

SD-OCT assessment and visual field changes 1 year or more after a single episode of unilateral acute primary angle closure

Avaliação do SD-OCT e mudanças do campo visual 1 ano ou mais após episódio único de fechamento angular primário agudo unilateral

Rafael Vidal Merola¹ , Sebastião Cronemberger¹ , Érica de Abreu Borges¹ , Jamilly Batista Prates¹ 

¹ Serviço de Glaucoma Professor Nassim Calixto, Hospital São Geraldo, Hospital das Clínicas, Universidade Federal de Minas Gerais, Belo Horizonte, MG, Brazil.

How to cite:

Merola RV, Cronemberger S, Borges EA, Prates JB. SD-OCT assessment and visual field changes 1 year or more after a single episode of unilateral acute primary angle closure. Rev Bras Oftalmol. 2022;81:e0069.

doi:

<https://doi.org/10.37039/1982.8551.20220069>

Keywords:

Tomography, optical coherence; Visual fields; Glaucoma, angle-closure; Optic disc; Macula lutea

Descritores:

Tomografia de coerência óptica; Campos visuais; Glaucoma de ângulo fechado; Disco óptico; Mácula lútea

Received on:
Aug 30, 2021

Accepted on:
Sept 19, 2022

Corresponding author:

Rafael Vidal Merola
Rua Santo Antônio, 416, apto. 604 – Centro
Zip code: 36015-000 – Juiz de Fora, MG,
Brazil
E-mail: rafaelmerola@hotmail.com

Institution:

Serviço de Glaucoma Professor Nassim Calixto, Hospital São Geraldo, Hospital das Clínicas, Universidade Federal de Minas Gerais, Belo Horizonte, MG, Brazil.

Conflict of interest:

the authors declare no conflict of interest.

Financial support:

the authors received no financial support for this work.



Copyright ©2022

ABSTRACT

Objective: To evaluate structural and visual field (VF) changes after ≥ 1 year of a single acute primary angle closure (APAC) attack using spectral-domain optical coherence tomography (SD-OCT) and standard automated perimetry (SAP). **Methods:** Patients with a single unilateral APAC crisis at least 1 year ago were included consecutively from 2013 to 2016. Contralateral eye was used as control. All patients underwent ophthalmic examination, RNFL imaging by SD-OCT, and SAP using Octopus 1-2-3. **Results:** 54 eyes (27 patients) were enrolled. Male-to-female ratio was 1:2. Mean time for the SD-OCT and SAP assessment after the crisis was 5.0 ± 5.1 (1.0–23.5) years, and IOP was 52.5 ± 9.8 mmHg. In APAC eyes, the thicknesses of all quadrants of peripapillary RNFL (36.3%; $P < 0.001$) and some macular sections (from 2.1% to 4.7%; $P < 0.01$) were reduced compared to contralateral eyes. Additionally, in APAC eyes, the mean defect on VF was negatively and statistically correlated with the reduction of all quadrants of peripapillary RNFL thickness. **Conclusion:** A single episode of APAC was associated with peripapillary RNFL and macular thickness and with VF defects after ≥ 1 year of the crisis in the affected eye. Statistically meaningful correlations were found between structural and functional damage.

RESUMO

Objetivo: Avaliar alterações estruturais e do campo visual 1 ano ou mais após uma crise única de fechamento angular primário agudo utilizando tomografia de coerência óptica de domínio espectral e perimetria automatizada padronizada. **Métodos:** Pacientes que apresentaram crise unilateral única de fechamento angular primário agudo há pelo menos 1 ano foram consecutivamente incluídos entre 2013 e 2016. Os olhos contralaterais foram utilizados como controles. Todos os pacientes foram submetidos a exame oftalmológico, avaliação das camadas de fibras nervosas da retina utilizando tomografia de coerência óptica de domínio espectral e perimetria automatizada padronizada com o Octopus 1-2-3. **Resultados:** Foram incluídos 54 olhos (27 pacientes) com razão homem:mulher de 1:2. O tempo médio após a crise foi de $5,0 \pm 5,1$ anos (1,0 a 23,5) e a pressão intraocular na crise foi $52,5 \pm 9,8$ mmHg. Nos olhos com fechamento angular primário agudo, todas as espessuras das camadas de fibras nervosas da retina peripapilares (36,3%; $p < 0,001$) e de algumas seções maculares (de 2,1 a 4,7%; $p < 0,01$) estavam reduzidas em comparação aos olhos contralaterais. Além do mais, nos olhos submetidos a fechamento angular primário agudo, o *mean defect* do campo visual foi estatisticamente e negativamente correlacionado com a redução da espessura de todos os quadrantes peripapilares da camada de fibras nervosas da retina. **Conclusão:** Um único episódio de fechamento angular primário agudo foi associado com redução na espessura da camada de fibras nervosas da retina peripapilar e da espessura macular e com defeitos de campo visual 1 ano ou mais após a crise no olho afetado. Correlações estatisticamente significativas foram identificadas entre danos estruturais e funcionais.

INTRODUCTION

Acute primary angle closure (APAC) is an eye emergency and possibly a blinding event. Optic nerve damage can occur after an abrupt increase in intraocular pressure (IOP) related to an APAC crisis. The optic disc appears edematous throughout this attack, and paleness with or without cupping may appear after remission. Several researchers have described an adverse long-term visual outcome after an APAC episode, with elevated proportions of serious glaucomatous optic neuropathy.^(1,2) Retinal nerve fiber layer (RNFL) reduction,⁽³⁻¹⁰⁾ optic nerve head damage,⁽¹¹⁻¹³⁾ visual field (VF) defects,^(14,15) prelaminar tissue thickness, and anterior lamina cribrosa surface depth reduction⁽¹⁶⁾ have been demonstrated after APAC. However, there are few studies regarding long-term changes in peripapillary RNFL thickness or, more rarely, macular thickness and their correlations with VF defects in APAC after ≥ 1 year of the crisis, and none of the studies have targeted Brazilians.⁽¹⁷⁾ Furthermore, limited data are available regarding the factors that could influence the severity of functional and structural damage after years of an acute attack. Therefore, this study aimed to assess the long-term outcomes, such as changes in peripapillary RNFL thickness, macular thickness, and VF, after a unique unilateral APAC crisis and the correlations between structure and function in a real-world setting.

METHODS

In this study, patients who had a unique APAC crisis of ≥ 1 year were eligible. They were identified and assessed through ophthalmic consultations at the Glaucoma Service of Hospital São Geraldo, Hospital das Clínicas - UFMG from January 2013 to July 2016. Written Informed Consent was obtained from all patients, and the study adhered to the tenets of the Declaration of Helsinki. The Ethics Committee of the Universidade Federal de Minas Gerais approved the study protocol.

The records of the patients were assessed. Acute primary angle closure cases were determined as follows: occurrence of a minimum of two of the following symptoms: eye pain; queasiness, vomiting, or both and clouded view with haloes; an IOP ≥ 21 mmHg on Goldmann applanation tonometry; occurrence of a minimum of three of the following: conjunctival hyperemia, corneal epithelial edema, unreactive mid-dilated pupil, and narrow anterior chamber; and closed anterior chamber angles in four quadrants at gonioscopy. The inclusion criteria were as follows: APAC as defined above; the contralateral eye did not suffer any APAC episode but had occludable angles at the examination; IOP < 21 mmHg after management using clinical therapy, laser

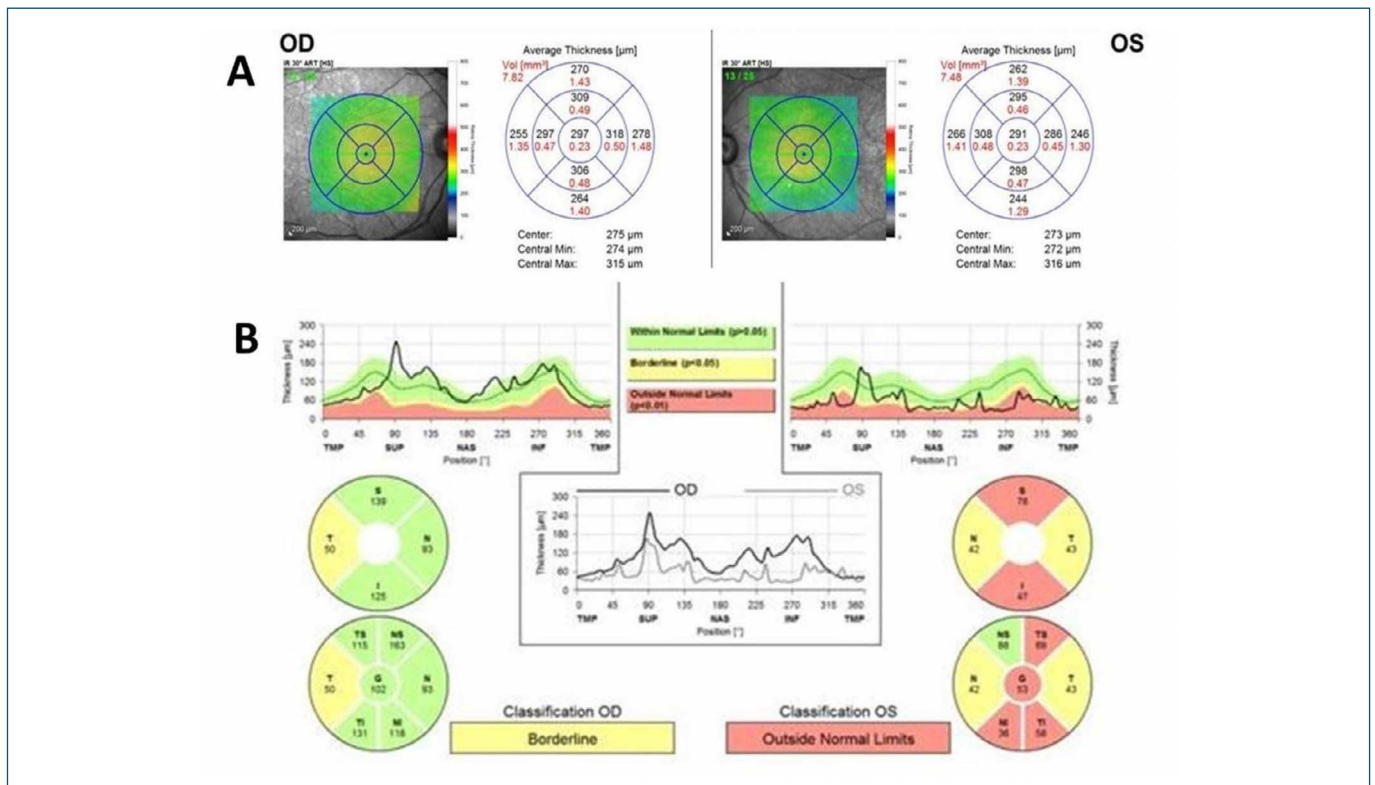
iridotomy, or glaucoma surgery; and no retinal damage that could interfere with the RNFL imaging examination, such as diabetic retinopathy, macular degeneration, retinal thrombosis, or macular edema. Patients with secondary angle closure, such as lens intumescence or subluxation, uveitis, and iris neovascularization, were excluded. We also excluded subjects who had indications of primary angle closure glaucoma (PACG) in the affected or contralateral eye upon examination. Primary angle closure glaucoma was diagnosed when the patient presented with one or both of the following findings: occurrence of glaucomatous optic neuropathy, with damage of neuroretinal rim tissue and a vertical cup-to-disc ratio (VCDR) of > 0.7 and/or significant VF defects on standard automated perimetry (SAP). It is important to mention that, although five eyes within the fellow eyes were receiving anti-glaucomatous drops and one eye had undergone trabeculectomy, these contralateral eyes did not meet the PACG criteria. Laser peripheral iridotomy was done in all affected and fellow eyes at the time of the crisis. And, at the time of the study, all patients had their IOP controlled. We documented demographic characteristics, previous medical history, number of ocular hypotensive medications, and eye records connected to the APAC attack (IOP, affected eye, the interval between the onset of symptoms, and IOP normalization), as well as additional eye diseases, and any eye operations.

All subjects underwent an ophthalmic examination, SAP using Interzeag Octopus 1-2-3 (Haag-Streit AG, Koeniz, Switzerland), RNFL assessment using spectral domain optical coherence tomography (SD-OCT), and ultrasound biometric assessment performed on the same day. Acute primary angle closure-affected eyes were compared with contralateral eyes (control eyes).

Both eyes were examined by a single ophthalmologist, a glaucoma specialist (one of the authors), including best-corrected visual acuity (BCVA) measurement in decimal notation, slit-lamp examination, Goldmann applanation tonometry, gonioscopy, and dilated fundus examination. Vertical cup-to-disc ratio assessment was performed by the same glaucoma specialist using a 78 Volk diopter lens. A factor of correction ($\times 1.1$) was applied to define the exact measurement.

Retinal nerve fiber layer peripapillary images of both eyes were captured using SD-OCT (Spectralis® HRA+OCT; Heidelberg Engineering Inc., Heidelberg, Germany) by an experienced operator who was blinded to the patients' ophthalmic data.

The operator utilized the integrated scan acquisition function named "circular" to obtain peripapillary



OD: right eye; OS: left eye.

Figure 1. Spectral-domain optical coherence tomography of a patient 23.5 years after an acute primary angle closure attack in the left eye. (A) Macular segmentation Spectralis® printout. (B) Peripapillary retinal nerve fiber layer segmentation Spectralis® printout.

B-scans (high-speed – HS – mode with automatic real-time – ART – set at 16 frames to improve quality images and optimize these images by noise reduction, covering 30°) in a rounded shape (approximately 3.4mm in diameter) centralized at the optic disc. Scans with a signal power quality ≤ 16 or poor centralization were excluded. The integrated assessment software plots the RNFL thickness (mean values) in a pie diagram demonstrating six regions of the optic disc (temporal superior – TS –, temporal – T –, temporal inferior – TI –, nasal superior – NS –, nasal – N –, and nasal inferior – NI), composed of a mean general RNFL thickness (global – G).

To evaluate the macular region, patients underwent four successive scans in a unique period via the “fast macular volume” comprising a 25-line horizontal scan covering 20°×20°, centralized on the fovea. Scans were achieved in the HS mode with ART assisted and set to 25 frames. The integrated assessment software plots the macular thickness (mean values) in a pie chart diagram demonstrating nine segmentations of the macula (fovea, inner superior – IS –, inner nasal – IN –, inner inferior – IF –, inner temporal – IT –, outer superior – OS –, outer nasal – ON –, outer inferior – OI –, and outer temporal – OT –, and center point thickness).

The SD-OCT mean values were documented in micrometers (Figure 1).

The axial length (AL) was measured using A-mode contact ultrasonography (DGH 5100e; DGH Technologies, Exton, USA) with a pachymeter to measure the corneal central thickness (CCT). Three consecutive CCT measurements were obtained with a standard deviation of ≤ 0.05 mm, and the lowest value was used, presuming that it was the most perpendicular measurement without exaggerated strength. Keratometric (K) values from vertical and horizontal measurements were obtained using a Bausch & Lomb keratometer (Lombart Keratometer; Lombart Instruments Inc., Norfolk, EUA).

In this examination, we used a reliability factor of $< 15\%$, with a false-positive and false-negative rate of $> 15\%$. Patients with unreliable VF underwent repeat examinations for a maximum of three times, after which they were excluded from the study. Furthermore, corrected loss variance (CLV) and mean defect (MD) of the VF were documented.

STATISTICAL ANALYSIS

The Statistical Package for Social Sciences (SPSS) version 16.0 for Windows (SPSS Inc., Chicago, IL) was used. The

affected eye of each patient with APAC was analyzed, and the fellow eye was examined and used as a control. The MD, CLV, peripapillary RNFL thickness, macular thickness, BCVA, IOP, VCDR, K, CCT, and AL values of the affected and fellow eyes were compared using a two-tailed Student's *t*-test. The level of significance was set at $p < 0.05$.

The relationship between MD, CLV, BCVA, and peripapillary RNFL thickness was evaluated using the Pearson correlation coefficient.

Univariate and multivariate regression analyses were used to correlate the percentage of peripapillary G RNFL and macular section (IS, II, IN, ON, and IT) thinning and MD alteration with clinical parameters (age at presentation, IOP at presentation, the interval between APAC crisis and IOP control, and the interval between the date of an APAC episode and the date of evaluation) to investigate whether these parameters could predict the SD-OCT and VF differences between the affected and contralateral eyes.

RESULTS

A total of 31 patients with APAC completed the study. Three (16.7%) subjects with bilateral crisis and one subject with exudative macular degeneration in the fellow eye were excluded; hence, 27 subjects were included in the final assessment. Table 1 summarizes the clinical, demographic, and biometric features of the subjects.

Table 1. Clinical, demographic, and biometric characteristics of patients with acute primary angle closure

	APAC affected eyes (n=27)	Fellow eyes (n=27)	p-value
Age (years) at presentation	60.5±9.7 (43-79)		
Males/females, n(%)	9 (33.3)/18 (66.7)		
Leukodermic/pheodermic/melanodermic, n(%)	13 (48.1)/13 (48.1)/1 (3.8)		
APAC affected eye, n(%)	8 (29.6) right/ 19 left (70.4)		
Family history of glaucoma, n(%)	16 (59.3) positive/ 11 (40.7) negative		
Interval between APAC crisis and IOP control (hours), mean±SD	68.9±82.8 (10-360)		
Interval between APAC crisis and examination (years), mean±SD	5.0±5.1 (1.0-23.5)		
BCVA, mean±SD	0.64±0.29	0.83±0.22	0.003
Baseline IOP (mmHg), mean±SD	52.5±9.8	15.5±4.0	<0.001
Vertical CDR, mean±SD	0.56±0.28	0.30±0.13	<0.001
Keratometry (diopters), mean±SD	44.70±1.68	44.74±1.85	0.822
CCT (µm), mean±SD	537±30.2	540±26.5	0.385
AL (mm), mean±SD	21.81±0.63	21.69±0.71	0.074
Ocular hypotensive medication (number of eyes) n(%)	8 (29.6)	5 (18.5)	
Cataract surgery (number of eyes) n(%)	7 (25.9)	7 (25.9)	
Trabeculectomy (number of eyes) n(%)	3 (11.1)	1 (3.7)	
Combined cataract and glaucoma surgery (number of eyes) n(%)	4 (14.8)	0 (0)	
Combined cataract and goniosynechiolysis surgery (number of eyes) n(%)	1 (3.7)	0 (0)	

APAC: acute primary angle closure; IOP: intraocular pressure; SD: standard deviation; BCVA: best-corrected visual acuity; CDR: cup-to-disc ratio; CCT: central corneal thickness; AL: axial length.

In APAC eyes, all quadrants of peripapillary RNFL ($p < 0.001$) and some macular sections (except for the center point, fovea, and outer superior) ($p < 0.01$) presented reduced thicknesses compared to contralateral eyes (Table 2).

Table 2. Visual field parameters mean defect and corrected low variance, peripapillary retinal nerve fiber layer and macular thickness (µm) measurements of patients with acute primary angle closure

	APAC Affected eyes (n=27)	Fellow eyes (n=27)	% reduction affected-fellow eyes	p-value
MD	11.0±9.3	2.9±3.0		<0.001
CLV	20.7±20.0	12.9±15.4		0.052
Peripapillary RNFL thickness				
Global	64.5±20.4	101.2±10.9	36.3	<0.001
Temporal superior	82.5±30.1	140.1±25.4	41.1	<0.001
Temporal	56.3±12.5	72.3±12.6	22.1	<0.001
Temporal inferior	80.9±29.5	147.4±24.3	45.1	<0.001
Nasal superior	71.5±30.5	110.3±24.9	35.2	<0.001
Nasal	47.1±17.3	70.0±20.7	32.7	<0.001
Nasal Inferior	75.3±36.0	116.2±38.6	35.2	<0.001
Macular thickness				
Center point	235.1±26.4	231.5±22.5		0.176
Fovea	269.9±23.6	263.8±21.3		0.092
Inner superior	322.0±23.4	333.8±17.0	3.5	0.001
Outer superior	285.6±26.9	293.5±15.8		0.147
Inner inferior	315.6±25.7	328.4±16.0	3.9	0.003
Outer inferior	267.5±21.3	273.2±23.8	2.1	0.015
Inner nasal	325.0±20.3	333.6±16.6	2.6	0.011
Outer nasal	295.3±20.9	310.0±17.3	4.4	<0.001
Inner temporal	307.9±22.6	320.4±17.6	3.9	0.002
Outer temporal	270.9±21.3	280.8±15.6	3.5	<0.001

APAC: acute primary angle closure; MD: mean defect; CLV: corrected low variance; RNFL: retinal nerve fiber layer.

The statistically significant correlations in affected APAC eyes between VF features and SD-OCT parameters and between BCVA and SD-OCT parameters in APAC eyes are summarized in Table 3. However, some CLV correlations were not statistically significant. No significant correlation was observed in fellow eyes between VF features and SD-OCT parameters or between BCVA and SD-OCT parameters.

No statistically significant correlation was found between age at presentation, family history of glaucoma, K, CCT, AL, VF, or SD-OCT parameters in APAC or fellow eyes.

Univariate and multivariate regression analyses verified that age, sex, race, IOP, AL, the interval between APAC crisis and IOP control, and the interval between the date of APAC crisis and the date of examination did not predict the SD-OCT and VF differences between affected and fellow eyes ($p > 0.05$).

DISCUSSION

To the best of our knowledge, this study is the first to assess changes in functional and structural parameters, particularly macular thickness, and their correlations after

Table 3. Pearson correlation coefficient between mean defect, corrected low variance, best-corrected visual acuity, and peripapillary retinal nerve fiber layer/macular thickness (μm) for acute primary angle closure-affected eyes ($n=27$)

	Peripapillary RNFL thickness						
	Global	Nasal superior	Nasal	Nasal inferior	Temporal superior	Temporal	Temporal inferior
MD	$r=-0.832$ ($p<0.001$)	$r=-0.792$ ($p<0.001$)	$r=-0.735$ ($p<0.001$)	$r=-0.565$ ($p=0.002$)	$r=-0.847$ ($p<0.001$)	$r=-0.654$ ($p<0.001$)	$r=-0.825$ ($p<0.001$)
CLV	$r=-0.105$ ($p=0.720$)	$r=-0.832$ ($p<0.001$)	$r=-0.832$ ($p<0.001$)	$r=-0.119$ ($p=0.686$)	$r=-0.314$ ($p=0.275$)	$r=-0.290$ ($p=0.315$)	$r=-0.280$ ($p=0.332$)
BCVA	$r=0.568$ ($p=0.002$)	$r=0.429$ ($p=0.025$)	$r=0.465$ ($p=0.015$)	$r=0.577$ ($p=0.002$)	$r=0.444$ ($p=0.020$)	$r=0.478$ ($p=0.012$)	$r=0.506$ ($p=0.007$)
	Macular thickness						
	Inner superior	Inner inferior	Inner nasal	Outer nasal	Inner temporal		
MD	$r=-0.514$ ($p=0.006$)	$r=-0.507$ ($p=0.007$)	$r=-0.435$ ($p=0.023$)	$r=-0.419$ ($p=0.029$)	$r=-0.452$ ($p=0.018$)		
CLV	$r=-0.043$ ($p=0.831$)	$r=-0.285$ ($p=0.150$)	$r=-0.112$ ($p=0.577$)	$r=-0.139$ ($p=0.490$)	$r=-0.229$ ($p=0.251$)		
BCVA	$r=0.686$ ($p<0.001$)	$r=0.587$ ($p=0.001$)	$r=0.593$ ($p=0.001$)	$r=0.593$ ($p=0.001$)	$r=0.554$ ($p=0.003$)		

$r>0.500$ is a high positive correlation; $r<-0.500$ is a high negative correlation. No statistical significance was found among the correlations above in the fellow eyes.
RNFL: the retinal nerve fiber layer; MD: mean defect; CLV: corrected low variance; BCVA: best-corrected visual acuity.

≥ 1 year of a single event of APAC using SD-OCT, mainly in Brazilians, in a real-world setting. Sng et al., using Stratus OCT and Heidelberg retina tomography, assessed 25 patients after a median of 33 months (range, 11 to 85 months) of an APAC episode. They observed peripapillary and outer macular RNFL reduction, VF defects, and optic disc pallor in situations in which the optic nerve head remained unchanged.⁽¹⁷⁾ In this study, we examined 27 patients after a median of 5.0 ± 5.5 years (range, 1.0 to 23.5) of an APAC episode and obtained similar results regarding the peripapillary and outer RNFL macula. However, we found an inner macular thickness reduction in APAC eyes. Chew et al. did not observe changes in macular thickness after 6 to 12 months of APAC episodes.⁽¹³⁾ One strength of this study is that we investigated macular thickness in patients with APAC for ≥ 1 year, and a reduction in thickness was found in the affected eyes.

In this study, MD was correlated with thickness reduction in all quadrants of peripapillary RNFL (G, NS, N, NI, TS, T, and TI) and some macular sections (IS, IF, IN, ON, and IT), and CLV to NS and N. Best-corrected visual acuity was correlated with thickness reduction in all quadrants of all peripapillary RNFL and some macular sections (IS, IF, IN, ON, and IT). Previous studies have demonstrated that an event of APAC is related to RNFL loss, which is noticeable on OCT and scanning laser polarimetry (SLP).⁽³⁻⁵⁾ Chew et al. found a decrease in RNFL over 6 to 12 months of follow-up and concluded that an increase in VCDR does not occur after immediate treatment of APAC, although RNFL reduction occurs.⁽¹³⁾ Mansoori et al., using spectral optical coherence tomography/scanning laser ophthalmoscopy, verified that RNFL was meaningfully thinner in APAC and normal fellow eyes than in normal control eyes 6 weeks after APAC completion.⁽⁶⁾ These studies did not clarify the functional damage or structural and functional correlations as we did in the present study. Using Stratus OCT, Sng et al. observed that peripapillary RNFL loss following APAC was associated with pale discs and

VF loss.⁽¹⁷⁾ Tsai et al. showed a significant correlation between average RNFL thickness in APAC eyes and VF index at 12 weeks.⁽⁹⁾ Subjects with more deep VF defects had greater relative RNFL thinning in a previous study.⁽⁹⁾ Our results were similar; however, we did not study patients with an APAC crisis during the first year after the episode but we assessed them ≥ 1 years after the attack. Lee et al., using SD-OCT, described a 25% reduction in peripapillary RNFL thickness in affected APAC eyes compared to that in unaffected eyes at 7.5 years after the crisis; however, they did not study macular thickness.⁽¹⁸⁾ In our study, we noticed a reduction of 36.3% of peripapillary G RNFL at 5.0 ± 5.1 years (1.0 to 23.5) after the attack. When we assessed macular sections, we verified a reduction of 3.5% (IS), 3.9% (II), 2.1% (OI), 2.6% (IN), 4.4% (ON), 3.9% (IT), and 3.5% (OT). At this point, it is important to discuss the main clinical implications of our findings. According to our results, not only peripapillary RNFL is reduced one year after a single APAC crisis but also some macular sections. In consequence, it is mandatory to investigate macular thickness using OCT in patients after 1 year of an angle closure attack.

Factors that could be correlated with RNFL thinning after APAC were investigated. Tsai et al. found a correlation between average RNFL thickness and the follow-up interval (1, 4, and 12 weeks after remission) in APAC eyes.⁽⁹⁾ This correlation was not observed in our long-term study. In an experimental primate glaucoma model, Quigley and Addicks demonstrated that a fast acute IOP elevation was followed by optic disc paleness; however, VCDR was not amplified.⁽¹⁹⁾ An increased VCDR occurred only when the acute IOP increase persisted for >1 week and was histologically connected to damage of anterior optic nerve head axonal fibers along with lateral and posterior displacement of the lamina cribrosa.⁽¹⁹⁾ Lai et al. used SLP to assess affected and fellow eyes at 6 months after a unique APAC attack, but did not observe significant alterations in any RNFL parameters in eyes whose APAC

episode was <48 hour.⁽²⁰⁾ Zhu et al. verified that patients with an APAC duration of <1 day had less retinal thickness damage and peripapillary blood flow density, suggesting that immediate control of the acute attack could prevent serious retinal damage.⁽²¹⁾ The relationship between follow-up intervals, duration of the IOP elevation, VCDR, VF, and SD-OCT parameters is likely to be complex and multifactorial. In our study, we did not observe any statistically significant correlation between age at presentation, IOP at presentation, the interval between APAC crisis and IOP control, the interval between the date of APAC attack and the date of assessment, and the interval between VF or SD-OCT parameters in APAC or fellow eyes.

Additionally, after univariate and multivariate regression analysis, we observed that age at presentation, IOP at presentation, the interval between APAC crisis and IOP control, and the interval between the date of APAC attack and the date of assessment did not predict the SD-OCT thickness reduction and VF differences between APAC-affected and contralateral eyes ($p>0.05$). Aung et al., in a comparable investigation, did not find any risk factors predictive of RNFL reduction.⁽⁵⁾ Using Cirrus HD-OCT, Knight et al. found that global and regional RNFL measurements were influenced by race, age, and AL in normal subjects.⁽²²⁾ Using SD-OCT, Ooto et al. verified that the effects of gender and age on macular dimensions vary according to the retinal layer in the normal population; these elements must be considered while analyzing macular layer data.⁽²³⁾ Lee et al. verified that using univariate analysis, an enlarged VCDR and poor visual acuity were the only relevant predictors of peripapillary RNFL thinning.⁽¹⁸⁾ Recent studies have identified that APAC eyes show a lower peripapillary retinal vessel density, which is correlated with VF changes,⁽²⁴⁻²⁶⁾ and that SD-OCT plays an important role in detecting PACG progression.⁽²⁷⁾

The results of our study should be cautiously analyzed, considering the intrinsic real-world limitations of the assessment, such as previous cataract surgery or trabeculectomy, and the relatively small sample size. An additional limitation of study is the circumstance that we evaluated VF defects and RNFL thickness (≥ 1 year after the crisis); therefore, we were unable to determine when the VF parameters or RNFL changes started and the velocity of their progression after APAC crisis. Some patients may have experienced increased IOP with RNFL loss before the acute crisis. As the data on the duration of critical symptoms may not be trustworthy, we also cannot be certain when the APAC attack started. Further, the time between the crisis and the examination varied significantly.

However, all patients had only one APAC crisis ≥ 1 year ago. A prior study has suggested that most patients develop PACG within 6 months of APAC, and another study has demonstrated that the following factors were related to a higher risk of glaucoma appearance: the interval of symptoms before presentation and the time required to solve the crisis.^(1,28) Using fellow eyes as controls was a good strategy, as a previous study has demonstrated that only 6.5% of contralateral eyes developed glaucoma with a mean follow-up of 6 years after an acute attack.⁽²⁾ One specific limitation and characteristic of the present study is that we did not assess the patients at different points over time. However, our group is conducting follow-up research to complement the knowledge of the present study and clarify some questions revealed in this study.

CONCLUSION

In conclusion, we verified, with statistical significance, that eyes affected with a unique unilateral attack of APAC for ≥ 1 year presented peripapillary RNFL (36.3%) and macular thickness (from 2.1% to 4.4%) reduction and VF defects compared unaffected eyes in a real-world setting. MD was negatively and statistically correlated and BCVA was positively and statistically correlated with the thickness of all quadrants of peripapillary RNFL and some macular sections (IS, II, IN, ON, and IT). No predictors of functional and structural differences between APAC and contralateral eyes were found among the clinical variables assessed.

REFERENCES

1. Aung T, Friedman D, Chew P, Ang LP, Gazzard G, Lai YF, et al. Long-term outcomes in Asians after acute primary angle closure. *Ophthalmology*. 2004;111(8):1464-69.
2. Friedman DS, Chew PT, Gazzard G, Ang LP, Lai YF, Quigley HA, et al. Long-term outcomes in fellow eyes after acute primary angle closure in the contralateral eye. *Ophthalmology*. 2006;113(7):1087-91.
3. Tsai J, Chang H. Scanning laser polarimetry in patients with acute angle-closure glaucoma. *Eye*. 2004; 18:9-14.
4. Fang A, Qu J, Li L, Ji BL. Measurement of retinal nerve fiber layer in primary acute angle closure glaucoma by optical coherence tomography. *J Glaucoma*. 2007;16(2):178-4.
5. Aung T, Husain R, Gazzard G, Chan YH, Devereux JG, Hoh ST, et al. Changes in retinal nerve fiber layer thickness after acute primary angle closure. *Ophthalmology*. 2004;111(8):1475-79.
6. Mansoori T, Viswanath K, Balakrishna N. Quantification of retinal nerve fiber layer thickness after unilateral acute primary angle closure in Asian Indian eyes. *J Glaucoma*. 2013;22(1):26-30.
7. Wong IY, Yuen NS, Chan CW. Retinal nerve fiber layer thickness after a single attack of primary acute angle-closure glaucoma measured with optical coherence tomography. *Ophthalmic Surg Lasers Imaging*. 2010;41(1):96-9.
8. Liu X, Li M, Zhong YM, Xiao H, Huang JJ, Kong XY. Damage patterns of retinal nerve fiber layer in acute and chronic intraocular pressure elevation in primary angle closure glaucoma. *Int J Ophthalmol*. 2010;3(2):152-7.

9. Tsai JC, Lin PW, Teng MC, Lai IC. Longitudinal changes in retinal nerve fiber layer thickness after acute primary angle closure measured with optical coherence tomography. *Invest Ophthalmol Vis Sci.* 2007;48(4):1659-64.
10. Tsai JC. Optical coherence tomography measurement of retinal nerve fiber layer after acute primary angle closure with normal visual field. *Am J Ophthalmol.* 2006;141(5):970-2.
11. Uhm K, Lee J, Sung H. Comparison of glaucomatous optic nerve damage in primary angle-closure glaucoma with and without acute attack. *Korean J Ophthalmol.* 2005; 19:201-7.
12. Shen S, Baskaran M, Fong A, Chan YH, Lim LS, Husain R, et al. Changes in the optic disc after acute primary angle closure. *Ophthalmology.* 2006;113(6):924-9.
13. Chew SS, Vasudevan S, Patel HY, Gurria LU, Kerr NM, Gamble G, et al. Acute primary angle closure attack does not cause an increased cup-to-disc ratio. *Ophthalmology.* 2011;118(2):254-9.
14. Ang L, Aung T, Chua W, Yip LW, Chew PT. Visual field loss from primary angle-closure glaucoma: a comparative study of symptomatic and asymptomatic disease. *Ophthalmology.* 2004;111(9):1636-40.
15. Bonomi L, Marraffa M, Marchini G, Canali N. Perimetric defects after a single acute angle-closure glaucoma attack. *Graefes Arch Clin Exp Ophthalmol.* 1999;237(11):908-4.
16. Lee EJ, Kim TW, Lee KM, Lee SH, Kim H. Factors Associated with the Retinal Nerve Fiber Layer Loss after Acute Primary Angle Closure: A Prospective EDI-OCT Study. *PLoS One.* 2017;31;12(1):e0168678.
17. Sng CC, See JS, Ngo CS, Singh M, Chan YH, Aquino MC, et al. Changes in retinal nerve fibre layer, optic nerve head morphology, and visual field after acute primary angle closure. *Eye (Lond)* 2011;25(5):619-5.
18. Lee JW, Woo TT, Yau GS, Yip S, Yick DW, Wong J, et al. Cross-sectional study of the retinal nerve fiber layer thickness at 7 years after an acute episode of unilateral primary acute angle closure. *Medicine (Baltimore).* 2015;94(2):e391.
19. Quigley HA, Addicks EM. Chronic experimental glaucoma in primates. II. Effect of extended intraocular pressure elevation on optic nerve head and axonal transport. *Invest Ophthalmol Vis Sci.* 1980;19(2):137-2.
20. Lai JS, Tham CC, Chan JC, Yip NK, Tang WW, Li PS, et al. Scanning laser polarimetry in patients with acute attack of primary angle closure. *Jpn J Ophthalmol.* 2003;47:543-7.
21. Zhu X, Zeng W, Wu S, Chen X, Zheng T, Ke M. Measurement of retinal changes in primary acute angle closure glaucoma under different durations of symptoms. *J Ophthalmol* 2019;2019(4):5409837.
22. Knight OJ, Girkin CA, Budenz DL, Durbin MK, Feuer WJ; Cirrus OCT Normative Database Study Group. Effect of race, age, and axial length on optic nerve head parameters and retinal nerve fiber layer thickness measured by Cirrus HD-OCT. *Arch Ophthalmol.* 2012;130(3):312-8.
23. Ooto S, Hangai M, Tomidokoro A, Saito H, Araie M, Otani T, et al. Effects of Age, Sex, and Axial Length on the Three-Dimensional Profile of normal macular layer structures. *Invest Ophthalmol Vis Sci* 2011;52(12):8769-79.
24. Rao HL, Kadambi SV, Weinreb RN, Puttaiah NK, Pradhan ZS, Rao DA, et al. Diagnostic ability of peripapillary vessel density measurements of optical coherence tomography angiography in primary open-angle and angle-closure glaucoma. *Br J Ophthalmol.* 2017;101(8):1066-70.
25. Wang X, Jiang C, Kong X, Yu X, Sun X. Peripapillary retinal vessel density in eyes with acute primary angle closure: an optical coherence tomography angiography study. *Graefes Arch Clin Exp Ophthalmol.* 2017;255(5):1013-8.
26. Zhang S, Wu C, Liu L, Jia Y, Zhang Y, Zhang Y, et al. Optical coherence tomography angiography of the peripapillary retina in primary angle-closure glaucoma. *Am J Ophthalmol.* 2017;182:194-200.
27. Kuryshva NI, Lepeshkina LV. Detection of primary angle closure glaucoma progression by optical coherence tomography. *J Glaucoma.* 2021;30(5):410-420
28. Andreatta W, Elaroud I, Nightingale P, Nessim M. Long-term outcomes after acute primary angle closure in a White Caucasian population. *BMC Ophthalmol.* 2015;15(19):108.