












Evaluation of mesenchymal cells and dapsona for the treatment of dermonecrotic wounds caused by *Loxosceles laeta* venom in rabbits

Avaliação de células mesenquimais e dapsona para o tratamento de feridas dermonecroticas causadas pelo veneno de Loxosceles laeta em coelhos

Guilherme de Caro Martins¹ , Maira Souza Oliveira Barreto² , Ana Flávia Machado Botelho^{3*} , Conrado Gamba¹ , Clara Guerra Duarte¹ , Benito Soto-Blanco¹ , Adriane Pimenta Costa-Val Bicalho¹ , Geovanni Dantas Cassali¹ , Alfredo Miranda de Goes¹ , Carlos Delfin Chávez Olórtégui¹ , Marília Martins Melo¹ 

¹Universidade Federal de Minas Gerais (UFMG), Belo Horizonte, Minas Gerais, Brazil

²Universidade Federal de Lavras (UFLA), Lavras, Minas Gerais, Brazil

³Universidade Federal de Goiás (UFG), Goiânia, Goiás, Brazil

*Correspondent: anafflaviamabo@gmail.com

Abstract

This study aimed to evaluate the efficacy of mesenchymal stem cells (MSC), alone or associated with dapsona (DAP), in treating dermonecrotic wounds caused by *Loxosceles laeta* venom. Twenty-five male rabbits were distributed into five groups. Negative control received ultrapure water (C-), whilst all other groups were injected with 20 µg of *L. laeta* venom. After 4 hours, each group received one of the following treatments: PBS (C+), DAP, MSC, and DAP+MSC. Animals were evaluated daily and photographic records made for analysis of wound area. Twelve days after, animals were euthanized and skin samples removed for histological analysis. We observed that DAP showed the best percentage of wound contraction at day 3. In the treatments using MSCs, a negative value of wound contraction was observed for the isolated MSCs, as well as a lower contraction value for the association of the MSC + DAP when compared to PBS, probably, by the increase in initial inflammation after the application of stem cells, due to the fact that MSCs secrete a broad spectrum of bioactive molecules such as cytokines and growth factors that favor regeneration. Histologically, it was observed that animals of C+ showed extensive areas of necrosis, ulcers, neutrophilic infiltrate, and mineralization. Collagen deposition showed increase in MSC+DAP treatment, however vascularization remained unchanged. This is the first report using MSC and MSC+DAP as a treatment for cutaneous loxoscelism and more studies are needed to determine its use as an alternative therapy for dermonecrotic lesions caused by *Loxosceles* spider.

Key words: loxoscelism; MSC; stem cells; spider venom; wound repair.

Resumo

Este estudo teve como objetivo avaliar a eficácia das células-tronco mesenquimais (CTMs), isoladas ou associadas à dapsona (DAP), no tratamento de feridas dermonecroticas causadas pelo veneno de *Loxosceles laeta*. Vinte e cinco coelhos machos foram distribuídos em cinco grupos. O controle negativo recebeu água ultrapura (C-), enquanto todos os outros grupos foram injetados com 20 µg de veneno de *L. laeta*. Após 4 horas, cada grupo recebeu um dos seguintes tratamentos: PBS (C+), DAP, CTMs e DAP + CTMs. Os animais foram avaliados diariamente durante 12 dias, e feitos registros fotográficos para análise da ferida e no 12º dia, foram eutanasiados e, retiradas amostras de pele para análise histológica. Observou-se que a DAP apresentou o melhor percentual de contração da ferida no terceiro dia. Nos tratamentos com CTMs, observou-se uma contração negativa da ferida tanto para as CTMs isoladas, bem como a associação CTMs + DAP em relação ao PBS, possivelmente, pelo aumento da inflamação inicial após a aplicação de células-tronco. Isso é devido ao fato de que as CTMs secretam um amplo espectro de moléculas bioativas como citocinas e fatores de crescimento que favorecem a regeneração. Histologicamente, observou-se que os animais de C+ apresentaram extensas áreas de necrose, úlceras, infiltrado neutrofílico, além de mineralização. Houve aumento de deposição de colágeno no tratamento CTMs + DAP, no entanto, a vascularização permaneceu inalterada. Este é o primeiro relato usando CTMs e CTMs + DAP como tratamento para loxoscelismo cutâneo e mais estudos são necessários para determinar seu uso como terapia alternativa para lesões demonecroticas causadas pela aranha *Loxosceles*.

Palavras-chave: loxoscelismo; células-tronco; CTMs; veneno de aranha; reparo de feridas.

Recebido : 18 de abril de 2022. Aceito: 13 de julho de 2022. Publicado: 30 de agosto de 2022.



Introduction

Loxoscelism is described in all the continents and corresponds to the most severe form of araneism in Brazil^(1,2,3,4). The clinical syndrome can develop into two distinct forms: the cutaneous form, characterized by local alterations, with a dermonecrotic wound of difficult healing, and the visceral-cutaneous form, presenting important systemic alterations such as acute renal failure, clotting disturbances, and risk of death, in addition to the local lesion^(5,6,7).

The cutaneous and systemic changes observed in loxoscelic accidents are due to multiple factors, involving direct tissue damage caused by venom components, secondary vascular injury, and enzymatic release by polymorphonuclear cells⁽⁷⁾. In spite of being a complex mixture of components, it is known that venom phospholipases D are mainly responsible for dermonecrosis. These enzymes are capable of interacting with cell membranes, initiating reactions involving the complement system, platelets, and leucocytes^(5,8).

Loxoscelic envenoming treatment is based on observed clinical signs and includes the use of dapson, acetylsalicylic acid, broad spectrum antibiotics, corticosteroids, specific antivenom, composed of heterologous antibodies developed in horses and new antibody treatments^(5,9,10,11,12,13). Despite these treatment options, tissue recovery after extensive dermonecrotic damage is slow and scar formation is difficult.

One therapeutic possibility for tissue repair is the use of stem cells⁽¹⁴⁾. Stem cells can be of embryonic, fetal, or mature tissue origin. Mesenchymal stem cells (MSC), from tissues such as mature bone marrow or adipose tissue, are being largely used in experimental assays of tissue regeneration due to their potential to differentiate into diverse cell types and ease in isolation and proliferation⁽¹⁵⁾. They have the potential to differentiate in to cutaneous cells of the ectodermal, mesodermal and endodermal layers of the skin, with applications in regenerative medicine^(16,17).

Up until now, there have been no studies evaluating the use of stem cells in the treatment of dermonecrotic wounds caused by loxoscelism. Therefore, the main goal of this work is to assess the efficacy of mesenchymal stem-cells, alone or associated with dapson, for the treatment of dermonecrotic lesions caused by experimental inoculation of *Loxosceles laeta* venom in rabbits. The resulting wounds were monitored by the evaluation of tissue healing, tissue morphology by histological examination, collagen quantification, and immunohistochemistry.

Material and methods

Mesenchymal stem cells (MSC) isolation

MSCs were obtained from the adipose tissue extracted from interscapular region of two donor outbred New Zealand rabbits, under general anesthesia with propofol (6 mg/kg). The collected tissue was washed in PBS and underwent enzymatic digestion with type II collagenase for 1 hour. Afterwards, collagenase activity was inhibited by adding fresh Dulbecco's Modified Eagle Medium (DMEM) to the cells and centrifuging at 23°C, 1200 rpm for 10 minutes. The resulting pellet was suspended in DMEM supplemented with 10% fetal bovine serum (FBS) and plated in T75 sterile culture flasks. Cell cultures were maintained at humid atmosphere, at 37°C, 5% CO₂ until 90% confluence. Cells were then detached with 0.5 ml trypsin-EDTA 0.25%, diluted at 1:3 ratio, and transferred to another T75 flask. Isolation of MSCs was based on their ability to adhere to the flasks⁽¹⁸⁾.

MSC characterization

Between the 3rd and 5th passages, MSCs were phenotypically characterized by differentiation induction into adipogenic or osteogenic cells to confirm their pluripotency. For adipogenic differentiation, 5 x 10⁴ cells/well were plated in 6-well plates, with DMEM supplemented with 10% FBS, dexamethasone (0.5 µM), insulin (1 µM), indomethacin (60 µM), and isobutyl methylxanthine (0.5 µM)⁽¹⁵⁾. Culture media were replaced every three days and culture was maintained for 21 days. Afterwards, cells were stained with Oil Red to evince lipid droplets in the cytoplasm, thus confirming differentiation into adipocytes. For osteogenic differentiation, 5 x 10⁴ cells/well were plated in six-well plates and cultured for 21 days in DMEM supplemented with 10% FBS, ascorbic acid (50 µg/ml), β-glycerophosphate (10 mM), and dexamethasone (0,1 µM). Media were replaced every 3 days⁽¹⁵⁾.

To evaluate cell viability of MSCs, MTT (3-(4,5-dimethylthiazol-2-yl)-2,5-diphenyl tetrazolium bromide) metabolization assay was performed. Cells/m² (5 x 10⁴) were plated in 24-well plates and incubated with 170 µl of MTT (5mg/ml; Sigma-Aldrich, USA), at 5% CO₂, 37°C, for 2 hours. Formed formazan crystals were observed in inverted light microscope and then solubilized by adding dodecyl sodium sulfate (SDS) in 10% HCl. Optical density was quantified at 595 nm, in automated plate reader.

Alkaline phosphatase activity

Considering that differentiated osteoblasts are able to secrete alkaline phosphatase⁽¹⁹⁾, its activity was measured in plated cells to ensure differentiation, using similar parameters described in the section above.

BCIP-NBT solution was added to each well and incubated for 2 hours. Purple precipitates were solubilized with SDS 10% HCl and optical density was quantified at 595 nm, in automated plate reader.

Animals

Twenty-five male New Zealand one-year old rabbits, weighting 1.5 kg, were used throughout this study. They were placed in individual metal cages (75 cm x 30 cm), receiving water and food *ad libitum*. All procedures were conducted following ethical principles, respecting the animals' welfare and minimizing eventual discomfort. The experiment was approved by the Ethics Committee in Animal Use (CEUA) of Universidade Federal de Minas Gerais, Belo Horizonte, MG, Brazil (Protocol No.83/2013).

Experimental groups and treatments

After a five-day adaptation period, the animals were randomly distributed into five groups of five animals. Negative control group (C-) was inoculated only with ultrapure water. All the other four groups were intradermally inoculated with 20 µg of *L. laeta* venom diluted in 0.2 ml of phosphate buffered saline (PBS). All treatments began four hours after venom injection with the intention of simulating early identification of the lesion and maximizing the effect of the proposed therapies, according to Phillips et al. ⁽²⁰⁾. Positive control group (C+) was treated only with PBS (0.5 ml), injected intradermally in four points equidistant from the center of the pre-formed lesion. The dapsone group (DAP) received a dose of 2 mg/kg of dapsone diluted in ethanol and ultrapure water (4:6 ratio) by nasoesophageal catheter every 24 hours for four days. The mesenchymal stem cells group (MSC) was treated with 1.25 x 10⁶ cells suspended in 0.5 ml of PBS, injected intradermally in four points equidistant from the center of the pre-formed lesion, totaling 5 x 10⁶ cells injected per animal. The 5th group was treated with a mixture of dapsone and mesenchymal stem cells (DAP+MSC), according to the procedures described above for each treatment.

Wound area evaluation

Wounds were measured and recorded daily to verify their evolution according to treatment protocol. Photographic records were taken with digital camera (Canon Rebel XSI EOS zoom 24 mm), kept at a constant distance of 50 cm from the wound. The collected data were evaluated with IMAGE PRO software. For wound contraction analysis, measurements were taken 3, 6, 9, and 12 days after treatment. Wound contraction percentage was calculated using the mathematical model proposed by Oliveira et al. ⁽²¹⁾ and Wu et al ⁽²²⁾:

$$\left(\frac{\text{area at day 1} - \text{area at day X}}{\text{area at day 1}} \right) * 100$$

Histopathological evaluation

The animals were euthanized twelve days after treatment by propofol anesthesia with a dose greater than 10 mg/kg. Skin fragments (5 cm x 6 cm) were removed and fixed in paraformol for 48 hours. Fixed tissues were then processed, included in paraffin, and 4-µm thick histological slices were taken for further analysis. After hematoxylin-eosin staining (Merck®), fixed skin tissue images were obtained with an Accu Scope microscope, coupled with TCS pro 500 software. Each slide was blindly described by a pathologist. Changes in epidermis, dermis, and muscle morphological structure, as well as the intensity and composition of inflammatory infiltrate and other specific findings such as tissue mineralization, were described.

To confirm tissue calcification observed on slides, von Kossa staining (Merck®) was performed. Masson's trichrome staining (Merck®) was used to evaluate the total number of collagen fibers. Photographic registry (Accu Scope microscope) was used with TCS pro 500 software to capture images. Collagen fibers were quantified using software ImageJ software. Picro-sirus Red staining was performed to evaluate collagen fiber differentiation. In this method, type I collagen fibers are stained red and type III collagen fibers are greenish. Pictures were taken with Leica Core microscope coupled with Leica Application Suite Core software. Six pictures of random fields of the lesion area of each slide were taken, and stained fibers were quantified using ImageJ software. Final evaluation was made considering each group's mean and standard deviation.

Immunohistochemistry

Immunohistochemistry was used to evaluate angiogenesis and vascular damage of affected skin tissues. Monoclonal CD31 antibody (clone JC70A, Dako) was used at 1:20 dilution, with 16 hours of incubation, to mark endothelial cells. To quantify the area marked by the used antibody, ten random fields of the lesion from each animal were captured using the Accu Scope microscope (400x) and the image capture software TCS pro 500. Images were analyzed by ImageJ software. The mean for each group was calculated for statistical evaluation.

Statistical analysis

Data was statistically analyzed using the software SAS v.9.0. The normality of the data was evaluated using a Shapiro-Wilk and Kolmogorov-Smirnov tests. Tukey's test was employed for the comparison of total collagen

fibers, type III collagen, and angiogenesis area. Logarithmic transformation of type I collagen values was performed prior to Tukey's test. Statistical analysis of wound contraction percentage was carried out using a mixed linear model approach of SAS, using first-order autocorrelation covariate structure. Animals were considered as a random factor, with each animal nested within treatments, with repeated measurements over time. Significant day versus treatment interactions were examined using the PDIFF procedure with preplanned comparisons. The significance level was set as $p < 0.05$.

Results and discussion

Isolation and characterization of mesenchymal stem cells from adipose tissues

The MSCs used throughout this work were obtained from interscapular adipose tissue from donor rabbits to avoid stressful handling of the animals posteriorly envenomed and treated, which could affect wound healing and the correct evaluation of employed treatments. Allogeneic MSCs are a promising option because of their low immunogenicity and immunosuppressive and tissue repair capabilities⁽²³⁾. Furthermore, auto-MSC extraction is time-consuming, making it difficult to use them promptly to treat acute diseases such as spider envenomation. MSCs derived from adipose tissue are gaining importance and being more frequently used in experiments, due to their easy isolation, good proliferative capacity, and the possibility of obtaining excellent cell quantity in a single procedure. This enables the use of fewer donor animals, when compared to the isolation of MSCs from bone marrow⁽¹⁸⁾.

Characterization of stem cells derived from adipose tissue confirmed their identity as mesenchymal stem cells (MSC) as they attached to culture flasks, presented in fibroblastoid form, and were able to differentiate into bone and adipogenic tissues (Fig.1). Cell viability was further confirmed by MTT and alkaline phosphatase tests (data not shown). The cells were then used to treat dermonecrotic wounds induced by intradermal *L. laeta* venom injection.

Wound evaluation

After venom injection, macroscopic evaluation of the wounds was made daily to enable the follow-up of injury evolution and differentiate between distinct treatment groups. The amount of venom injected induced a typical dermonecrotic lesion^(11,24) that began with a hemorrhagic halo 4 hours after injection, associated with edema, erythema, and exacerbated sensitiveness. After 48 hours, the hemorrhagic area turned into a bluish necrotic area. Four days later, a crust was formed that was later detached from the skin (Fig.2a). This typical evolution

confirmed the use of rabbits as good animal models for cutaneous loxoscelism^(5,25), unlike mice and rats, which do not develop dermonecrosis. It must be pointed out, however, that wound development in rabbits occurs faster than in humans^(2,5,6). This can be explained by structural differences between these two animals or the fact that experimentally produced wounds tend to be more controlled.

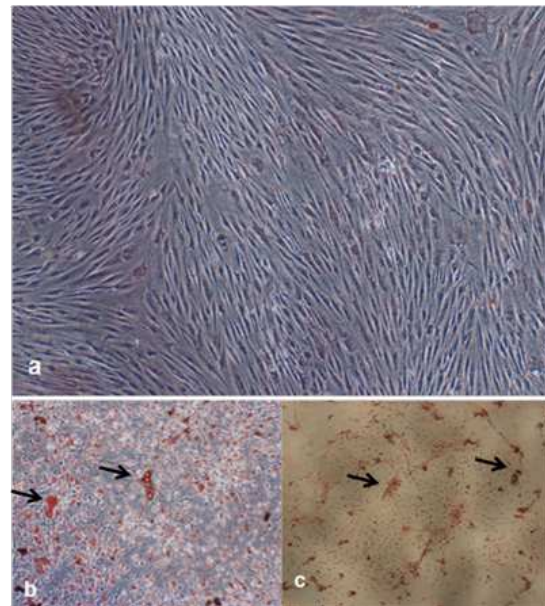


Figure 1. Photomicrographies from undifferentiated and differentiated mesenchymal stem cells (MSCs) derived from rabbit adipose tissue. **(a)** Undifferentiated MSCs cultured in unsupplemented media (400x). **(b)** MSCs cultured in specific media to induce adipogenic differentiation, stained with Oil Red (400x). Lipid droplets are marked red, demonstrating successful differentiation (arrows). **(c)** MSCs cultured in specific media to induce osteogenic differentiation, stained with von Kossa (400x). Mineralized matrix shows brownish coloration (arrows).

Morphometric evaluation and wound contraction rate

Through the evaluation of the mean values of wound contraction, statistical significance was observed at day 3 in all treatments, and dapsone showed the best percentage of wound contraction at that time. In the treatments using MSCs, a negative value of wound contraction was observed for the isolated MSCs, as well as a lower contraction value for the association of the MSC + DAP when compared to PBS group (Fig. 2i). This fact can be explained by the increase in initial inflammation after the application of stem cells, that may occur in the first days, because MSCs secrete a broad spectrum of bioactive molecules such as cytokines and growth factors that favor a regeneration

microenvironment^(26,27). No statistical difference was observed in the other days; however, it was observed that the treatments that received stem cells and dapsone were superior to the PBS group already on the sixth day ($P > 0.05$). This may suggest a positive influence on wound healing, since inflammatory factors and inflammatory cells start tissue regeneration by replenishment of cells and extracellular components.

MSC can contribute to a faster and more effective wound healing, due to reepithelization, fibroblast proliferation, and neovascularization stimuli, as observed by Kim et al.⁽²⁸⁾. These stimuli occur mainly by paracrine effect, through the production of soluble factors such as bioactive molecules and growth factors that promote a tissue repair microenvironment^(26,27).

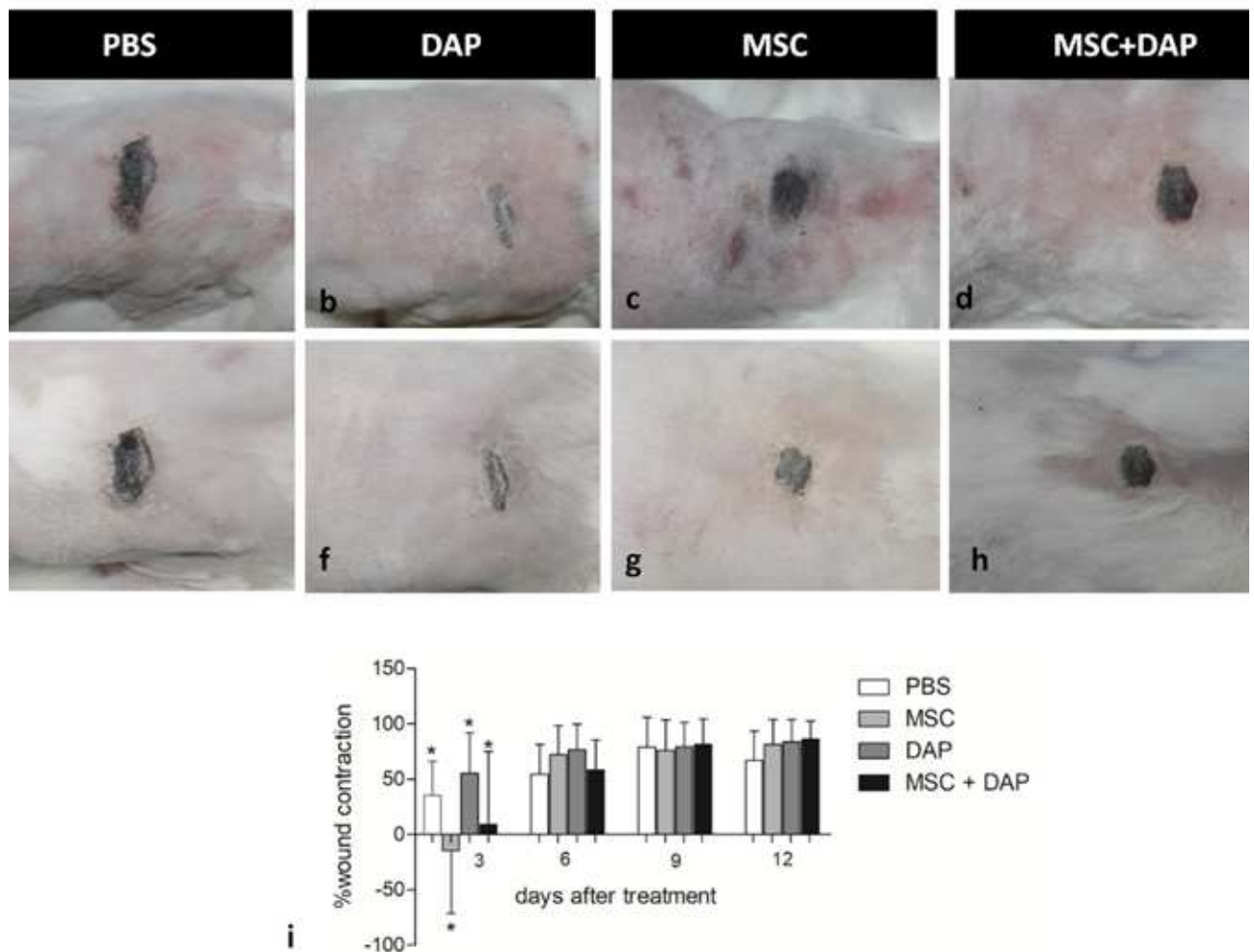


Figure 2. Dermonecrosis evolution of New Zealand rabbits after *Loxosceles laeta* venom (20 μ g) inoculation and treated with phosphate buffered saline (PBS), dapsone (DAP), mesenchymal stem cells (MSC) or in association of both MSC and DAP (MSC+DAP). (a,b,c,d) Dermonecrotic lesion in rabbits four days after starting treatment. (e,f,g,h) Dermonecrotic lesion in rabbits 12 days after starting treatment. (i) Mean values of percentage of wound retraction and standard deviation using a mixed linear model approach of SAS, using first-order autocorrelation covariate structure. Animals were considered as a random factor, with each animal nested within treatments, with repeated measurements over time. Significant day versus treatment interactions were examined using the PDIF procedure with preplanned comparisons. The significance level was set as $p < 0.05$. After *L. laeta* venom inoculation, groups were treated with either PBS (C+), mesenchymal stem cells (MSC), dapsone (DAP), or in association of both MSC and DAP (MSC+DAP). Measurements were taken 3, 6, 9, and 12 days after treatment.

Clinical assays using dapsone as treatment for wound repair show contrasting results. The benefits of dapsone in the treatment of dermonecrosis caused by loxoscelism have already been observed by Rees et al. (31), who used dapsone with or without precocious surgical tissue excision to treat patients. Barret et al. (33) also successfully used dapsone in an experimental model using guinea pigs. Conversely, Phillips et al. (20) and Elston et al. (25) did not observe statistical differences in wound retraction when using dapsone for treating rabbits. Morphometric analysis for obtaining the percentage of wound retraction during the scarring process has shown to be an efficient and accessible method (21,22). The evaluation of the rate of wound retraction instead of the wound area eliminates the differences caused by wounds of different initial sizes that can be formed, even when injecting the exact same amount of venom.

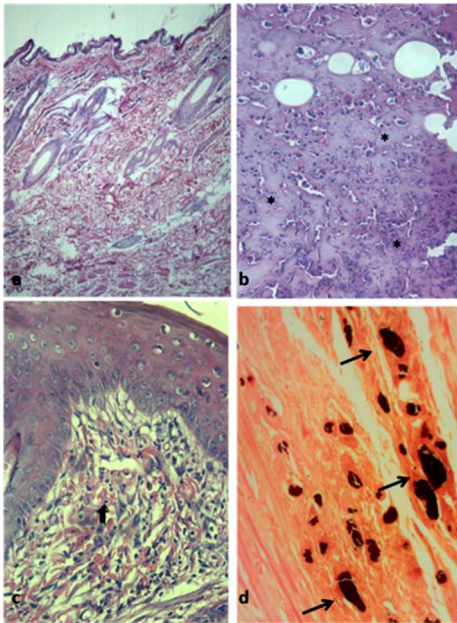


Figure 3. Microscopy of New Zealand rabbits' skin inoculated with *Loxosceles laeta* venom (C+) and treated with dapsone (DAP), mesenchymal stem cells (MSC) or in association of both MSC and DAP (MSC+DAP). (a) Normal skin showing integrity of epidermal and dermal cells (C-) (HE, 100x). (b) Presence of necrotic crust on the skin of envenomed rabbits that received PBS (C+) (*) (HE, 200x). (c) Presence of discrete inflammatory polymorphonuclear infiltrate (arrow) in animals treated with dapsone (DAP) (HE, 200x). (d) Multiple dark spots can be seen in the dermis, a sign of tissue calcification in the skin of animals treated with PBS (arrows) (Von Kossa, 100x).

Histopathological evaluation

When analyzing histopathological changes in HE staining of wounded skin sections, animals from the PBS group (C+) showed larger necrotic areas, intense neutrophilic infiltrate, intradermic hemorrhage, and mineralization spots (Fig. 3b), confirmed by von Kossa staining (Fig. 3d), as observed by Elston et al. (25) and

Ospedal et al. (29). Other studies also describe early eosinophilic infiltration (25,30) which was not observed in our study, probably due to the time elapsed from the beginning of treatment and sample collection.

Animals from the DAP group showed less significant lesions, with mineralization and angiogenesis areas, as was also seen in the MSC group (Fig. 3 c). Lesions in the MSC + DAP group were considerably more discrete and the inflammatory infiltrate was also less intense. Animals from the negative control group showed no changes (Fig. 3a). Tissue neutrophilic infiltration is considered one of the main causes of dermonecrotic lesions observed in loxoscelism (4,5). This fact was confirmed in the PBS (C+) group, which showed intense inflammatory infiltrate with neutrophil predominance, in addition to crust formation and damage to the epidermis and superficial and deep dermis (Fig. 3b).

In contrast, neutrophilic infiltrates were also more discrete in groups that showed less intense wounds, as occurred in the group treated with DAP, MSC and MSC + DAP. This fact can be explained by dapsone's anti-leukocyte aggregation effect, which has already been described by some authors (31,32,33,34). In addition, MSCs shows immunomodulatory effect that can attenuate inflammation and reprogram the local immune system, favoring tissue repair and inhibiting exuberant fibrosis (35,36).

The observations made in the groups that received MSC probably occurred due to positive stimulus on the local cells, such as keratinocytes and progenitor cells (27). MSCs have the ability to interact with the local microenvironment, attracting progenitor cells, differentiating in other tissues and producing a series of soluble factors, such as cytokines and growth factors that positively influence the scarring of chronic wounds, like the ones observed in cutaneous loxoscelism (27). Furthermore, MSCs have an immunomodulatory effect on skin local inflammation, suggesting it can be used in patients with hard-to-heal wounds (28).

Collagen fiber evaluation

Two different methods were used to assess the deposition of collagen fibers during the wound healing process: total collagen identification by Masson's trichrome staining and identification and quantification of mature and immature fibers by Picro-sirius Red staining (Fig 4 e 5). These collagen analyses are important to assess the scarring stage, since that is when collagenic organization and gradual substitution of immature by mature fibers can be observed (37).

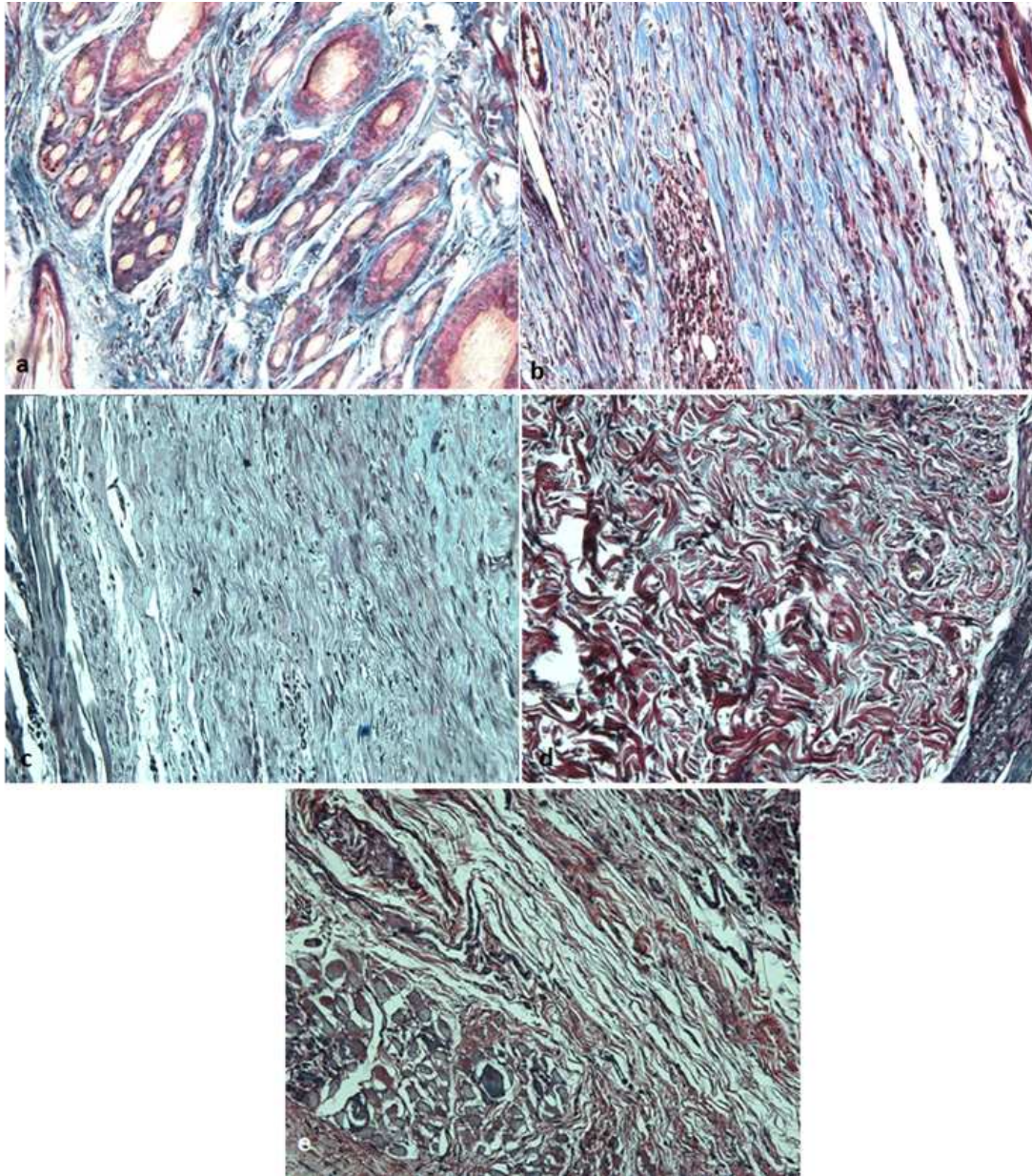


Figure 4. Collagen deposition analysis through Masson's trichrome of New Zealand rabbits' skin inoculated with *Loxosceles laeta* venom and treated with dapson (DAP), mesenchymal stem cells (MSC) or in association of both MSC and DAP (MSC+DAP). **(a)** Sample from a control group skin (C-) (200x). **(b)** Pattern of collagen deposition following *Loxosceles laeta* envenomation (C+) (*) (200x). **(c)** Collagen deposition in envenomed rabbits treated with dapson (DAP) (*) (200x). **(d)** Collagen deposition in envenomed rabbits treated with mesenchymal stem cells (MSC) (*) (200x). **(e)** Collagen deposition in envenomed rabbits treated with DAP and MSC (DAP-MSC) (*) (200x).

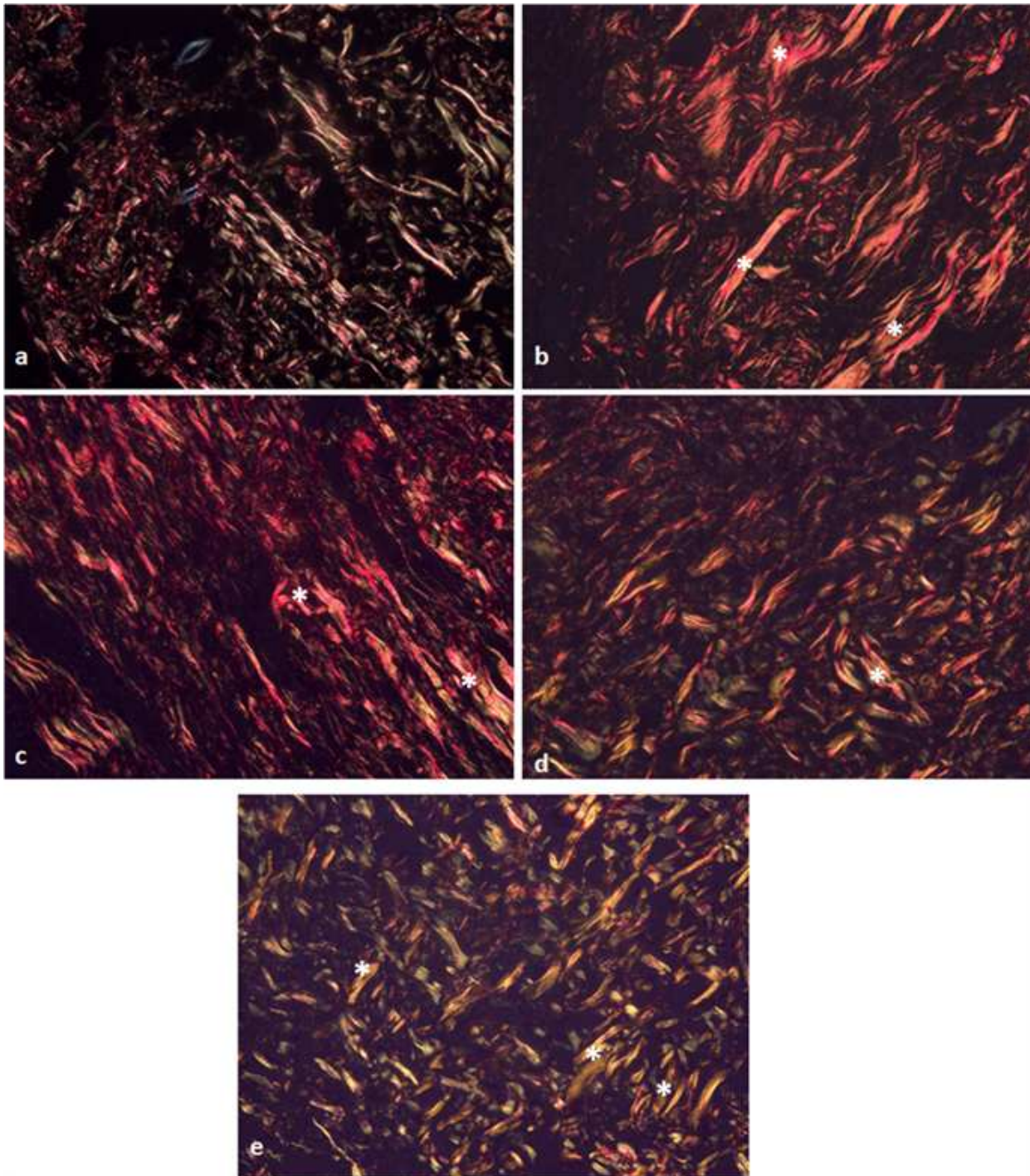


Figure 5. Collagen deposition analysis through Prico-Sirius stain of New Zealand rabbits' skin inoculated with *Loxosceles laeta* venom and treated with dapsone (DAP), mesenchymal stem cells (MSC) or in association of both MSC and DAP (MSC+DAP). **(a)** Sample from a control group skin (C-) (200x), **(b)** Pattern of collagen deposition following *Loxosceles laeta* envenomation (C+) (*) (200x), **(c)** Collagen deposition in envenomed rabbits treated with dapsone (DAP) (*) (200x), **(d)** Collagen deposition in envenomed rabbits treated with mesenchymal stem cells (MSC) (*) (200x), **(e)** Collagen deposition in envenomed rabbits treated with DAP and MSC (DAP-MSC) (*) (200x).

Animals submitted to treatment with DAP and MSC showed a higher number of total collagen fibers compared to the negative control group ($p < 0.05$) (Table I and figure 4). This may represent a synergic action between MSC and DAP, increasing stimulus for total collagen deposition.

Table I. Means of areas occupied in pixels by collagen in the skin of New Zealand rabbits according to the different types of treatments instituted after staining with Masson in samples collected 12 days after inoculation of *Loxosceles laeta* venom

Groups	Total collagen
Negative control	396125.70 A
Positive control (<i>L. laeta</i>)	582954.9 AB
Dapsone	679998.50 AB
MSC	590493.40 AB
Dapsone + MSC	742477.60 B

MSC: Mesenchymal Stem Cells. Different capital letters represent different statistical values in the columns by the test of Tukey where $p < 0.05$.

Immunohistochemical evaluation of angiogenesis

There was no noticeable statistical difference in the area occupied by blood vessels between the control group and all the tested treatments. Angiogenesis is a process of the proliferative phase of scarring and very important in wound healing evolution, occurring from intact or newly damaged capillaries. This event is modulated by the vascular endothelial growth factor (VEGF-A), produced by endothelial cells, macrophages, and active epidermal cells⁽³⁸⁾. It is generally accepted that MSC stimulates angiogenesis through macrophage chemotaxis and endothelial cells stimulation by pro-angiogenic factors, such as VEGF-A. The fact that there was no observable difference in neovascularization between the different groups can be explained by the sample collection timing. A study concerning wounds in dogs after treatment with MSCs corroborates this hypothesis. In this study, no difference in the number of blood vessels was observed 14 days after stem-cell treatment, but on day 21, a statistical difference in the treated groups could be seen⁽²⁸⁾.

Conclusions

The amount of *L. laeta* venom used in this study (20 µg) was capable of inducing a significant dermonecrotic lesion in rabbits. MSC may increase initial inflammation following application in the first few days, however as the time progresses it may contribute to wound healing. Histopathological analysis showed diminished tissue lesion and less intense inflammation in DAP e MSCs groups. This could have indicated some potential use of stem cells in regenerative therapies after loxoscelic accidents. Although few parameters presented statistical significance, treatment with DAP+MSC revealed potential to improve collagen deposition.

Additional studies could provide more evidence and are needed to define MSC and its association with dapsone as potential treatment options for cutaneous lesions of *Loxosceles*.

Declaration of conflict of interest

Authors declare no conflict of interests.

Author Contributions

Conceptualization: M.M. Melo, C.D.C. Olórtégui and A.M. Goes. *Data curation:* G.C. Martins, M.S.O. Barreto, A.F.M. Botelho and C. Gamba. *Formal analysis:* G.C. Martins. *Funding acquisition:* M.M. Melo. *Investigation:* G.C. Martins, M.S.O. Barreto, A.F.M. Botelho, C. Gamba and G.D. Cassali. *Methodology:* M.M. Melo, C.D.C. Olórtégui, A.M. Goes and G.D. Cassali. *Project management:* M.M. Melo. *Resources:* M.M. Melo, C.D.C. Olórtégui, A.M. Goes and G.D. Cassali. *Software:* G.C. Martins. *Supervision:* M.M. Melo. *Validation:* M.M. Melo, C.D.C. Olórtégui and A.M. Goes. *Visualization:* G.C. Martins, A.F.M. Botelho and C.G. Duarte. *Writing (original draft):* G.C. Martins, A.F.M. Botelho, C.G. Duarte, B.S. Blanco and A.C.V. Bicalho. *Writing (revision and edition):* G.C. Martins, M.M. Melo, A.F.M. Botelho and C.G. Duarte.

Funding

This work was supported by Conselho Nacional de Desenvolvimento Científico e Tecnológico – CNPq (Grant number 308754/2021-2).

References

- Andrade RMG, Lourenço WR, Tambourgi DV. Comparison of the fertility between *Loxosceles intermedia* and *Loxosceles laeta* spiders (Araneae, sicariidae). 2000. Journal of Arachnology. 2000; 28, 245-247.
- Malaque CMS, Castro-Valencia JE, Cardoso JLC, França FOS, Barbaro K, Fan HW. Clinical and epidemiological features of definitive and presumed loxoscelism in São Paulo, Brazil. Revista do Instituto de Medicina Tropical de São Paulo. 2002; 44,139-143. Available from: <http://dx.doi.org/10.1590/S0036-46652002000300005>.
- Miranda, ALS, Guerra-Duarte C., Lima, SA, Chávez-Olórtégui C, Soto-Blanco B. History, challenges and perspectives on *Loxosceles* (brown spiders) antivenom production in Brazil. Toxicon. 2021, 40-45. Available from: <https://doi.org/10.1016/j.toxicon.2021.01.004>
- Silva PH, Silveira RB, Appel MH, Mangili OC, Gremisk W, Veiga SS. Brown spiders and loxoscelism. Toxicon. 2004.44, 693-709. <https://doi.org/10.1016/j.toxicon.2004.07.012>.
- Smith CW, Micks DW. The role of polymorphonuclear leukocytes in the lesion caused by the venom of the brown spider. Laboratory Investigation 1970. 22, 90-93.
- Tambourgi DV, Gonçalves-de-Andrade RM, van den Berg CW. Loxoscelism: From basic research to the proposal of new therapies. Toxicon. 2010. 15;56(7):1113-9. Available from: <https://doi.org/10.1016/j.toxicon.2010.01.021>.
- Malaque CMS, Santoro ML, Cardoso JL, Conde MR, Novaes CTG, Risk JY, França FOS, Medeiros CR, Fan HW. Clinical picture and laboratorial evaluation in human loxoscelism. Toxicon.

2011. 58, 664-671. Available from: <https://doi.org/10.1016/j.toxicon.2011.09.011>.
8. Barbaro KC, Knysak I, Martins R, Hogan C, Winkel K. Enzymatic characterization, antigenic cross-reactivity and neutralization of dermonecrotic activity of five *Loxosceles* spider venoms of medical importance in the Americas. *Toxicon*. 2005. 45, 489-499. Available from: <https://doi.org/10.1016/j.toxicon.2004.12.009>.
9. Ministério da saúde, brasil. Manual de diagnóstico e tratamento de acidentes por animais peçonhentos. Brasília: assessoria de comunicação e educação em saúde – Fundação Nacional de Saúde. 2001. 45-56.
10. Peterson ME. Brown Spider Envenomation. Clinical techniques in Small Animal Practice. 2006. 21, 191-193. Available from: <https://doi.org/10.1053/j.ctsap.2006.10.004>.
11. Pauli I, Minozzo JC, Silva PH, Chaim OM, Veiga SS. Analysis of therapeutic benefits of antivenin at different time intervals after experimental envenomation in rabbits by venom of the brown spider (*Loxosceles intermedia*). *Toxicon*. 2009. 53, 660-671. Available from: <https://doi.org/10.1016/j.toxicon.2009.01.033>.
12. Costa TGF, Costal-Oliveira F, de Assis TCS, Lima SA, Martins CA, Finco AB, Veiga SS, Soccol VT, Machado-de-Ávila RA, Figueiredo LFM, Minozzo JC, Kalapothakis E, Guerra-Duarte C, Alvarenga LM, Chávez-Olórtegui C. Engineered antigen containing epitopes from *Loxosceles* spp. spider toxins induces a monoclonal antibody (Lox-mAb3) against astacin-like metalloproteases. *International Journal of Biological Macromolecules*. 2020. Nov 1;162:490-500. Available from: <https://doi.org/10.1016/j.ijbiomac.2020.06.176>.
13. Saavedra-Langer R, Costa TGF, Lima SA, Costal-Oliveira F, Martins CA, Machado-de-Ávila RA, Minozzo JC, Soccol VT, Guerra-Duarte C, Kalapothakis E, Chávez-Olórtegui C. A prokaryote system optimization for rMEPLox expression: A promising non-toxic antigen for *Loxosceles* antivenom production. *International Journal of Biological Macromolecules*. 2021 Sep 30;187:66-75. Available from: <https://doi.org/10.1016/j.ijbiomac.2021.07.042>.
14. Fortier LA. Stem cells: classifications, controversies, and clinical applications. *Veterinary Surgery*. 2005. 34, 415-423. Available from: <https://doi.org/10.1111/j.1532-950X.2005.00063.x>.
15. Minguell JJ, Erices A, Conget P. Mesenchymal stem cells. *Experimental Biology and Medicine*. 2001. 226, 507-520.
16. Jeong JH. Adipose Stem cells and skin repair. *Current Stem Cell Research and Therapy*. 2010. 5, 137-140.2010.
17. Gaur M, Dobke M, Lunyak VV. Mesenchymal stem cells from adipose tissue in clinical applications for dermatological indications and skin aging. *International Journal of Molecular Sciences*. 2017. 18, 208. Available from: <https://doi.org/10.3390/ijms18010208>.
18. Kim, W., Park, B., Sung, J., Yang, J., Park, S., Kwak, S., Park, J. Wound healing effect of adipose-derived stem cells: A critical role of secretory factors on human dermal fibroblasts. *Journal of Dermatological Science*. 2007. 48, 15-24. Available from: <https://doi.org/10.1016/j.jdermsci.2007.05.018>.
19. Kasperk C, Wergedal J, Strong D, Farley J, Wangerin K, Gropp H, Ziegler R, Baylink DJ. Human bone cell phenotypes differ depending on their skeletal site of origin. *The Journal of Clinical Endocrinology and Metabolism*. 1995. 80, 2511-2517. Available from: <https://doi.org/10.1210/jcem.80.8.7629252>.
20. Phillips S, Kohn M, Baker D, Vander Leest R, Gomez H, McKinney P, McGoldrick J, Brent J. Therapy of brown spider envenomation: a controlled trial of hyperbaric oxygen, dapsone, and cyproheptadine. *Annals of Emergency Medicine*. 1995. Mar;25(3):363-8. Available from: [https://doi.org/10.1016/S0196-0644\(95\)70296-2](https://doi.org/10.1016/S0196-0644(95)70296-2). PMID: 7864478.
21. Oliveira ST, Leme MC, Pippi NL, Raiser AG, Manfron MP. Preparations of comfrey (*Symphytum officinale*) on cutaneous wound healing in rats. *Revista da FZVA*. 2000. 7, 65-74
22. Wu Y, Chen L, Scott PG, Tredget EE. Mesenchymal stem cells enhance wound healing through differentiation and angiogenesis. *Stem Cells*. 2007. 25, 2648-2659.
23. Zhang J, Huang X, Wang H, Liu X, Zhang T, Wang Y, Hu D. The challenges and promises of allogeneic mesenchymal stem cells for use as a cell-based therapy. *Stem Cell Research and Therapy*. 2015. Available from: <https://doi.org/10.1186/s13287-015-0240-9>
24. Ferrara GIS, Fernandes-Pedrosa MF, Azevedo ILMJ, Andrade RMG, Portaro FCV, Almeida DM, Murakami M, Arni RK, Berg CW, Ho L, Tambourgi DV. Smase II, a new sphingomyelinase D from *Loxosceles laeta* venom gland: Molecular cloning, expression, function and structural analysis. *Toxicon*. 2009. 53, 743-753. Available from: <https://doi.org/10.1016/j.toxicon.2009.02.013>.
25. Elston DM, Miller SD, Young RJ, Eggers J, Mcglasson D, Schmidt WH, Bush A. Comparison of colchicine, dapsone, triamcinolone, and diphenhydramine therapy for the treatment of brown recluse spider envenomation. *Archives of Dermatology*. 2005. 141, 595-597. Available from: <https://doi.org/10.1001/archderm.141.5.595>.
26. Caplan AI. Adult mesenchymal stem cells for tissue engineering versus regenerative medicine. *Journal of Cellular Physiology*. 2007. 213, 341-347. Available from: <https://doi.org/10.1002/jcp.21200>.
27. Harman RJ. Stem cell therapy in veterinary dermatology. *Veterinary Dermatology*. 2013. 24, 90-e24. Available from: <https://doi.org/10.1111/vde.12000>.
28. Kim JW, Lee JH, Lyoo YS, Jung DI, Park HM. The effects of topical mesenchymal stem cell transplantation in canine experimental cutaneous wounds. *Veterinary Dermatology*. 2013. 24, 242-253. Available from: <https://doi.org/10.1111/vde.12011>.
29. Ospedal KZ, Appel MH, Neto JF, Mangili OC, Sanches V, Gremski W. Histopathological findings in rabbits after experimental acute exposure to the *Loxosceles intermedia* (brown spider) venom. *International Journal of Experimental Pathology*. 2002. 83, 287-294.
30. Maynor ML, Moon RE, Klitzman B, Fracica PJ, Canada A. Brown recluse spider envenomation: a prospective trial of hyperbaric oxygen therapy. *Academic Emergency Medicine*. 1997. 4, 184-192.
31. Rees RS, Altenbern DP, Lynch JB, King Jr LE. Brown recluse spider bites. A comparison of early surgical excision versus dapsone and delayed surgical excision. *Annals of Surgery*. 1985. 202, 659-663.
32. Booth SA, Moody CE, Dahl MV, Herron MJ, Nelson RD. Dapsone suppresses integrin-mediated neutrophil adherence function. *Journal of Investigative Dermatology*. 1992. 98, 135-40.
33. Barret SM, Jenkins MR, Fisher DE. Dapsone or electric Shock therapy of brown recluse spider envenomation? *Annals of Emergency Medicine*. 1994. 24, 21-25.
34. Hogan CJ, Barbaro KC, Winkel K. Loxoscelism: old obstacles, new directions. *Annals of Emergency Medicine*. 2004. 44, 608-624. Available from: <https://doi.org/10.1016/S0196064404013149>.
35. Nauta AJ, Fibbe WE. Immunomodulatory properties of mesenchymal stromal cells. *Blood*. 2007. 110, 3499-3506. Available from: <https://doi.org/10.1182/blood-2007-02-069716>.

36. Jackson WM, Nesti LJ, Tuan, RS. Mesenchymal stem cell therapy for attenuation of scar formation during wound healing. *Stem Cell Research and Therapy*. 2012. 3, 1-9. Available from: <https://doi.org/10.1186/scrt111>.

37. Reinke JM, Sorg H. Wound repair and regeneration. *European Surgical Research* 2012. 49, 35-43. Available from: <https://doi>

[.org/10.1159/000339613](https://doi.org/10.1159/000339613).

38. Hosgood G. Reparo de Feridas e Resposta Tecidual Específica à Lesão. In: SLATTER, D. *Manual de cirurgia de pequenos animais*. New York: Elsevier Science. 2003. Cap. 4, 66-86.