

MORPHOMETRIC ANALYSIS OF THE SURGICAL CORRIDOR IN THE PRE-PSOAS APPROACH: AN MRI STUDY IN THE BRAZILIAN POPULATION

ANÁLISE MORFOMÉTRICA DO CORREDOR CIRÚRGICO NO ACESSO PRÉ-PSOAS: UM ESTUDO POR RESSONÂNCIA MAGNÉTICA DA COLUNA LOMBAR NA POPULAÇÃO BRASILEIRA

ANÁLISIS MORFOMÉTRICA DEL CORREDOR QUIRÚRGICO EN EL ACCESO PREPSOAS: UN ESTUDIO DE RESONANCIA MAGNÉTICA DE LA COLUMNA LUMBAR EN LA POBLACIÓN BRASILEÑA

GABRIEL CARVALHO LACERDA^{1,2} , GUILLERMO JULIO TATIS¹ , MIGUEL LOZANO RAYMUNDO¹ , LUCIENE MOTA ANDRADE³ , CRISTIANO MAGALHÃES MENEZES^{1,2} 

1. Instituto Columna, Belo Horizonte, MG, Brasil.

2. Hospital Vila da Serra, Department of Orthopedics/Spine Surgery, Belo Horizonte, MG, Brasil.

3. Hospital Vera Cruz, Department of Radiology, Belo Horizonte, MG, Brasil.

ABSTRACT

Objective: This study aims to perform a morphometric analysis and explore the characteristics of the surgical corridor of the anterior to psoas approach in the Brazilian population through magnetic resonance imaging (MRI). **Methods:** Two hundred spinal MRI scans of patients aged between 18 and 80 years were evaluated using axial cuts at L2-L5 levels and a sagittal cut, T2 weighted. The relationship between the left psoas muscle and the abdominal aorta or the left common iliac artery was analyzed. The anterior to psoas corridor was defined as the shortest distance between the posterolateral aspect of the aorta or inferior vena cava or the nearest iliac vessel and the anteromedial aspect of the ipsilateral psoas muscle. **Results:** 104 females and 96 males with a mean age of $49,68 \pm 2,04$ (range 18–80) years. The mean anterior to psoas distance at the L2-L3 level was $14,17 \pm 0,75$ mm; at the L3-L4 level was $12,08 \pm 0,77$ mm and at the L4-L5 level was $9,12 \pm 0,77$ mm. The surgical corridors at all levels were larger in the older population. **Conclusion:** In most Brazilian patients, the anterior to psoas approach can be a good alternative for lumbar intervertebral fusions. As a routine in preoperative examination and surgical planning, lumbar MRI is fundamental in preoperative evaluation for anterior to psoas approach surgery. **Level of Evidence IV; Descriptive study.**

Keywords: Spine; Magnetic Resonance; Back pain.

RESUMO

Objetivo: O objetivo deste estudo é realizar uma análise morfométrica e explorar as características do corredor cirúrgico da via anterior ao psoas na população brasileira, através de exames de ressonância magnética. **Métodos:** Duzentos exames de ressonância magnética da coluna lombar de pacientes entre 18 e 80 anos foram avaliados, utilizando cortes axiais nos níveis L2-L5 e um corte sagital na ponderação T2. A relação entre o músculo psoas esquerdo e a aorta abdominal ou a artéria ilíaca comum esquerda foi analisada. O corredor anterior ao psoas foi definido como a menor distância entre a face posterolateral da aorta ou veia cava inferior ou o vaso ilíaco mais próximo e a face anteromedial do músculo psoas ipsilateral. **Resultados:** A população estudada foi de 104 mulheres e 96 homens com idade média de $49,68 \pm 2,04$ (18-80) anos. A média da distância anterior ao psoas no nível L2-L3 foi de $14,17 \pm 0,75$ mm; no nível L3-L4 foi de $12,08 \pm 0,77$ mm e no nível L4-L5 foi de $9,12 \pm 0,77$ mm. Os corredores cirúrgicos em todos os níveis foram considerados maiores na população idosa. **Conclusão:** A abordagem anterior ao psoas pode ser uma boa alternativa para a fusão intervertebral lombar na maioria dos pacientes brasileiros. Como rotina no exame pré-operatório e no planejamento cirúrgico, a ressonância magnética lombar tem fundamental importância na avaliação pré-operatória de cirurgias de abordagem anterior ao psoas. **Nível de Evidência IV; Estudo descritivo.**

Descritores: Coluna vertebral; Ressonância Magnética; Dor lombar.

RESUMEN

Objetivo: El objetivo de estudio es realizar un análisis morfométrico y explorar las características del corredor quirúrgico de la vía anterior al psoas en la población brasileña, a través de resonancias magnéticas (RM). **Métodos:** Se evaluaron 200 RM de la columna lumbar de pacientes entre 18 y 80 años, utilizando cortes axiales a niveles L2-L5 y un corte sagital, con ponderación T2. Se analizó la relación entre el músculo psoas izquierdo y la aorta abdominal o la arteria ilíaca común izquierda. El corredor anterior al psoas se definió como la distancia más corta entre la cara posterolateral de la aorta o la vena cava inferior o el vaso ilíaco más cercano y la cara anteromedial del músculo psoas ipsilateral. **Resultados:** La población estudiada estuvo constituida por 104 mujeres y 96 hombres con una edad media de $49,68 \pm 2,04$ (18-80) años. La distancia media anterior al psoas en nivel L2-L3 fue de $14,17 \pm 0,75$ mm; en el nivel L3-L4 fue de $12,08 \pm 0,77$ mm y en

Study conducted by Instituto Columna, Rua Conde de Linhares, 278 - Cidade Jardim, Belo Horizonte, MG, Brazil.

Correspondence: Cristiano Magalhães Menezes. 278, Conde de Linhares, Cidade Jardim, Belo Horizonte, MG, Brazil. 30380-030. cristiano@vertebral.com.br



el nivel L4-L5 fue de $9,12 \pm 0,77$ mm. Los corredores quirúrgicos en todos niveles se consideraron más grandes en la población anciana. **Conclusión:** El abordaje del psoas anterior puede ser una alternativa para la fusión intervertebral lumbar en la mayoría de los pacientes brasileños. Como rutina en examen preoperatorio, la resonancia magnética lumbar es importante en la evaluación preoperatoria de cirugías con abordaje anterior del psoas. **Nivel de Evidencia IV; Estudio descriptivo.**

Descriptor: Columna espinal; Resonancia magnética; Dolor de espalda.

INTRODUCTION

Minimally Invasive Surgery (MIS) of the spine has become very popular in the past few decades. Advances in surgical techniques and instruments have allowed minimally invasive surgical approaches to become a safe alternative to traditional open techniques and often the preferred choice for many spine surgeons.¹⁻⁷ These new minimally invasive approaches mainly include anterior intervertebral lumbar fusion (ALIF), lateral/extreme lumbar intervertebral fusion (LLIF/XLIF), and oblique intervertebral lumbar fusion (OLIF/ATP).⁸

The OLIF/ATP, which uses the pre-psoas access to the lumbar spine, will be the focus of our study and was first described by Silvestre et al., in 2012.⁹ Unlike the LLIF/XLIF transpsoas, the pre-psoas approach makes the most of the natural cavity between the psoas muscle and the blood vessels to gain access to the spine and the intervertebral discs.

Although there is a natural corridor, some complications, such as vascular injury, can occur. Previous studies on the Japanese population have reported the incidence of vascular damage to occur between 0.8% to 10%.^{10,11,12} Mehren et al. published, in 2016, a study in which the authors reviewed complications in 812 patients undergoing the pre-psoas technique. 3.7% of patients had a complication intraoperatively or during their hospital stay. The percentage of vascular and neurological complications was found in 3 patients (0.37%).¹³ To minimize possible vascular damage and other noble structures, such as the ureter, it is important to analyze some characteristics of the surgical corridor in the anterior to psoas (ATP) approach. Some intraoperative techniques can be used to minimize the risk of injury to important structures, such as psoas muscle retraction.¹³ However, the retraction of the muscle means that the pre-psoas access is not completely free from causing damage to the muscle.

A clear understanding of the anatomical characteristics and regularities of the surgical corridor of the pre-psoas access can be an effective measure to avoid these intraoperative complications. This study aims to perform a morphometric analysis and explore the availability of a realistic surgical corridor in the pre-psoas approach. The MRI of the lumbar spine and the relationship between the left psoas muscle and the abdominal aorta or the left common iliac artery were retrospectively analyzed and studied to assess the availability of a realistic surgical corridor in the pre-psoas approach and thus the safety of performing pre-psoas access in the Brazilian population.

METHODS

Two hundred lumbar spine magnetic resonance imaging (MRI) scans were evaluated. The exams were chosen randomly from patients between 18 to 80 years of age who sought medical attention with a complaint of low back pain/sciatica between January 2018 and June 2020 at a tertiary center in Brazil.

Patients outside the age range or who had previously undergone posterior lumbar spine instrumentation, retroperitoneal surgical procedure, or those with abdominal vascular diseases, malformations, or intra-abdominal tumors were excluded.

The study was submitted and approved by the institution's ethics committee (CAAE: 35586520.7.0000.5135), which granted us exemption from the "free and informed consent" (TCLE) to carry out this project, considering that it only used data obtained from magnetic resonance scans. Furthermore, the study respected the privacy and confidentiality of the subjects and the confidential data involved in the research and ensured that the data would not be disclosed.

The relationship between the left psoas muscle and the abdominal aorta or the left common iliac artery was retrospectively analyzed. In addition, L2-3, L3-4, and L4-5 axial and sagittal images were studied, and morphometric parameters associated with the anterior to psoas approach were measured and recorded. The anterior to psoas corridor was defined as the shortest distance between the posterolateral aspect of the aorta or inferior vena cava or the nearest iliac vessel and the anteromedial aspect of the ipsilateral psoas muscle. (Figure 1) All measurements were recorded at the axial cut at the level of the disc studied.

All exams were initially reviewed and evaluated by the service's chief radiologist. Then, measurements were taken by a spine fellow under the supervision of the senior spine surgeon (CMM) and senior radiologist (LMA) using the institution's digital radiological repository (Carestream Health®). Statistical analysis was performed using the software Wizard Pro®. The likelihood-ratio chi-square test was used for independent samples, with a significance level of p-value < 0.05.

RESULTS

There were 104 females and 96 males with a mean age of $49,68 \pm 2.04$ (range 18–80) years. Surgical corridors anterior to psoas at the L2-L5 disc levels were found in most magnetic resonance imaging scans studied. The surgical corridor had its largest size at the most cranial level and decreased in size until the most caudal level. The mean anterior to psoas distance at all levels is summarized in Table 1. The L2-L3 level was $14,17 \pm 0.75$ mm; the L3-L4 level was $12,08 \pm 0.77$ mm; and the L4-L5 level was $9,12 \pm 0.77$ mm. Each level's bare window size did not significantly differ between males and females (p = 0.955). (Table 2) The surgical corridors at all levels were statistically significant in older populations (p = 0.000). (Table 3)

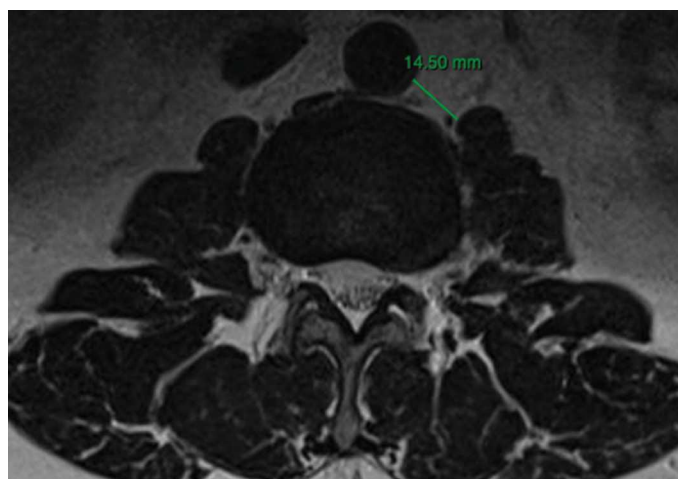


Figure 1. Anterior to psoas corridor (ATP).

Table 1. Anterior to psoas distance at all levels.

Level	Mean distance (mm)
L2-L3	14.17±0.75
L3-L4	12.08±0.77
L4-L5	9.12±0.77

p value = 0.000.

Table 2. Anterior to psoas distance by sex.

Level	Mean distance (mm)	
	M	F
L2-L3	15.83±1.99	13.77±1.63
L3-L4	14.81±2.25	12.09±1.52
L4-L5	10.32±2.52	9.66±2.13

p value = 0.955.

Table 3. Anterior to psoas distance by age.

Age group	Level	Mean distance (mm)
18 - 39	L2-L3	12.50±1.32
	L3-L4	9.93±1.33
	L4-L5	5.53±1.29
40 - 59	L2-L3	14.15±1.04
	L3-L4	11.17±1.00
	L4-L5	8.49±1.22
60 - 80	L2-L3	15.82±1.67
	L3-L4	15.82±1.53
	L4-L5	13.79±2.11

p value = 0.000.

DISCUSSION

Since its initial description, lumbar interbody fusion has become a surgical treatment for various spine pathologies: degenerative, traumatic, infectious, and tumoral. Advances in surgical techniques and instruments in spinal surgery have allowed the development of minimally invasive approaches, standing out as an alternative and a safe resource to traditional open surgery for many specialists. A clear understanding of the anatomical characteristics of the spine has allowed the development of access through the anterior corridor to the psoas in the lumbar spine.¹⁴

The lumbar interbody fusion anterior to the psoas is a popular technique within the minimally invasive approaches for spine surgery, with advantages such as minimal bleeding and tissue damage and preservation of the posterior tension band.^{1,3,4,15} The surgical corridor allows the placement of inter somatic devices that contribute to increasing disc height and can generate indirect decompression, improving sagittal and coronal alignment and the advantages of a lower risk of lumbar plexus injury.¹⁵ These techniques have specific complications related to the approach. It is reported that the left-sided ATP approach is viable in both sexes. The ATP approach for the L1-L2 and L2-L3 discs is feasible regardless of age, while L3-L4 and L4-L5 are more feasible in older patients, especially men. The right approach is less likely to be done effectively due to the presence of the vena cava and right iliac vein.^{16,17} The size of the retroperitoneal oblique corridor is also observed to decrease in the cephalo-caudal direction, limiting access to the L4-5 disc space.¹⁷ This was found to be true in our study as well.

The anterior to the psoas approach has been described as a technique that utilizes a theoretically natural corridor in the lumbar spine, sparing bone, ligaments, and muscles, allowing access to the L2-L5 disc spaces with minimal psoas retraction and without significant tendon disruption.¹⁴ This is also supported by magnetic resonance studies concluding that the access to the oblique corridor of the L2-L5 discs is found in 90% of the magnetic resonance images (99% L2-L3, 100% L3-L4, and 91% L4-L5).^{18,19} Molinares et al.,¹⁴ in a series of 133 patients in the American population, found that the mean surgical corridors were 16.04mm at L2-L3, 14.21mm at L3-L4, and 10.28mm at L4-L5. Our results are similar at all levels.

Another study by Zhang et al.¹⁹ compared the ATP oblique corridor in supine and lateral MRI exams and had homogeneous results in the supine position; the mean distance of L2-L3 was 13.49mm, L3-L4 was 13.08mm, and L4-L5 was 8.64mm. They found that the corridor significantly decreases from the supine to the right lateral decubitus position, possibly due to the relaxed psoas deformation. Boghani et al.¹⁶ reviewed three hundred MRI exams and reported slightly larger anterior to psoas distances in all levels, especially in the L4-L5 level, in which they reported a mean distance of 14.8 ± 7.8 cm.¹⁶ All studies support using MRI to predetermine the presence of the oblique corridor for access to the intervertebral disc spaces between L2-L5 before lumbar spine surgery. Julian Li et al.¹⁷ demonstrated that the regional anatomy of each level related to the anterior to psoas approach has its singularities, and not all levels are appropriate for this technique. The authors studied the magnetic resonance images of two hundred randomly selected Australian patients. They found that L2-L3 disc level is feasible regardless of age, while L3-L4 and L4-L5 might be more appropriate in older patients, especially in males.¹⁷

Analysis of the prevalence, size, location of the oblique corridor, and morphology of the psoas muscle at the L4-L5 level studied by Ng et al.,¹⁵ recommends that quantitative values and grades based on a standardized classification should be considered, recommending a preoperative evaluation of the anatomy. The authors proposed a classification of the oblique corridor categorized into four grades: Grade 0 = no corridor, Grade 1 = small corridor (≤ 1 cm), Grade 2 = moderate corridor (1-2 cm), and Grade 3 = large corridor (> 2 cm). The results found that 25% of their patients had no anatomic corridor caused by vascular obstruction (grade 0 = 10.5%) or increased psoas incursion.¹⁵ Of the surgical corridors considered feasible, 35% were grade 1; that is, they measured 0- 1 cm, and 37.5% were grade 2, between 1-2 cm. These results meant that only 17,3% of the patients had a natural surgical corridor suitable for the anterior to psoas approach.¹⁵ Louie et al.²⁰ studied the morphology of the psoas and their association with neurovascular structures at L4-L5. In cases of common transitional anatomy, the presence of tear-shaped psoas anatomy at this level is confirmed, associated with an anterior migration of the lumbar plexus and posterolateral migration of the iliac vasculature, which may increase the risk of the oblique-lateral approach at this level.^{20,21}

If we consider the classification proposed by Ng et al.¹⁵ in our study at the L4-L5 level, we found that 23 patients (11.5%) were grade 0; 84 (42%) were grade 1; 66 (33%) grade 2 and only 17 (8%) had an appropriate surgical corridor with more than 2cm, the distance that enables the placement of a conventional cage, which measures 22mm in width, without any disruption of the psoas muscle.

It is the first study to describe the anterior to psoas corridor in the Brazilian population.

CONCLUSION

In most Brazilian patients, the anterior to psoas approach can be a good alternative for lumbar intervertebral fusion. The elderly population has a larger surgical corridor in the anterior to psoas approach. It thus is more likely to have an easier approach without retracting the psoas muscle. As a routine in preoperative examination and surgical planning, lumbar MRI is fundamental in preoperative evaluation for anterior to psoas approach surgery.

All authors declare no potential conflict of interest related to this article.

CONTRIBUTIONS OF THE AUTHORS: Each author contributed individually and significantly to the development of this article. GCL: data measures, data analysis, statistical analysis, writing, review; GJT: writing, review; MLR: writing, review; LMA: a review of data measures; CMM: writing, data analysis, and final review.

REFERENCES

1. Baron EM, Davis T, Anand N. The transposas approach for thoracolumbar interbody fusion. In: Vaccaro AR, Baron EM (eds). *Spine Surgery: Operative Techniques*. Philadelphia: Elsevier Saunders; 2012. p. 314-26.
2. Klimov VS, Vasilenko II, Rzaev, JA, Evsyukov AV, Khalepa RV, Amelina, EV, et al. LLIF in the correction of degenerative scoliosis in elderly patients. *Coluna/ Columna*. 2020;19(4):243-8.
3. Berjano P, Balsano M, Buric J, Petrucci M, Lamartina C. Direct lateral access lumbar and thoracolumbar fusion: preliminary results. *Eur Spine J*. 2012;21(Suppl 1):S37-S42.
4. Amaral R, Marchi L, Oliveira L, Coutinho T, Castro C, Coutinho, E, et al. Minimally invasive lateral option for thoracic-lumbar intersomatic arthrodesis. *Coluna/ Columna*. 2011;10(3):239-43.
5. Mundis GM, Akbarnia BA, Phillips FM. Adult deformity correction through minimally invasive lateral approach techniques. *Spine (Phila Pa 1976)*. 2010;35(Suppl 26):S312-21.
6. Le TV, Uribe JS. The minimally invasive retroperitoneal transposas approach. In: *Spine Surgery*. Rijeka, Croatia: InTech; 2012.
7. Pimenta L, Oliveira L, Schaffa T, Coutinho E, Marchi L. Lumbar total disc replacement from an extreme lateral approach: clinical experience with a minimum of 2 years' follow-up. *J Neurosurg Spine*. 2011;14(1):38-45.
8. Mobbs RJ, Phan K, Malham G, Seex K, Rao PJ. Lumbar interbody fusion: techniques, indications and comparison of interbody fusion options including PLIF, TLIF, MI-TLIF, OLIF/ATP, LLIF and ALIF. *J Spine Surg*. 2015;1(1):2-18. doi:10.3978/j.issn.2414-469X.2015.10.05.
9. Silvestre C, Mac-Thiong JM, Hilmi R, Roussouly P. Complications and morbidities of mini-open anterior retroperitoneal lumbar interbody fusion: oblique lumbar interbody fusion in 179 patients. *Asian Spine J*. 2012;6(2):89-97.
10. Ohtori S, Orita S, Yamauchi K, Eguchi Y, Ochiai N, Kishida S, et al. Mini-open anterior retroperitoneal lumbar interbody fusion: oblique lateral interbody fusion for lumbar spinal degeneration disease. *Yonsei Med J*. 2015;56(4):1051-9.
11. Fujibayashi S, Kawakami N, Asazuma T, Ito M, Mizutani J, Nagashima H, et al. Complications associated with lateral interbody fusion: nationwide survey of 2998 cases during the first 2 years of its use in Japan. *Spine*. 2017;42(19):1478-84.
12. Li J, Wang X, Sun Y, Zhang F, Gao Y, Li Z, et al. Safety Analysis of Two anterior lateral lumbar interbody fusions at the initial stage of learning curve. 2019;127:e901-9.
13. Mehren C, Mayer HM, Zandanell C, Siepe CJ, Korge A. The Oblique Anterolateral Approach to the Lumbar Spine Provides Access to the Lumbar Spine with Few Early Complications. *Clin Orthop Relat Res*. 2016;474(9):2020-7. doi:10.1007/s11999-016-4883-3.
14. Molinares DM, Davis TT, Fung DA. Retroperitoneal oblique corridor to the L2-S1 intervertebral discs: an MRI study. *J Neurosurg Spine*. 2016;24(2):248-55. doi: 10.3171/2015.3.SPINE13976.
15. Ng JP, Kaliya-Perumal AK, Tandon AA, Oh JY. The Oblique Corridor at L4-L5: A Radiographic Anatomical Study into the Feasibility for Lateral Interbody Fusion. *Spine (Phila Pa 1976)*. 2020;45(10):E552-E559. doi: 10.1097/BRS.0000000000003346. Erratum in: *Spine (Phila Pa 1976)*. 2020;45(15):E977.
16. Boghani Z, Steele WI, Barber SM, Lee JJ, Sokunbi O, Blacklock JB, et al. Variability in the size of the retroperitoneal oblique corridor: A magnetic resonance imaging-based analysis. *Surg Neurol Int*. 2020;11:54. doi: 10.25259/SNI_438_2019.
17. Julian Li JX, Mobbs RJ, Phan K. Morphometric MRI Imaging Study of the Corridor for the Oblique Lumbar Interbody Fusion Technique at L1-L5. *World Neurosurg*. 2018;111:e678-85. doi: 10.1016/j.wneu.2017.12.136.
18. Liu L, Liang Y, Zhang H, Wang H, Guo C, Pu X, et al. Imaging Anatomical Research on the Operative Windows of Oblique Lumbar Interbody Fusion. *PLoS One*. 2016;11(9):e0163452. doi: 10.1371/journal.pone.0163452.
19. Zhang F, Xu H, Yin B, Tao H, Yang S, Sun C, et al. Does right lateral decubitus position change retroperitoneal 7 oblique corridor? A radiographic evaluation from L1 to L5. *Eur Spine J*. 2017;26(3):646-50.
20. Louie PK, Narain AS, Hijji FY, Yacob A, Yom KH, Phillips FM, et al. Radiographic Analysis of Psoas Morphology and its Association With Neurovascular Structures at L4-5 With Reference to Lateral Approaches. *Spine (Phila Pa 1976)*. 2017;42(24):E1386-E92.
21. Kaliya-Perumal AK, Ng JPH, Soh TLT, Yap WMQ, Tan M, Yu CS, et al. Reliability of the new modified Moro's classification and oblique corridor grading to assess the feasibility of oblique lumbar interbody fusion. *J Orthop*. 2020;21:321-5. doi: 10.1016/j.jor.2020.05.018.