

Management of Mucocele of the Glands of Blandin-Nuhn With a High-Intensity Laser: A Case Report



Rayla Bentes Kato¹, Humberto Jácome-Santos², Ana Paula Guerreiro Rodrigues Couto¹, Lucas Guimarães Abreu³, Ricardo Alves Mesquita², Camila Nazaré Alves de Oliveira Kato^{2*}

¹School of Dentistry, Centro Universitário do Pará – CESUPA, Belém, Pará, Brazil

²Department of Oral Pathology and Surgery, School of Dentistry, Universidade Federal de Minas Gerais, Belo Horizonte, Minas Gerais, Brazil

³Department of Pediatric Dentistry and Orthodontics, School of Dentistry, Universidade Federal de Minas Gerais, Belo Horizonte, Minas Gerais, Brazil

*Correspondence to

Camila Nazaré Alves de Oliveira Kato,
Universidade Federal de Minas Gerais
Faculdade de Odontologia, sala 3202D.
Av. Antônio Carlos, 6667
Pampulha 31.270-010
Belo Horizonte, MG, Brasil.
Tel: 55-31-31-3409-2499;
Email: cnao20@yahoo.com.br

Received: October 16, 2020

Accepted: February 21, 2021

Published: June 20, 2021



Abstract

Introduction: The glands of Blandin–Nuhn are mucous and serous salivary glands situated on both sides of the midline of the ventral surface of the tongue. In this area, a mucocele generally results from trauma. The diagnosis of mucoceles is based on clinical and histopathological examinations and the recommended treatment is surgical excision.

Case Report: This report describes a case of mucocele of the glands of Blandin-Nuhn (MGBN) affecting a 20-year-old male. Oval-shaped swelling with a smooth and bright surface of soft consistency was observed on the ventral surface of the individual's tongue. The diagnostic hypothesis was mucocele. Surgical excision was performed in a single session with a diode laser. A histopathological examination revealed mucus extravasating into connective tissue, with foamy macrophages and granulation tissue.

Conclusion: The high-intensity laser was a safe and effective tool for treating MGBN. No need for a suture, minimal or no intraoperative bleeding, and a minimal report of pain and edema by the patient were observed. A diode laser may be a helpful tool because it is less invasive and it is safe and effective.

Keywords: Mucocele; Glands of Blandin-Nuhn; High-intensity laser; Laser therapy.

Introduction

Mucocele is a benign lesion that affects the minor salivary glands. Swelling similar to vesiculobullous or nodular lesions of the translucent aspect or bluish color occurs due to the extravasation or retention of mucus, associated with trauma (92%) or obstruction of the gland duct (8%). Mucocele is frequent in glands of the lower lip of young people.¹⁻³ The tongue has three sets of minor salivary glands located in different regions; the glands of Weber on the lateral border of the tongue, the glands of von Ebner around circumvallated and foliate papillae, and the glands of Blandin-Nuhn in the deep portion of the ventral tongue. Mucocele of the glands of Blandin-Nuhn (MGBN) is uncommon^{4,5} possibly due to the muscles of the region that act as a protection. The rupture of the gland duct by trauma is the main causal factor of MGBN.⁶ Treatments for MGBN have been proposed according to the size of the lesion. Small mucoceles are removed along with the neighboring glands and large mucoceles may be treated by marsupialization or micro-marsupialization. A conventional surgical excision performed with a scalpel or

electrocautery is the main choice of treatment.² Lasers of different wavelengths have been used to treat mucocele in the lip region.⁷⁻⁹ A deep localization of MGBN may require a more invasive technique. A high-intensity laser has the advantage of providing a minimum of intraoperative and postoperative bleeding as well as comfort for the patient.⁹ The diode laser is a high-intensity laser with an 808 nm wavelength with an affinity for pigmented tissue and water. Its use results in areas of coagulation, vaporization and carbonization in the region.⁸ Thus, a high-intensity laser may be a useful tool for the treatment of MGBN. This report describes the case of a patient with an MGBN treated with a high-intensity laser. The report is creating interest because it shows the advantages of surgical excision with a high-intensity laser of a rare lesion, located on the ventral surface of the tongue. Additionally, conventional surgery on the ventral surface of the tongue can result in excessive bleeding, postoperative pain and edema as well as the necessity of suture.

Case Report

A 20-year-old male patient sought the Oral Medicine service of the School of Dentistry, Universidade Federal of Minas Gerais (UFMG), Brazil, for the diagnosis and treatment of a lesion in the tongue. The lesion was asymptomatic, with primary manifestation nine months before the appointment at the service. The patient reported that he had undergone surgical excision of a previous lesion at another oral health service in the same area. The previous histopathological examination had revealed a diagnosis of pyogenic granuloma. The medical or dental history was not contributory. Clinical examination showed an oval-shaped swelling with non-ulcerated mucosa, smooth and bright surface, soft consistency, and 3 × 6 mm in size in the midline of the ventral surface of the tongue (Figure 1A). The clinical diagnosis was mucocele, with the differential diagnosis for vascular anomalies, fibrous hyperplasia, pyogenic granuloma and lipoma. Surgical excision of the lesion using a high-intensity laser was proposed to the patient. The excision was performed in a single session under local anesthesia. The Gallium-Indium-Arsenide diode laser (Thera Laser Surgery, DMC Equipment's, São Carlos, SP, Brazil, 808 nm, 4W optical fiber, 400 μm in diameter with an area of 0.001 cm²) was used in continuous mode, with 3W power and energy of 792 J for four minutes and 24 seconds, with a power density of 3 W/cm². The 3 W was chosen due to the thermal effect and the ability to remove tissue, avoiding the thermal damage caused by the maximum power

of 4 W.^{10,11} Lower powers were not used because they would increase the surgical time. The optical fiber of the laser was inserted around the lesion in order to achieve complete excision of the impaired glands. Bleeding during the procedure was minimal and a suture was unnecessary (Figure 1B). Histopathological examination of the specimen showed a mucosal fragment covered with stratified parakeratinized squamous epithelium, areas of mucin extravasation, macrophages (foamy histiocytes), and a granulation tissue response (Figures 2A and 2B). A diagnosis of MGBN was made according to clinical, localization and microscopic characteristics.

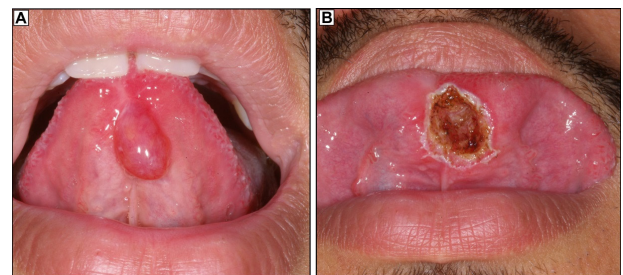


Figure 1. (A) Clinical aspect of mucocele of the Blandin-Nuhn glands - An oval-shaped swelling with non-ulcerated mucosa, smooth and bright surface, soft consistency, 3x6 mm in size was observed on the midline of the ventral surface of the tongue. (B) Immediate postoperative aspect of the mucocele of the Blandin-Nuhn glands after surgical excision with a diode laser. An ulcerated non-bleeding and non-sutured region is observed.

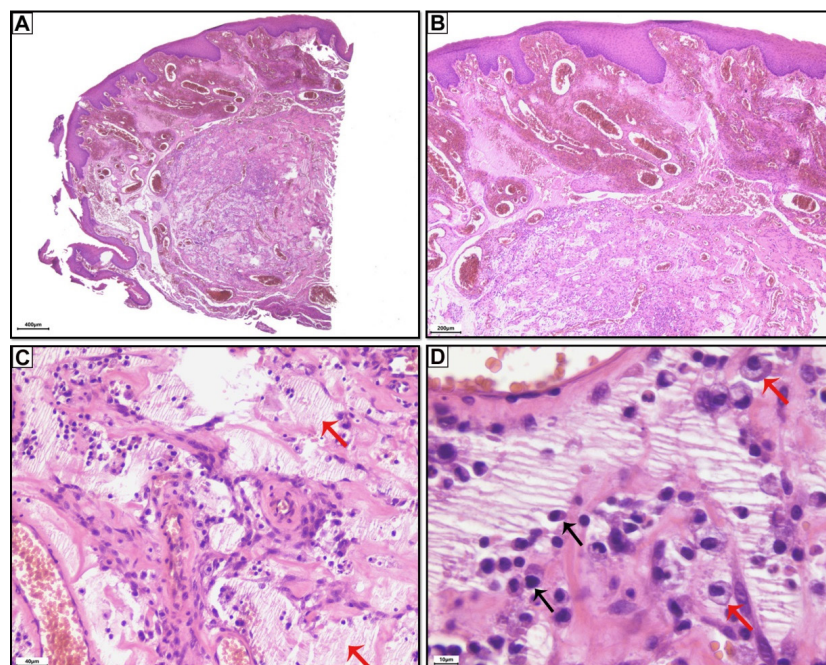


Figure 2. Histopathological Findings of Mucocele of the Glands of Blandin-Nuhn (Hematoxylin-eosin). (A) A fragment of the oral mucosa region of the mucocele (magnification 20x). (B) Parakeratinized squamous epithelium, dense connective tissue, cellularized and deep area of granulation tissue (40x). (C) Areas of mucin (red arrows) and inflammatory infiltrate (200x). (D) Foamy macrophages (red arrows) and lymphocytes (black arrows) (400x).

The patient was advised about care and oral hygiene of the surgical region. Analgesics were prescribed in case of postoperative pain. The patient reported the occurrence of minimal edema and mild pain symptoms only on the first postoperative day. Healing was assessed 15 and 30 days after the treatment and was complete on the 30th day (Figures 3A and 3B). No recurrence of MGBN was observed after two years of follow-up.

Discussion

MGBN is described as a relatively rare lesion, with only 2.5% of mucocele lesions occurring on the tongue in the region of the glands of Blandin-Nuhn.^{3,5,12} However, the low prevalence of MGBN may also be due to a neglected or inconclusive diagnosis and mainly due to the fact that mucocele in these glands has thin walls, suffering easy rupture.¹³ The glands of Blandin-Nuhn are mucous and serous salivary glands situated on both sides of the midline of the ventral tongue surface, embedded in the muscles of the ventral tongue, and covered with a thin layer of mucosa.⁴ In general, MGBN is a result of physical trauma.⁵ In addition to the natural exposure to trauma, surgeries performed in the region, such as a lingual frenectomy, can trigger the lesion.³ Congenital origin with the lesion disappearing spontaneously after 6 months has also been reported.¹⁴ In the current case, the previous surgical procedure may have triggered the lesion.

There are two main clinical aspects of MGBN; one clinical aspect is characterized by a slow-growth and asymptomatic submucosal lesion with a size ranging between 2 and 4 cm and located under the mucosal layer, similar to the lesion reported in the current case.⁵ The location of the Blandin-Nuhn glands embedded within the muscular structure of the lingual surface leads to the formation of mucocele lesions that require more invasive surgical excision with possible damage to other anatomical structures, especially blood vessels and other salivary glands. The high-intensity laser improves coagulation leading to the immediate hemostasis of the vessels. There is no need for the suture of tissues and the time of surgery

is reduced, providing comfort to the patient. The excision of mucocele with a high-intensity laser in other locations may last three to five minutes,⁹ as observed in our case. In addition, the high temperature of the optical fiber leads to the decontamination of the region, reducing the chances of possible postoperative infections.

The other clinical aspect involves a lesion that is more protuberant and painful and has a pedunculated base and a history of local trauma. The histopathological examination is important in order to confirm the diagnosis since MGBNs share similar clinical characteristics with vascular anomalies, pyogenic granuloma, fibrous hyperplasia and squamous papilloma, depending on the degree of vascularization and the atrophy of the acinus.¹ Other lesions such as lipoma or mucoepidermoid carcinoma¹² may also be clinically similar to MGBN.

Over the last three decades, alternative treatment techniques for MGBNs have been reported, such as steroid injections¹⁵ and cryosurgery.¹⁶ Injection of ethanol is also a possible treatment,⁶ but its side effects have not been evaluated yet. For conventional surgical excision, the lesion may be filled with flowable rubber base impression material before surgery to improve the visualization of the area during the surgical procedure¹⁷ or filled with alginate impression material, allowing the surgeon to have the lesion better delimited.¹⁸

Several reports have confirmed that mucoceles affecting the lower lip may be treated with different types of lasers, but it was only very recently that the use of diode lasers started to be indicated for MGBN.¹⁹ The carbon dioxide (CO₂), erbium and diode lasers were used as substitutes for the conventional surgical excision of mucoceles affecting the lip.⁷⁻⁹ Due to the deep location, conventional surgical excision may require invasive surgical management of the MGBN, resulting in postoperative complications such as edema and pain.^{1,5,13} In addition to low cost and portable characteristics, the diode laser has the advantage of causing less thermal damage to tissues because of the possibility of controlling the parameters during its use.⁹ Other advantages of the diode laser include minimal or no intraoperative bleeding, no need for suture, a time-saving procedure, and no scar formation with minimal postoperative discomfort and pain reported by patients.^{9,19} All of these advantages were observed in our case.

Conclusion

In conclusion, this case demonstrated the safe and effective management of MGBN with a high-intensity laser. No need for suture, minimal or no intraoperative bleeding, and a minimal report of pain and edema in the tongue region were observed. Thus, a diode laser may be a helpful tool for the treatment of MGBN because it is less invasive and because it is safe and effective.

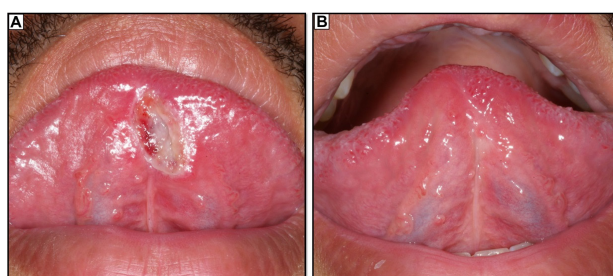


Figure 3. (A) Clinical aspect of healing 15 days after surgical excision with a diode laser. An ulcerated region with a yellowish background, non-bleeding and non-sutured is observed. (B) Total clinical healing is observed 30 days after surgical excision with a diode laser.

Ethical Considerations

Informed consent was obtained from the patient for the publication of this case report.

Conflict of Interest

The authors declare no conflict of interest.

References

- Joshi SR, Pendyala GS, Choudhari S, Kalburge J. Mucocele of the glands of blandin-nuhn in children: a clinical, histopathologic, and retrospective study. *N Am J Med Sci.* 2012;4(9):379-83. doi:10.4103/1947-2714.100977.
- Santos IKS, Matos JDM, Franco JMPL, Pereira NC, Vasconcelos JEL, Pita-Neto IC. Mucocele in Blandin-Nuhn Glands: Case Report and Integrative Review. *Int Arch Med.* 2017; 9(392). doi.org/10.3823/2263.
- Said M, Walby JA, Senders C, Aizenberg D. Mucocele of the Glands of Blandin-Nuhn, a rare complication following lingual frenectomy: Case report. *Int J Pediatr Otorhinolaryngol Case Report.* 2018;21:3-5. doi:10.1016/j.pedeo.2018.05.002.
- Sugerman PB, Savage NW, Young WG. Mucocele of the anterior lingual salivary glands (glands of Blandin and Nuhn): report of 5 cases. *Oral Surg Oral Med Oral Pathol Oral Radiol Endod.* 2000;90(4):478-482. doi:10.1067/moe.2000.108805.
- Adachi P, Soubhia AMP, Horikawa FK, Shinohara EH. Mucocele of the glands of Blandin-Nuhn--clinical, pathological, and therapeutical aspects. *Oral Maxillofac Surg.* 2011;15(1):11-13. doi:10.1007/s10006-010-0221-1.
- Zhang J, Wang C. The Application of Absolute Ethanol in the Treatment of Mucocele of the Glands of Blandin-Nuhn. *J Craniofac Surg.* 2016;27(7): e641e642. doi:10.1097/SCS.0000000000002993.
- Ramkumar S, Ramkumar L, Malathi N, Suganya R. Excision of mucocele using diode laser in lower lip. *Case Rep Dent.* 2016;2016:1746316. doi:10.1155/2016/1746316.
- Ahad A, Tandon S, Lamba AK, Faraz F, Anand P, Aleem A. Diode laser assisted excision and low level laser therapy in the management of mucus extravasation cysts: a case series. *J Lasers Med Sci.* 2017;8(3):155-159. doi:10.15171/jlms.2017.28.
- Bagher SM, Sulimany AM, Kaplan M, Loo CY. Treating mucocele in pediatric patients using a diode laser: three case reports. *Dent J (Basel).* 2018;6(2):13. doi: 10.3390/dj6020013.
- Amaral MBF, de A´vila JMS, Abreu MHG, Mesquita RA. Diode laser surgery versus scalpel surgery in the treatment of fibrous hyperplasia: a randomized clinical trial. *Int J Oral Maxillofac Surg.* 2015;44:1383–1389. doi: 10.1016/j.ijom.2015.05.015
- de Jesus AO, Matias MDP, de Arruda JAA, Aires AV, Gomes IP, Souza LN, et al. Diode laser surgery versus electrocautery in the treatment of inflammatory fibrous hyperplasia: a randomized double-blind clinical trial. *Clin Oral Investig.* 2020;24(12):4325-34. doi: 10.1007/s00784-020-03296-3
- Graillon N, Mage C, Le Roux MK, Scemama U, Chossegros C, Foletti JM. Mucoceles of the anterior ventral surface of the tongue and the glands of Blandin-Nuhn: 5 cases. *J Stomatol Oral Maxillofac Surg.* 2019;120:509-12. doi:10.1016/j.jormas.2019.04.005.
- Moraes PC, Bönecker M, Furuse C, Thomaz LA,Teixeira RG, Araújo VC. Mucocele of the gland of Blandin-Nuhn: histological and clinical findings. *Clin Oral Invest.* 2009;13(3):351-353. doi:10.1007/s00784-009-0252-x.
- Ochia A, Nakayama N. Congenital mucocele of the gland of Blandin-nuhn. *Oxf Med Case Reports.* 2015;12:374-375. doi:10.1093/omcr/omv066.
- Wilcox JW, History JE. Non-surgical resolution of mucoceles. *J Oral Surg.* 1978;36:478.
- Twetman S, Isaksson S. Cryosurgical treatment of mucocele in children. *Am J Dent.* 1990;3:175-6.
- Rai AJ, Hegde AM, Shetty YR. Management of Blandin-Nuhn mucocele—a case report. *J Clin Pediatr Dent.* 2007;32(2):147-9. doi:10.17796/jcpd.32.2.65n3364l14756107.
- Kumaresan R, Karthikeyan P, Mohammed F, Fairozekhan TA. A Novel Technique for the Management of Blandin-Nuhn Mucocele: A Case Report. *Int J Clin Pediatr Dent.* 2013;6(3):201-204. doi:10.5005/jp-journals-10005-1219.
- De Falco D, Di Venere D, Maiorano E. Diode Laser Excision of Blandin-Nuhn Mucocele. *Cureus.* 2020;12(3):e7441. doi:10.7759/cureus.7441.