

# Mast cell degranulation in periodontal disease from HIV-infected individuals

Giovanna Ribeiro Souto<sup>1</sup>, Alessandro Oliveira de Jesus<sup>2</sup>, Takeshi Kato Segundo<sup>3</sup>, Paôlla Freitas Perdigão<sup>4</sup>, Lucas Guimarães Abreu<sup>5</sup>, Fernando Oliveira Costa<sup>2</sup>, Ricardo Alves Mesquita<sup>2</sup>

<sup>1</sup> Department of Dentistry. Pontifical Catholic University of Minas Gerais, Belo Horizonte, Minas Gerais, Brazil. Hospital Público Regional de Betim. Betim, Minas Gerais, Brazil.

<sup>2</sup> Department of Oral Surgery and Pathology. School of Dentistry. Universidade Federal de Minas Gerais, Belo Horizonte, Minas Gerais, Brazil.


<sup>3</sup> Private clinic. Faculdade Arnaldo de Odontologia Belo Horizonte, Minas Gerais Brazil.

<sup>4</sup> D'OR Institute for Research and Education. Rio de Janeiro, Rio de Janeiro Brazil.

<sup>5</sup> Department of Paediatric Dentistry, School of Dentistry, Universidade Federal de Minas Gerais, Belo Horizonte, MG, Brazil.

**Conflicts of interest:** none

## Corresponding author:

Giovanna Ribeiro Souto  
Departamento de Odontologia –  
ICBS/PUC Minas Laboratório de  
Biologia Oral  
Rua Dom José Gaspar, 500 –  
Prédio 45 – sala 111  
Coração Eucarístico  
Belo Horizonte - MG, Brasil.  
30.535-610 Voice: +55-31-33194341  
E-mail: grsouto@hotmail.com  
 <https://orcid.org/0000-0003-3617-8794>

**Received:** November 12, 2018

**Accepted:** May 23, 2019

**Aim:** The objective was to compare the density and degranulation of mast cells on specimens obtained from individuals diagnosed with gingivitis or chronic periodontitis who were either non-HIV-infected or HIV-infected patients treated with highly active antiretroviral therapy (HAART).

**Methods:** Gingival samples were taken from 16 non-HIV-infected individuals and 17 HIV-infected individuals diagnosed with gingivitis and chronic periodontitis. The samples were processed and stained with 0.3 percent o-toluidine blue. Densities (cells/mm<sup>2</sup>) and percentages of intact and degranulated mast cells were obtained. **Results:** No statistically significant differences were observed in the mast cell density and the percentage of degranulated mast cells between non-HIV-infected and HIV-infected individuals diagnosed with gingivitis and chronic periodontitis. Mononuclear inflammatory infiltrate was weakly correlated with the percentage of mast cells degranulated for both groups. **Conclusions:** There are no differences of the density and degranulation of mast cells in gingival tissue between non-HIV-infected and HIV-infected patients undergoing HAART, both groups with diagnosis of gingivitis or chronic periodontitis. This may be a result of the recovery of the immunologic system by HAART treatment.

**Keywords:** Mast cells. Infection. Inflammation. Humans. Mouth mucosa.



## Introduction

Mast cells were first described in 1876 by Paul Ehrlich<sup>1</sup>. The key role of mast cells in the pathophysiology of different diseases such as atherosclerosis, autoimmune disorders, intestinal diseases, cancer, oral lichen planus and periodontal disease was demonstrated in experimental and clinical studies<sup>1-7</sup>. The function of mast cells was associated with the degranulation of cytotoxic mediators responsible for producing deleterious effects in different tissues<sup>8</sup>. In periodontal disease, mast cells seem to contribute with modulation of humoral and cellular response<sup>9,10</sup>. According to Steinsvoll et al.<sup>11</sup> (2004) evidence attributes to mast cells in natural immunity to bacteria a role in the local differentiation of monocytes into macrophages and dendritic cells. When mast cells are properly activated, the release of mast cells mediators in the tissue may be contributing to the maintenance of the periodontal disease<sup>12</sup>.

Degranulation of the granule-associated mediators is a result of mast cell activation. The granules of these inflammatory cells contain histamine, heparin, serotonin, chemotactic factors and various proteases such as peroxidase, tryptase, chymase, carboxidase and beta glucuronidase as primary mediators<sup>1,13</sup>. Marshall et al.<sup>14</sup> (2003) demonstrated that mast cells can be infected with several viruses, including the Human Immunodeficiency Virus (HIV), dengue virus, cytomegalovirus and adenovirus.

Bacterial plaque is the etiologic factor most important in inflammatory periodontal disease, and mast cells were found in high numbers in gingival samples taken from patients having chronic periodontitis in comparisons with controls<sup>2</sup>. Huang et al.<sup>7</sup> (2013) demonstrated a significant correlation between mast cell density, the degree of their degranulation, and human periodontitis severity. In the same context, an association between mast cells, HIV and periodontal disease also has been observed in patients undergoing treatment for HIV infection, but none had received highly active anti-retroviral therapy (HAART)<sup>15,16</sup>. Patients in all stages of HIV infection showed increased numbers of mast cells on gingival tissue with periodontal disease<sup>15</sup>. Furthermore, a significantly higher proportion of matrix metalloproteinases (MMP) expressed by mast cells was displayed in samples of HIV-infected individuals diagnosed with chronic periodontitis in comparisons with controls<sup>16</sup>. However, mast cell degranulation was not evaluated.

In a prior analysis of our research group<sup>17</sup>, the results did not demonstrate a statistically significant difference in the mast cell densities in HIV-infected individuals with periodontal disease undergoing HAART in comparison with non-HIV-infected individuals with periodontal disease. It was suggested that this fact may well be the result of the application of HAART in individuals with HIV<sup>17</sup>. Considering the importance of the mast cell in the immune response, it was evaluated the hypothesis of an alteration on the mast cell degranulation in gingival tissue of HIV-infected individuals. Therefore, this study compared the mast cell density and degranulation percentage between HIV-infected undergoing HAART and non-HIV-infected individuals diagnosed with gingivitis or chronic periodontitis. Also, the effect of mononuclear inflammatory infiltrate on mast cell degranulation was evaluated.

## Materials and methods

The present study was approved by the Research Ethics Committee from the Federal University of Minas Gerais (UFMG) under protocol number 514/07. All experiments were conducted in accordance with the Declaration of Helsinki.

### Clinical evaluation

Individuals with plaque-induced periodontal disease, classified as gingivitis or chronic periodontitis, were selected for the study<sup>18</sup>. Periodontal disease status was determined with the probing depth (PD), clinical attachment level (CAL), and gingival bleeding (GB). A full-mouth periodontal examination was performed by a single trained examiner (TKS) in four sites per tooth in all teeth, in a circumferential mode. The presence of four or more teeth with one or more sites containing PD  $\geq 4$  mm and CAL  $\geq 3$  mm within the same site constituted a diagnosis of chronic periodontitis<sup>19</sup>. Individuals who presented  $>25\%$  of sites with GB, and an absence of PD  $\geq 4$  mm and CAL  $\geq 3$  mm were diagnosed as having gingivitis<sup>19,20</sup>.

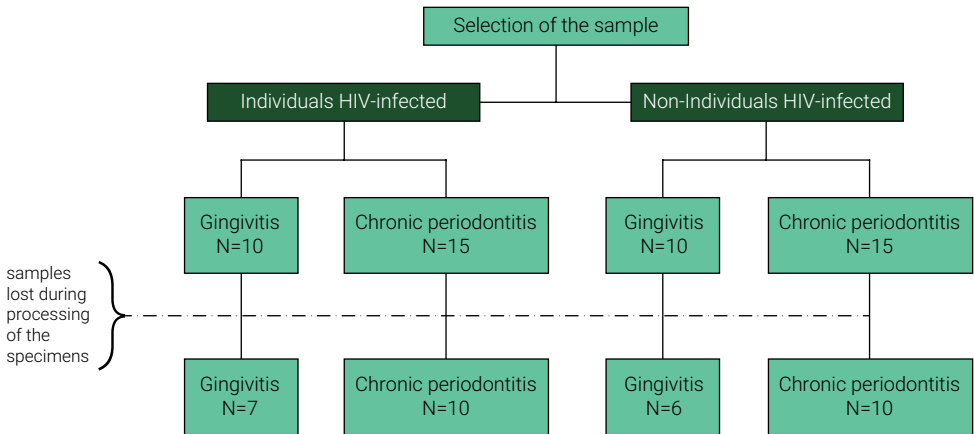
The patients ranged in age from 30 to 60 years old and included both men and women. The HIV-infected individuals were recruited from the Orestes Diniz Center (Belo Horizonte, Brazil) during a period of one year. HIV infection was determined by applying the Western-Blot test, and all positive patients had been undergoing HAART for a period of five to 13 years. The non-HIV-infected individuals were recruited from the Periodontology Clinic of the School of Dentistry and were sent to the Anonymous Test Center (Belo Horizonte, Brazil) to confirm their HIV-negative status.

CD4 and CD8 T-lymphocyte levels and viral loads were obtained from the medical records of the HIV-infected individuals up to two months prior to performing the biopsy of the gingival tissues.

### Procedures for tissue collection for both groups

1. Individuals diagnosed with gingivitis: For group diagnosed with gingivitis, gingival tissue samples were obtained from teeth with absence of PD  $\geq 4$  mm and CAL  $\geq 3$  mm removed for prosthetic or orthodontic reasons<sup>2</sup>.
2. Individuals with chronic periodontitis: For group diagnosed with chronic periodontitis, samples were obtained during the modified Widman surgery. These individuals were provided with oral hygiene instruction as well as sub-gingival scaling and root planning prior to surgery. After 45 to 60 days, for patients presenting with both PD  $> 5$  mm and bleeding on probing, modified Widman surgery was recommended. All gingival tissue samples were removed at sites with higher PD<sup>21</sup>.

Sample selection flowchart can be observed in the Fig. 1. The group diagnosed with gingivitis included seven samples from HIV-infected individuals and six samples from non-HIV-infected individuals. The group diagnosed with chronic periodontitis included 10 samples from HIV-infected individuals and 10 samples from non-HIV-infected individuals.



**Figure 1.** Sample selection flowchart

## Exclusion and inclusion criteria

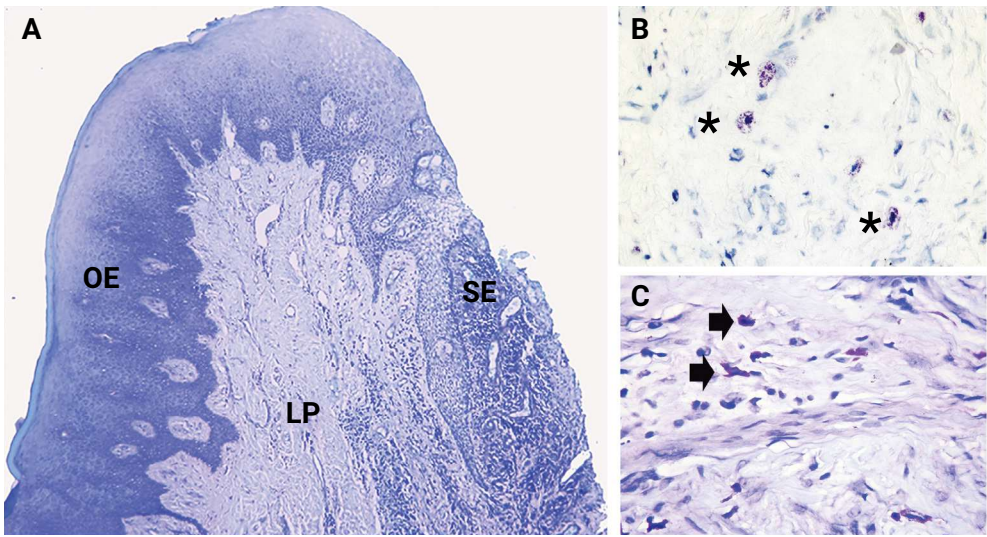
Individuals HIV-infected and non-HIV-infected diagnosed with gingivitis and chronic periodontitis were included in the study. Individuals from the non-HIV-infected group that reported systemic diseases or immunologic abnormalities were excluded. HIV-infected group that reported a non-controlled immunological system and the presence of others systemic diseases were also excluded from the study. The patients have not used any medication, except to HIV infection condition.

## Staining and grading

The specimens were fixed in 10 percent neutral-buffered formaldehyde solution. Sections stained with hematoxylin-eosin (H&E) were digitized using a microscope (Axioskop 2 Plus, Carl Zeiss, Göttingen, Germany) at 400X magnification, interfaced to a computer. Mononuclear inflammatory cell count was determined by a trained investigator (AOJ) using a software program (Image Tool, v.3.0, University of Texas Health Science Center, San Antonio, TX, USA), and the count was performed in eight to 10 consecutive fields.

Serial sections of 4  $\mu\text{m}$  from paraffin-embedded blocks were deparaffinized and dehydrated. Mast cells were detectable with o-toluidine blue 0.3 percent stain. The toluidine blue gave a light blue background to the section and allowed easy mapping of metachromatically-stained mast cells<sup>4</sup>. The degranulated mast cells were determined at a magnification of 100x under a light microscope (Axioskop 2 Plus, Carl Zeiss, Göttingen, Germany).

Mast cells were clearly identified by o-toluidine blue stain, and they presented in the lamina propria (LP) subjacent to the oral epithelium (OE) and sulcular epithelium (SE) in samples of the gingival tissue (Fig. 2A). Mast cell densities (per  $\text{mm}^2$ ) were calculated. Mast cells were counted only when the nucleus was clearly visible (Fig. 2B and C). According to Ghalayani et al.<sup>6</sup> (2012), the mast cells were categorized into two groups:



**Figure 2.** Gingival sample stained with o-toluidine blue. A) The oral (OE) and sulcular (SE) epithelium and lamina propria (LP) in gingival tissue sample were showed in toluidine blue stain (o-toluidine blue, original magnification 50x). B) Degranulated mast cells - it is observed less intense metachromasia and obvious clear outline of the nucleus (asterisk) (o-toluidine blue, 400x original magnification). C) Intacted mast cells- it is observed intense and dense metachromasia and nucleus not apparent (arrow) (o-toluidine blue, 400x original magnification).

1. Degranulated: less intense metachromasia or stainability and an obvious clear outline of the nucleus and/or free granules in close proximity to the cell membrane (Fig. 2B).
2. Intact: intense and dense metachromasia or stainability in which the nucleus was not apparent and/or no granule extrusion around the cell was present (Fig. 2C).

Mast cell degranulation was determined in the inflammatory infiltrate subjacent to the sulcular and oral gingival epithelium. All gingival specimens were evaluated, so eight to 10 fields were viewed via a microscope (Axioskop 2 Plus, Carl Zeiss, Göttingen, Germany) at 400X magnification using a meshwork eyepiece (0.1024 mm<sup>2</sup>). Mast cell densities and the percentage of mast cell degranulation were obtained, and the results were expressed as means and were compared.

The densities of degranulated mast cells [the cell number per millimeters squared (per mm<sup>2</sup>)] were correlated with the densities of mononuclear inflammatory infiltrate cells in HIV-infected and in non-HIV-infected individuals diagnosed with gingivitis or chronic periodontitis, because in this phase of the inflammation process, the mast cell has already released its granules.

## Statistical Analysis

The statistical analysis was performed using the software program (BioEstat, version 5.0, PA, Belém, Pará, Brazil). The sample distribution was tested using the Shapiro-Wilks procedure, and the samples presented a non-normal distribution; therefore, the Mann-Whitney Test and Spearman correlation were applied. The  $\alpha$  level was

set to 0.05. The correlation was graded according to the Cohen classification as weak ( $< 0.30$ ), moderate ( $0.30$  to  $0.50$ ), or strong ( $> 0.50$ )<sup>22</sup>. The reliability of the measurements was assessed by the intraclass correlation coefficient (ICC). An  $ICC > 0.91$  was considered to be a very good correlation;  $0.71 < ICC < 0.91$  was a good correlation;  $0.51 < ICC < 0.71$  was a moderate correlation;  $0.31 < ICC < 0.51$  was considered to be a bad correlation; and an  $ICC < 0.31$  was a very bad correlation<sup>23</sup>.

Sample size calculation was carried out with the Power and Sample Size Program (PS, version 3.0, Nashville, USA) and considered both type I and II errors. For this, we assumed a 95% confidence interval, 80% power of test and parameters of values of densities of mast cells obtained in study of periodontal disease of Huang et al.<sup>7</sup>

## Results

Data clinical and periodontal clinical parameters of the HIV-infected and non-HIV-infected individuals are presented in Table 1. There were no statistically significant differences in clinical periodontal parameters between the groups. Individuals who were HIV-infected presented a blood level of CD4 T cells/mm<sup>3</sup> of 521 (117-1,054) and 450 (28-815), and a blood level of CD8 T cells/mm<sup>3</sup> of 850 (267-1140) and 1,048 (406-1,565) for gingivitis or chronic periodontitis, respectively.

**Table 1.** Data clinical and periodontal clinical parameters of the HIV-infected and non-HIV-infected individuals.

Clinical Data	Gingivitis		Chronic periodontitis	
	HIV-infected (n = 7)	Non-HIV-infected (n = 6)	HIV-infected (n = 10)	Non-HIV-infected (n = 10)
Age (Years)*	38 (34 to 50)	38 (30 to 45)	46 (40 to 60)	42 (32 to 52)
Sex (n)				
Males	3	3	4	6
Females	4	3	6	4
GB (mean** $\pm$ SD)	0.94 $\pm$ 0.91	1.69 $\pm$ 0.83	1.05 $\pm$ 0.29	1.35 $\pm$ 0.65
PD > 4 mm (% of sites)	ND	ND	8.2	6.0
CAL > 3 mm (% of sites)	ND	ND	14.9	18.6

\* Median.

\*\*Mean

HIV= Human Immunodeficiency Virus (HIV); SD= standard deviation; GB= gingival bleeding; PD = probing depth; CAL= clinical attachment level; ND = not determined; Mann-Whitney test ( $P>0.05$ )

Cell counts were performed throughout the sections by two masked examiners at two different times, two weeks apart. The reliability of the measurements was assessed, and the ICC was 0.85. Statistically significant differences were not observed in the mast cell density between HIV-infected and non-HIV-infected individuals diagnosed with gingivitis ( $P=0.43$ ) or chronic periodontitis ( $P=0.76$ ). In addition, there were no statistically significant differences in degranulation of the mast cells between HIV-infected and non-HIV-infected individuals diagnosed with gingivitis ( $P=0.18$ ) or

chronic periodontitis ( $P=0.20$ ) (Table 2). It was observed that the densities of the mononuclear inflammatory infiltrate were weakly correlated with the density of mast cell degranulation for both groups—HIV-infected and non-HIV-infected with gingivitis ( $P=0.21$ ) or chronic periodontitis ( $P=0.87$ ).

**Table 2.** Mast cell densities and degranulation in gingival samples of individuals presenting with gingivitis or chronic periodontitis.

	Gingivitis		Chronic periodontitis	
	HIV-infected (n = 7)	Non-HIV-infected (n = 6)	HIV-infected (n = 10)	Non-HIV-infected (n = 10)
Mean $\pm$ SD of mast cell densities (cell/mm <sup>2</sup> )	46.19 $\pm$ 47.64	53.80 $\pm$ 52.35	48.21 $\pm$ 51.68	51.78 $\pm$ 48.32
Mast cell degranulation (%)	52.74	62.54	52.88	47.11

HIV= Human Immunodeficiency Virus (HIV); SD= standard deviation; Mann-Whitney test ( $P>0.05$ )

## Discussion

In human periodontal disease, there is an increase in the number of mast cells that may be participating either in the destructive events or in the defense mechanism of periodontal disease via secretion of cytokines<sup>2</sup>. It was suggested that HIV infection may increase or be associated with an augmented mast cell count in the cervixes of women, even without treatment information<sup>8</sup>. In addition, some authors think that mast cells represent a potential reservoir for infectious HIV-1<sup>24,25</sup>. However, in the present study, statistically significant differences were not observed in the mast cell density and degranulation percentage between HIV-infected individuals undergoing HAART and non-HIV infected individuals diagnosed with gingivitis or chronic periodontitis.

The mast cells degranulation represents their functional status<sup>26</sup>. This occur in response to various stimuli including chemicals, drugs, allergen-bound immunoglobulin-E (IgE) or to non-immunological stimuli, as well as in response to bacterial products or cytokines<sup>26,27</sup>. Huang et al.<sup>7</sup> (2013) showed strong mast cell degranulation in both the moderate and advanced periodontitis groups, suggesting that periodontal mast cell accumulation and degranulation may play a central role in the pathogenesis of human periodontal disease. To date, the role of mast cells degranulation in periodontal disease from HIV-infected individuals it was not evaluated. In the present study, mast cells were clearly identified by o-toluidine blue stain. The evaluation of mast cell activation by degranulation using o-toluidine blue stain was considered to be a reliable method in comparison with immunohistochemical reaction<sup>7</sup>.

Histological analysis performed by Huang et al.<sup>7</sup> (2013) demonstrated that inflammatory infiltrate present in chronic periodontitis samples is significantly increased in comparison to clinically healthy gingival tissues. This infiltrate is composed by predominantly mononuclear cells and focally distributed with large presence of lymphocytes and plasma cells, as well as a discrete presence of macrophage-like cells and foci of polymorphonuclear cells<sup>7</sup>. In the current study, inflammatory infiltrate density

was not significantly correlated to mast cell density and degranulation. These results contrast with the significant correlation demonstrated between inflammatory infiltrate and dendritic cells densities<sup>28</sup>. Therefore, it is possible that the mast cells recruitment and activation in periodontal disease is more related to secretion of inflammatory cytokines and chemokines by inflammatory infiltrate cells than number of this cells.

The clinical examiner was a specialist in periodontics with more than 10 years of experience and therefore we considered that the clinical parameters used in the study were reliable. However, the absence of intra-examiner calibration may be a limitation of the study. In addition, the absence of mean and standard deviation of PD and CAL of teeth whose gingival tissues were obtained was also a limitation of the present study. The severity of the disease could impact the analysis performed in this study. However, we considered no significant variation was found in this parameters, since the gingival tissues were obtained from teeth with of PD <4 mm and CAL <3 mm for gingivitis group, and sites with higher PD for chronic periodontitis group.

Studies performed before the introduction of HAART presented an accelerated progression of periodontitis existing previously<sup>29</sup>. With HAART, studies have demonstrated a decrease in the oral manifestations of Kaposi's sarcoma, oral candidiasis, and hairy leukoplakia in HIV-infected patients<sup>30</sup>. However, in these studies, the findings are not clear about periodontal disease, mainly due to the lack of consistent criteria to define disease. It has been difficult to determine the true prevalence of the periodontal disease in patients with HIV-infection<sup>30-32</sup>. A study of the frequency of oral lesions in HIV-positive patients undergoing HAART, compared with a non-HIV-infected control group, showed that periodontal diseases were the second most frequent oral lesions (25 percent) found in these patients<sup>33</sup>. In contrast with Peppes et al.<sup>33</sup> (2013), Gonçalves et al.<sup>30</sup> (2013) showed no statistically significant differences in the prevalence of oral manifestations, including periodontal disease, between patients who were HIV-positive and undergoing HAART, in comparison with those not on HAART.

Recently, to assess the prevalence and severity of chronic periodontitis in patients with HIV-infection, Groenewegen et al.<sup>34</sup> (2019) compared 258 patients with HIV-infection and undergoing HAART with 539 controls and observed severe chronic periodontitis more prevalent in infected patients (66%) than in controls (36%). In the present study, the samples had no significant differences in the severity of periodontal disease. This could be a possible explanation for similar recruitment and activation of mast cells observed between groups.

However, cytokines and other inflammatory mediators expressed by mast cells from gingival samples could explain the role of these cells in the periodontal disease of patients with HIV-infection. A potential function in HIV-1 dissemination was demonstrated for gut mucosal mast cells. They expressed a variety of HIV-1 attachment factors (HAFs) and mast cell surface-bound viruses were efficiently transferred to target T cells. Strategies futures to prevent viral capture and transfer mediated by mast cells could be beneficial in combating primary HIV-1 infection<sup>35</sup>.

The present study concluded that HIV-infected individuals undergoing HAART did not present differences in mast cell density and degranulation in comparison with

non-HIV-infected. This mast cell accumulation and degranulation similar may be a result of the recovery of the immunologic system by HAART treatment. From the clinical point of view, this could explain because, in the last years, the progression of periodontal disease has been shown similar between the HIV-infected and non-HIV-infected groups.

## Acknowledgments:

The authors would like to thank the National Council for Scientific and Technological Development (CNPq), Brasília, DF, Brazil (grant numbers 309322/2015-4).

---

## Reference

1. Anand P, Singh B, Jaggi AS, Singh N. Mast cells: an expanding pathophysiological role from allergy to other disorders. *Naunyn Schmiedebergs Arch Pharmacol*. 2012 Jul;385(7):657-70. doi: 10.1007/s00210-012-0757-8.
2. Batista AC, Rodini CO, Lara VS. Quantification of mast cells in different stages of human periodontal disease. *Oral Dis*. 2005 Jul;11(4):249-54.
3. Juneja M, Mahajan S, Rao NN, George T, Boaz K. Histochemical analysis of pathological alterations in oral lichen planus and oral lichenoid lesions. *J Oral Sci*. 2006 Dec;48(4):185-93.
4. Rao KN, Brown MA. Mast cells: multifaceted immune cells with diverse roles in health and disease. *Ann N Y Acad Sci*. 2008 Nov;1143:83-104. doi: 10.1196/annals.1443.023.
5. Sharma R, Sircar K, Singh S, Rastogi V. Role of mast cells in pathogenesis of oral lichen planus. *J Oral Maxillofac Pathol*. 2011 Sep;15(3):267-71. doi: 10.4103/0973-029X.86674.
6. Ghalayani P, Jahanshahi G, Saberi Z. Degranulated mast cells and TNF- $\alpha$  in oral lichen planus and oral lichenoid reactions diseases. *Adv Biomed Res*. 2012;1:52. doi: 10.4103/2277-9175.100161.
7. Huang S, Lu F, Chen Y, Huang B, Liu M. Mast cell degranulation in human periodontitis. *J Periodontol*. 2013 Feb;84(2):248-55. doi: 10.1902/jop.2012.120066.
8. Guimarães JV, Costa FB, Andrade WM, Vêncio EF, Salge AK, Siqueira KM, et al. Quantification of mast cells in the uterine cervix of women infected with human immunodeficiency virus. *Ann Diagn Pathol*. 2011 Oct;15(5):318-22. doi: 10.1016/j.anndiagpath.2011.02.009.
9. Welle M. Development, significance, and heterogeneity of mast cells with particular regard to the mast cell-specific proteases chymase and tryptase. *J Leukoc Biol*. 1997 Mar;61(3):233-45.
10. Villa I, Skokos D, Tkaczyk C, Peronet R, David B, Huerre M, et al. Capacity of mouse mast cells to prime T cells and to induce specific antibody responses in vivo *Immunology*. 2001 Feb;102(2):165-72.
11. Steinsvoll S, Helgeland K, Schenck K. Mast cells—a role in periodontal diseases? *J Clin Periodontol*. 2004 Jun;31(6):413-9.
12. Forsythe P, Befus AD. Inhibition of calpain is a component of nitric oxide-induced down-regulation of human mast cell adhesion. *J Immunol*. 2003 Jan 1;170(1):287-93.
13. Schwartz LB, Austen KF. Enzymes of the mast cell granule. *J Invest Dermatol*. 1980 May;74(5):349-53.
14. Marshall JS, King CA, McCurdy JD. Mast cell cytokine and chemokine responses to bacterial and viral infection. *Curr Pharm Des*. 2003;9(1):11-24.

15. Myint M, Steinsvoll S, Yuan ZN, Johne B, Helgeland K, Schenck K. Highly increased numbers of leukocytes in inflamed gingiva from patients with HIV infection. *AIDS*. 2002 Jan 25;16(2):235-43.
16. Naesse EP, Schreurs O, Helgeland K, Schenck K, Steinsvoll S. Matrix metalloproteinases and their inhibitors in gingival mast cells in persons with and without human immunodeficiency virus infection. *J Periodontol Res*. 2003 Dec;38(6):575-82.
17. Segundo TK, Souto GR, Costa FO, Mesquita RA. Mast cells in periodontal disease of individuals with and without HIV undergoing highly active antiretroviral therapy. *J Periodontol*. 2013 Jul;84(7):995-1001. doi: 10.1902/jop.2012.120436.
18. Armitage GC. Periodontal diagnoses and classification of periodontal diseases. *Periodontol* 2000. 2004;34:9-21.
19. López NJ, Smith PC, Gutierrez J. Periodontal therapy may reduce the risk of preterm low birth weight in women with periodontal disease: a randomized controlled trial. *J Periodontol*. 2002 Aug;73(8):911-24.
20. López NJ, Da Silva I, Ipinza J, Gutiérrez J. Periodontal therapy reduces the rate of preterm low birth weight in women with pregnancy-associated gingivitis. *J Periodontol*. 2005 Nov;76 Suppl 11S:2144-2153. doi: 10.1902/jop.2005.76.11-S.2144.
21. Salvi GE, Lindhe J, Lang NP. Plano de tratamento de pacientes com doenças periodontais. 5<sup>th</sup> ed. Rio de Janeiro: Guanabara Koogan; 2008.p. 629.
22. Cohen J. Statistical power analysis for the behavioral sciences. 2<sup>nd</sup> ed. Hillsdale, NJ: Lawrence Erlbaum Associates; 1988. p. 40-151.
23. Bressenot A, Salleron J, Bastien C, Danese S, Boulagnon-Rombi C, Peyrin-Biroulet L. Comparing histological activity indexes in UC. *Gut*. 2015 Sep;64(9):1412-8. doi: 10.1136/gutjnl-2014-307477.
24. Crowe S, Zhu T, Muller WA. The contribution of monocyte infection and trafficking to viral persistence, and maintenance of the viral reservoir in HIV infection. *J Leukoc Biol*. 2003 Nov;74(5):635-41.
25. Sundstrom JB, Little DM, Villinger F, Ellis JE, Ansari AA. Signaling through Toll-like receptors triggers HIV-1 replication in latently infected mast cells. *J Immunol*. 2004 Apr 1;172(7):4391-401.
26. Maurer M, Theoharides T, Granstein RD, Bischoff SC, Bienenstock J, Henz B, et al. What is the physiological function of mast cells? *Exp Dermatol*. 2003 Dec;12(6):886-910.
27. Caughey GH. Mast cell tryptases and chymases in inflammation and host defense. *Immunol Rev*. 2007 Jun;217:141-54.
28. Souto GR, Queiroz-Junior CM, de Abreu MH, Costa FO, Mesquita RA. Pro-inflammatory, Th1, Th2, Th17 cytokines and dendritic cells: a cross-sectional study in chronic periodontitis. *PLoS One*. 2014 Mar 26;9(3):e91636. doi: 10.1371/journal.pone.0091636. eCollection 2014.
29. Lamster IB, Grbic JT, Bucklan RS, Mitchell-Lewis D, Reynolds HS, Zambon JJ. Epidemiology and diagnosis of HIV-associated periodontal diseases. *Oral Dis*. 1997 May;3 Suppl 1:S141-8.
30. Gonçalves LS, Gonçalves BM, Fontes TV. Periodontal disease in HIV-infected adults in the HAART era: Clinical, immunological, and microbiological aspects. *Arch Oral Biol*. 2013 Oct;58(10):1385-96. doi: 10.1016/j.archoralbio.2013.05.002.
31. Mataftsi M, Skoura L, Sakellari D. HIV infection and periodontal diseases: an overview of the post-HAART era. *Oral Dis*. 2011 Jan;17(1):13-25. doi: 10.1111/j.1601-0825.2010.01727.x.
32. Ryder MI, Nittayananta W, Coogan M, Greenspan D, Greenspan JS. Periodontal disease in HIV/AIDS. *Periodontol* 2000. 2012 Oct;60(1):78-97. doi: 10.1111/j.1600-0757.2012.00445.x.
33. Peppes CP, Lemos ASP, Araujo RLF, Portugal MEG, Buffon MCM, Raboni SM. Oral lesions frequency in HIV-positive patients at a tertiary hospital, Southern Brazil. *Bra J of Oral Sci*. 2013;12(3):216-22. doi: 10.1590/S1677-32252013000300012.

34. Groenewegen H, Bierman WFW, Delli K, Dijkstra PU, Nesse W, Vissink A, et al. Severe periodontitis is more common in HIV- infected patients. *J Infect.* 2019 Mar;78(3):171-177. doi: 10.1016/j.jinf.2018.11.008.
35. Jiang AP, Jiang JF, Wei JF, Guo MG, Qin Y, Guo QQ, et al. Human Mucosal Mast Cells Capture HIV-1 and Mediate Viral trans-Infection of CD4+ T Cells. *J Virol.* 2015 Dec 30;90(6):2928-37. doi: 10.1128/JVI.03008-15.