

Immunohistochemical Evaluation of the Hedgehog Route as a Potential Prognostic Factor in Hepatocellular Carcinoma

Avaliação imuno-histoquímica da rota Hedgehog como potencial fator prognóstico no carcinoma hepatocelular

João Paulo Imperes Lira¹; Jesus Junior Faria Rosa¹; Ronniel Morais Albuquerque¹; Thiago Almeida Pereira²; Paula Vieira Teixeira Vidigal¹

¹ Department of Pathology, Faculty of Medicine, Federal University of Minas Gerais, MG, Brazil.

² Stanford University Medical School, Institute for Stem Cell Biology and Regenerative Medicine, Brazil.

ABSTRACT

Introduction: Hepatocellular carcinoma (HCC) is the most common primary malignant neoplasm in the liver. HCC develops gradually from multiple stages that control proliferation and apoptosis. In hepatocarcinogenesis, multiple signaling pathways were already described, such as the Hedgehog pathway (Hh). However, few studies have investigated the expression of Hh proteins as a potential prognostic factor in human HCC. This study aimed to investigate the expression of the Shh protein in HCC and to correlate with clinical and morphological prognostic characteristics of the tumor.

Methods: Immunohistochemical expression of Shh protein in tumor and cirrhotic parenchyma was performed in 36 HCC samples from patients who underwent liver transplantation at Clinical Hospital - UFMG. Correlation between the Shh tumor expression and etiology, number of nodules, size of the nodules, levels of alpha-fetus-protein (AFP), MELD score, tumor differentiation, and vascular invasion were performed.

Results: In our study, Shh protein labeling gradually increased from the normal to the cirrhotic and neoplastic parenchyma. Degree of tumor differentiation and vascular invasion were correlated with high Shh protein expression ($p = 0.014$ and $p = 0.003$, respectively). The other variables did not show a statistically significant correlation with Shh labeling.

Conclusion: Hedgehog pathway has importance in hepatocarcinogenesis. The immunohistochemical study of the Hh signaling pathway may have a promising role as a prognostic factor for HCC, especially due to the positive correlation between the Shh expression and the degree of tumor differentiation and invasion vascular.

Key words: carcinoma; hepatocellular; prognosis; hedgehog Proteins; immunohistochemistry.

RESUMO

Introdução: O carcinoma hepatocelular (CHC) é a neoplasia maligna primária mais comum no fígado. O CHC se desenvolve gradualmente a partir de múltiplos estágios que controlam a proliferação e a apoptose. Na hepatocarcinogênese, múltiplas vias de sinalização já foram descritas, como a via Hedgehog (Hh). No entanto, poucos estudos investigaram a expressão de proteínas Hh como um potencial fator prognóstico no CHC humano. Este estudo teve como objetivo investigar a expressão da proteína Shh no CHC e correlacionar com características prognósticas clínicas e morfológicas do tumor.

Métodos: A expressão imuno-histoquímica da proteína Sbb em tumor e parênquima cirrótico foi realizada em 36 amostras de CHC de pacientes submetidos a transplante hepático no Hospital das Clínicas - UFMG. Correlação entre a expressão e etiologia do tumor Sbb, número de nódulos, tamanho dos nódulos, níveis de proteína alfa-feto (AFP), pontuação MELD, diferenciação tumoral e invasão vascular foram realizadas.

Resultados: Em nosso estudo, a marcação da proteína Sbb aumentou gradualmente do parênquima normal para o cirrótico e neoplásico. Grau de diferenciação tumoral e invasão vascular foram correlacionados com alta expressão da proteína Sbb ($p = 0,014$ e $p = 0,003$, respectivamente). As demais variáveis não apresentaram correlação estatisticamente significativa com a marcação de Sbb.

Conclusão: A via Hedgehog tem importância na hepatocarcinogênese. O estudo imuno-histoquímico da via de sinalização Hh pode ter um papel promissor como fator prognóstico para CHC, principalmente devido à correlação positiva entre a expressão de Sbb e o grau de diferenciação tumoral e invasão vascular.

Palavras-chave: carcinoma; hepatocelular; prognóstico; proteínas de ouriço; imuno-histoquímica.

INTRODUCTION

Hepatocellular Carcinoma (HCC) is the most common primary malignancy in the liver. According to estimates of the World Health Organization (WHO), in 2018, HCCs were responsible for 4.7% of new cancer cases globally, with a mortality rate of 8.2% [1]. Its primary etiology still resides in chronic viral infections by hepatitis B and hepatitis C viruses (HBV and HCV, respectively), responsible for approximately 85% of the cases. However, the importance of other etiologies is emerging, as non-alcoholic steatohepatitis (NASH) [2]. In general, the most significant risk factor for developing this neoplasia is the presence of liver cirrhosis [3].

HCC develops slowly and gradually from multiple stages that control proliferation and apoptosis [4,5]. In the face of a still poorly understood etiopathogenesis, signaling pathways related to hepatocarcinogenesis have been the subject of ongoing studies [6]. Multiple signaling pathways that regulate cell proliferation, angiogenesis, and vascular invasion may be altered in HCC. We can highlight the Hedgehog (Hh) signaling pathway, which is activated in several neoplasms [7].

The activation of the Hh pathway is initiated by connecting one of the Hedgehog ligands (Sonic hedgehog (Shh), Indian hedgehog (Ihh), and Desert hedgehog (Dhh)) to the Patched transmembrane receptor (PTCH). The PTCH receptor, when not stimulated, acts as a tumor suppressor, inhibiting the Smoothed proto-oncoprotein (SMO). After binding the stimulating factor, SMO is released and migrates to the nucleus, activating cell proliferation genes, such as the oncogene-1 associated with the

glioma (GLI1) [8]. The Hedgehog pathway is exposed to several forms of regulation, such as the proteins Gli3 (GPC3) and Hedgehog Interacting Protein (Hhip), important negative regulators [9,10].

In the healthy adult liver, the Hh pathway is quiescent due to the low production of its stimulating ligands (Shh, Ihh, and Dhh) and the high expression of its negative regulators (Hhip) [11]. However, in acute or chronic liver injury, several cell types in the parenchyma start to produce Shh and/or Ihh ligands [12]. In addition, there is a reduction in the expression of negative regulators [13]. Thus, this imbalance between stimulating and inhibitory factors creates a microenvironment for proliferation and differentiation gene transcription.

Huang et al. demonstrated elevated levels of Shh protein in HCC neoplasia samples [14]. Chan et al. showed that, in addition to stimulation of proliferative pathways, hyperexpression of Shh protein could induce glycolysis, increasing the production of ATP and lactate, which can be used as an energy source for tumor growth [15]. In animal models of HCC, increased protein expression of Shh has already been demonstrated through immunohistochemical markers [16].

In the scientific literature, studies indicate that the Hh pathway plays a fundamental role in the development and capacity of vascular invasion of HCC [17]. However, the clinical importance of Hh pathway activation in patients with HCC is still unclear. The hyperactivity of Shh has been associated with poor prognosis in prostate, colorectal and pancreatic cancer [18-20]. In animal models, there was a direct association between the level of Shh protein labeling and the degree of tumor

differentiation [16], a prognostic factor in HCC. However, few studies have investigated the relationship between the expression of proteins in the Shh pathway as a potential prognostic factor in human HCC.

This study aimed to investigate the expression of the Shh signaling protein in surgical specimens with HCC of patients who underwent liver transplantation and correlate Shh expression with the clinical and morphological prognostic characteristics of the tumor [21]: tumor differentiation, presence of vascular invasion, level of alpha-fetoprotein, MELD score, etiology of the tumor, number of nodules and size of the nodule.

MATERIAL AND METHODS

A total of 36 samples were obtained from surgical specimens from liver transplantation performed at the *Alfa Institute of Gastroenterology of Hospital das Clínicas* (HC) of the Federal University of Minas Gerais (UFMG) between the years 2003 and 2015 were evaluated. In addition, the archived slides were reviewed to choose the most representative blocks of hepatocellular carcinoma. The study was approved by the UFMG Research Ethics Committee on 9/20/2017, under the registration number CAAE: 71206617.8.0000.5149.

All cases analyzed in this study had their medical records reviewed to correlate immunohistochemical findings with clinical, laboratory, and morphological data. In addition, data on the latest laboratory profile, etiology of the tumors, and the morphological characteristics of the lesion were collected. The MELD score (model for end-stage liver disease) was retrospectively recalculated from data of serum creatinine, total serum bilirubin, and International Normalized Ratio (INR), disregarding the additional score received in the case of a clinically detected HCC patient.

The most representative histological slides of each case were selected. Samples of hepatocellular carcinoma were submitted to immunohistochemistry using the anti-Shh antibody (EPITOMICS 1843-1) at a concentration of 1:1000. Two pathologists determined the degree of immunoreactivity semi-quantitatively based on the percentage of positive cytoplasmic cells per field and the intensity of the cytoplasmic staining under light microscopy (H-score), as established in the literature [22]. The final positivity H-score was classified as absent, weak, moderate, and strong. The pathologist's evaluation was independent, and an agreement test was not performed for this study.

Statistical analysis was performed using the Minitab program, version 18.9.1. The correlation of the data was performed

using the chi-square association test. Values of $p < 0.05$ were considered statistically significant. The odds ratio (Odds Ratio) was calculated for data with statistical significance to quantify this association.

RESULTS

Clinical and morphological data: All 36 HCC cases in the present study were obtained from cirrhotic liver, with 16 (44.4%) having alcoholic hepatitis as the underlying disease, 14 cases (38.9%) of chronic hepatitis C, and 6 cases (16.7%) of cryptogenic cirrhosis. Regarding laboratory data, the serum alpha-fetoprotein (AFP) level was identified in only 23 cases, with a median of 5.5 ng/mL. The recalculated MELD score values were obtained for 28 of the 36 patients. The median MELD of the cases analyzed was 15 points. Table 1 shows the clinical and laboratory data of the patients studied.

TABLE 1 - Distribution of Etiology of cirrhosis and laboratory data on patients undergoing liver transplantation at HC-UFMG between 2003 and 2015

Etiology of cirrhosis and laboratory data	Distribution
Etiology	n (%)
Ethanol	16 (44.4)
HCV	14 (38.9)
Cryptogenic	6 (16.7)
Laboratory data:	Median (min-max)
ALT (U / L)	48.0 (11.0 - 275.0)
AST (U / L)	53.0 (20.6 - 177.0)
BT (mg / dL)	2.15 (0.6 - 8.7)
RNI	1.49 (0.99 - 2.51)
Creatinine (mg / dL)	0.89 (0.4 - 3.0)
AFP (ng / ml) *	n (%)
<10	17 (73.9)
> 10	6 (26.1)
MELD **	n (%)
<20	22 (78.6)
> 20	6 (21.4)

Source: Authors. * n=23 cases. ** n=28 cases.

HCV: Hepatitis C virus; ALT: Alanine transaminase; AST: Aspartate transaminase; BT: Total bilirubin; RNI: International normalized ratio; AFP: alpha-fetoprotein; MELD: Model of end-stage liver disease.

The number of nodules found in the tissue specimens varied from 1 to 10 per patient, with a median of 2. About the size of the nodules, there was a variation of 1.0 to 5.2 cm, with 2.75 cm being the median. Regarding the degree of tumor differentiation, 27 (75%) cases were classified as low grade (8 grade I and 19 grade II), and 9 cases (25%) were classified as high grade (7 grade III and 2 grade IV). HE detected a vascular invasion in 12 (33.3%) cases, being absent in 24 (66.7%) cases. Table 2 summarizes the morphological data of the patients studied.

TABLE 2 - Morphological analysis of 36 cases of HCC from liver transplantation performed at HC-UFGM in the period between 2003 and 2015

Morphological analysis of HCC	n (%)
Number of Nodes	
Single	18 (50)
Multiples	18 (50)
Node size	
> 2.0 cm	29 (80.6)
<2.0 cm	7 (19.4)
Vascular invasion	
Present	12 (33.3)
Absent	24 (66.7)
Degree of differentiation*	
Low grade (I / II)	27 (75)
High grade (III / IV)	9 (25)

Source: Authors. *According to the Edmonson -Steiner score.
HCC: Hepatocellular Carcinoma

Immunohistochemistry Analysis: In our study, we found the following pattern of immunohistochemical staining: none of the normal hepatocytes showed Shh protein labeling; in peritumoral cirrhotic parenchyma, we found 17 weak and three moderate Shh protein labeling; and in HCC tumor parenchyma, we found eight weak, ten moderate and two intense Shh protein labeling. Absent/weak staining was predominant in the cirrhotic parenchyma, and the neoplastic parenchyma showed more moderate/strong marking. Figure 1(a) shows an example of cytoplasmic labeling for the Shh protein in normal liver, and Figure 1(b) illustrates cirrhotic and tumor Shh expression by immunohistochemistry.

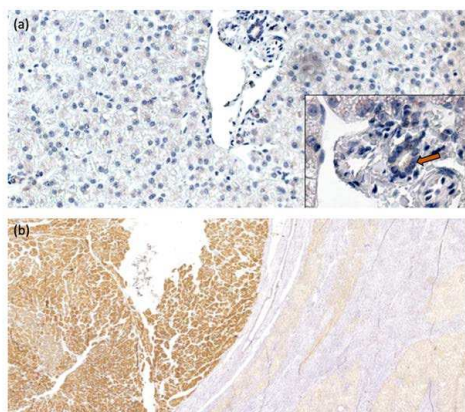


FIGURE 1 – Shh immunoeexpression in (a) normal liver, Shh protein is only marked in cholangiocytes (arrow), 200x and 600x magnification; (b) tumoral area (left, strong marking) with pseudoacinar architecture and adjacent cirrhotic nodules (right, moderate marking), 40x magnification.

The statistical analysis allowed us to establish that the proportions of the Shh protein labeling are not homogeneous, with moderate/strong labeling being more associated with the tumor tissue (p = 0.009), as shown in Table 3.

TABLE 3 - Correlation between the immunohistochemical score of Shh protein in the cirrhotic and tumor parenchyma in HCC from liver transplantation performed at HC-UFGM in the period between 2003 and 2015

Shh Immunohistochemical score	Parenchyma		P
	Cirrhotic n (%)	Tumor n (%)	
Absent / Weak	33 (91.7)	24 (66.7)	0.009
Moderate / Strong	3 (8.3)	12 (33.3)	

Source: Authors.
HCC: Hepatocellular Carcinoma

Correlation between immunohistochemical scores and clinical/morphological data: The main point of our study was to evaluate the correlation between Shh protein expression and the clinical, laboratory, and morphological markers for HCC. Regarding the serum levels of alpha-fetoprotein, there was no correlation between serum levels greater than or less than ten ng/ml and the expression of Shh in the tumor (p = 0.526). No correlation was verified between Shh expression in tumor samples and a MELD score greater than or less than 20 (p = 0.291). There was no significant correlation between Shh protein expression and the parameters of etiology (p = 0.227), number of nodules (p = 0.157), and size of the nodules (p = 0.551), as shown in Table 4.

TABLE 4 - Correlation between the Shh protein immunohistochemical score in the tumor parenchyma and Etiology, Number of nodules, Size of the nodules, Levels of alpha-fetus-protein (AFP), and MELD score in HCC from liver transplant performed at HC-UFGM in the period between 2003 and 2015

Variables	Shh Immunohistochemical score		P
	Absent / Weak n (%)	Moderate / Strong n (%)	
Etiology			0.227
Viral	11 (30, 6)	3 (8.3)	
Non-Viral	13 (36.1)	9 (25)	
Number of nodules			0.157
Single	14 (38.9)	4 (11.1)	
Multiples	10 (27.8)	8 (22.2)	
Node Size			0.551
<2.0 cm	4 (11.1)	3 (8.3)	
> 2.0 cm	20 (55, 6)	9 (25)	
AFP level *			0.526
<10 mg / dL	11 (48)	6 (26)	
> 10 mg / dL	3 (13)	3 (13)	
MELD score **			0.291
<20	16 (57.1)	6 (21.4)	
> 20	3 (10.75)	3 (10.75)	

Source: Authors. * n = 23 cases. ** n = 28 cases.
HCC: Hepatocellular Carcinoma; AFP: alpha-fetoprotein; MELD: Model of end-stage liver disease.

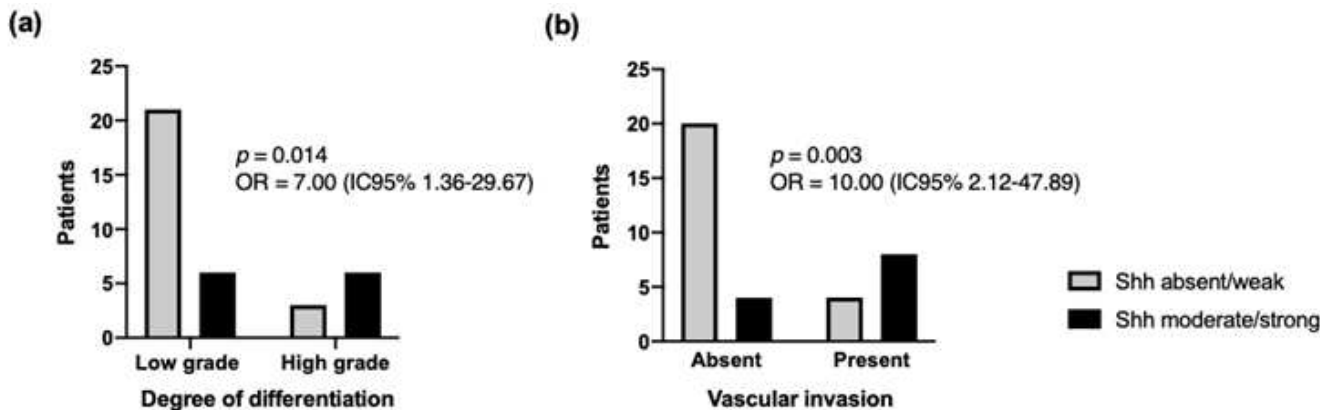


FIGURE 2 – Correlation between the Shh protein immunohistochemical score in the tumor parenchyma and (a) degree of differentiation and (b) vascular invasion in HCC from liver transplantation performed at HC-UFMG in the period between 2003-2015. Analysis by the Chi-Square Test; p-values <0.005 were considered statistically significant.

The analysis of the tumor immunohistochemical score of the Shh protein label showed a statistical correlation with the degree of tumor differentiation [p = 0.014; OR = 7.00 (IC95% 1.36-29.67)], as shown in Figure 2(a). Of the 27 low-grade (GI / GII) cases, 21 (77.8%) had absent/weak labeling. On the other side, of the nine high-grade samples (GIII / GIV), 6 (66.7%) obtained moderate/strong marking.

There was also a significant correlation between the tumor Shh protein expression and the presence of vascular invasion [p=0,003; OR=10 .00 (IC95% 2.12-47.89)]. From the total of 24 cases in which there was no identification of vascular invasion, 20 (83.3%) had absent/weak marking and that. On the other hand, 8 (66,7%) of the 12 cases with invasion showed moderate/strong staining, as shown in Figure 2(b).

DISCUSSION

HCC is the target of several studies that seek to evaluate clinical-morphological characteristics and associate them with prognostic criteria for this neoplasm. In the present study, we evaluated the expression of the Shh protein in surgical specimens with HCC in patients undergoing liver transplantation to correlate it with the clinical and prognostic characteristics already established for this tumor. This study found a positive correlation between Shh protein expression and the degree of tumor differentiation and vascular invasion.

Huang et al. demonstrated elevated levels of Shh protein in HCC samples [14], a finding that points to the importance of components of the Hh pathway in hepatocarcinogenesis. We observed an expressive level of Shh immunostaining in the tumor parenchyma, identified in 55,5% of the 36 samples analyzed. These findings agree with those demonstrated by Xie et al., in which the

activation of the Hh pathway, including detection of Shh, was observed in 59.2% of the HCC samples by in situ hybridization techniques and real-time PCR [23]. The detection of Shh in the adjacent cirrhotic parenchyma was observed in the minority of cases in the study of Xie et al. However, we observed that 55.5% of the cases showed marking, at least weak, in the peritumoral cirrhotic parenchyma. This difference can be explained by the fact that, in the study of Xie et al., there was no description of whether the adjacent area analyzed was of a normal or cirrhotic liver.

In our study, Shh protein labeling was absent in normal liver samples. The marking in adjacent cirrhosis was significantly weaker than the observed in neoplastic cells, which was most associated with the marking moderate/strong (p = 0.009). As cirrhosis is a known risk factor for HCC, this progressive expression of Shh suggests that this protein may be a critical factor in the hepatocarcinogenesis process. As a mechanism, we can propose a higher production of Shh protein in tumor cells contrasted to the adjacent parenchyma, or a more effective modulation of Shh, through its inhibitors, in the non-neoplastic parenchyma [9]. To confirm these hypotheses, additional studies using transcription factors are necessary.

Regarding the etiology of peritumoral liver cirrhosis, some studies have already shown that the expression of the Hh signaling pathway is increased in cells infected by hepatitis B and C viruses [24,25]. In addition to directly contributing to the fibrogenesis process in these cases, the Hh pathway may be associated with hepatocarcinogenesis [9]. Our study found no statistical correlation between the degree of tumor expression of Shh protein and the etiology of the underlying cirrhosis, whether viral or not. Among the limitations observed in this study, we highlight the small number of cases, which may have hindered the global assessment of the correlations proposed here, particularly the expression of Shh protein in the different etiologies

of underlying chronic liver disease.

The degree of differentiation of HCC correlates with the more aggressive behavior of neoplasia and, consequently, a worse prognosis. According to a study carried out by Tamura et al., the histological degree of tumor differentiation alone may represent an independent prognostic factor since low-grade tumors have a three-year increase in survival rate in patients with nodules of varying sizes when compared to patients with high-grade lesions [26]. Studies have demonstrated a correlation between the levels of Shh immunohistochemical staining and the degree of tumor differentiation in HCCs using *in vivo* experimental models [16,27]. However, studies using human samples did not show statistical relevance when correlating the activation of transcriptional factors, such as GLI-1, with the degree of tumor differentiation [14,28]. In this study, we obtained a positive correlation ($p = 0.014$) between the degree of strong/moderate tumor labeling of Shh and tumors considered to be of high grade. The tumoral secretion of Shh induces, through ligand-dependent paracrine signaling, the activation of the glycolytic pathway in adjacent myofibroblasts, leading to the production of ATP and lactate [15]. These elements could be used as an energy source by the tumor, justifying the more proliferative and, therefore, the more aggressive biological behavior in situations where there is increased expression of Shh protein.

The presence of vascular invasion is also a valuable criterion used for HCC staging [21]. We have not found any other work in the literature that assesses the correlation between the presence of vascular invasion and the intensity of marking of components of the Shh signaling pathway. We obtained a statistically valid correlation ($p = 0.003$) when correlating these two parameters. This association, together with that observed with the degree of tumor differentiation, allows us to propose the possibility that the level of Shh cytoplasmic marking can be considered a prognostic factor associated with worse tumor behavior. Although there was a statistically significant difference, the overall differences were modest, given the small cases numbers. Larger studies are needed to conclude the prognostic relevance of SHH immunostaining.

The alpha-fetoprotein level is considered one of the main markers for HCC staging [29-31]. The evaluated cases here had a lower median (5.5 ng/mL) when compared to those typically observed in the literature for patients with HCC, usually above 100 ng/mL [29,30]. Our study found no correlation between Shh tumor immunorepression and serum AFP levels greater than ten ng/mL ($p = 0.526$). Sicklick et al., similarly, found no correlation between AFP levels and markers of the Hedgehog signaling pathway, such

as PTCH and SMOH [32]. However, we observed that patients with AFP less than 10 were more associated with absent/weak immunostaining for Shh (48%), without statistical significance. It is worth mentioning that during the review of electronic medical records, only 23 patients of the 36 studied had a record of serum AFP levels, which, associated with the fact that the tumor's size that enables transplantation are small (Milan criteria), may have contributed to we do not get significant correlations.

Like the other studies already carried out, we did not obtain a good statistical correlation when analyzing the degree of expression of Shh in the tumor parenchyma with the size of the dominant lesion and multiplicity of nodules [14,26-28,34]. This is the first study that evaluated the relationship between the MELD score and Shh protein expression. No correlation was observed between Shh expression in tumor samples and MELD score.

Among the limitations observed in this study, it should be noted that the evaluation of the signaling pathway was performed only using the immunostaining for the Shh ligand. Ren et al. showed that the expression of the transcription factor GLI-1 is a better marker, directly associated with the worse prognosis of HCC [34]. Therefore, it would be essential to evaluate GLI-1 expression in hepatocellular carcinoma samples and its correlation with clinical and morphological parameters, like those used in this work. However, we must emphasize that to analyze the expression of the components of the hedgehog signaling pathway is necessary to use RT-PCR techniques, which, despite being accurate, are expensive and not feasible in most Brazilian services. The immunohistochemistry technique is more feasible to be incorporated into HCC research, diagnosis, and prognosis routines in most laboratories.

CONCLUSION

The immunohistochemical study of the Hh signaling pathway, through the labeling of the Shh protein, may have a promising role as a prognostic factor for HCC in the future, mainly due to the positive correlation between the expression of the Shh protein and the degree of tumor differentiation and invasion vascular. In short, it is concluded that the Hedgehog pathway may have importance in the pathogenic mechanisms of hepatocellular carcinoma and opens perspectives for studying its components as a form of prognostic evaluation.


Acknowledgments: The authors express sincere thanks to Mrs. Fernanda Césari.

REFERENCES

1. Bray F, Ferlay J, Soerjomataram I, et al. Global cancer statistics 2018: GLOBOCAN estimates of incidence and mortality worldwide for 36 cancers in 185 countries. *CA Cancer J Clin.* 2018; 68 (6): 394-424.
2. A Sherif Z. The Rise in the Prevalence of Nonalcoholic Fatty Liver Disease and Hepatocellular Carcinoma. *Nonalcoholic Fatty Liver Disease - An Update.* 2010.
3. Bosman FT, Carneiro F, Hruban RH, et al. World Health Organization Classification of Tumors of the Digestive System. 4. Lyon: IARC. Tumors of the liver and intrahepatic bile ducts. 2010; 195-262.
4. Roskams T, Kojiro M. Pathology of Early Hepatocellular Carcinoma: Conventional and Molecular Diagnosis. *Semin Liver Dis.* 2010; 30(1): 17-25.
5. Shin JW, Chung YH. Molecular targeted therapy for hepatocellular carcinoma: Current and future. *World J Gastroenterol.* 2013; 19(37): 6144-55.
6. Hoshida Y. Molecular classification and novel targets in hepatocellular carcinoma: recent advancements. *Semin Liver Dis.* 2010; 30(1): 35-51.
7. Moeni A. Emerging Signaling Pathways in Hepatocellular Carcinoma. *Liver Cancer.* 2012; 1(2): 83-93.
8. Teglung S, Tofgard R. Hedgehog beyond medulloblastoma and basal cell carcinoma. *Biochim Biophys Acta.* 2010; 1805(2): 181-208.
9. Chuang PT, McMahon AP. Vertebrate Hedgehog signalling modulated by induction of a Hedgehog-binding protein. *Nature.* 1999; 397(6720): 617-21.
10. Capurro MI. Glypican-3 inhibits Hedgehog signaling during development by competing with patched for Hedgehog binding. *Dev Cell.* 2008; 14(5): 700-11.
11. Omenetti A. Hedgehog signaling in the liver. *J Hepatol.* 2011; 54(2): 366-73.
12. Machado MV, Diehl AM. Hedgehog signalling in liver pathophysiology. *J Hepatol.* 2018; 68 (3): 550-62.
13. Michelotti GA, Xie G, Swiderska M, et al. Smoothed is a master regulator of adult liver repair. *J Clin Invest.* 2013; 123(6): 2380-94.
14. Huang S. Activation of the hedgehog pathway in human hepatocellular carcinomas. *Carcinogenesis.* 2006; 27(7): 1334-40.
15. Chan IS, Guy CD, Chen Y, et al. Paracrine Hedgehog signaling drives metabolic changes in hepatocellular carcinoma. *Cancer Res.* 2012; 72(24): 6344-50.
16. Cai H. Sonic hedgehog signaling pathway mediates development of hepatocellular carcinoma. *Tumor Biol.* 2016; 16: 5463-6.
17. Rodríguez- Perálvarez M, Luong TV, et al. A systematic review of microvascular invasion in hepatocellular carcinoma: diagnosis and prognostic variability. *Ann Surg Oncol.* 2013; 20: 325-39.
18. Fan L, Pepicelli CV, Dibble CC, et al. Hedgehog signaling promotes prostate xenograft tumor growth. *Endocrinology.* 2004; 145(8): 3961-70.
19. Thayer S, di Magliano, M Heiser P, et al. Hedgehog is an early and late mediator of pancreatic cancer tumorigenesis. *Nature.* 2003; 425(6960): 851-6.
20. Varnat F, Duquet A, Malerba M. Human colon cancer epithelial cells harbor active HEDGEHOG-GLI signalling that is essential for tumor growth, recurrence, metastasis and stem cell survival and expansion. *EMBO Mol Med.* 2009; 1(6-7): 338-51.
21. Amin MB, Edge SB, Greene FL, et al. *AJCC Cancer Staging Manual.* 8th ed. New York: Springer. 2017.
22. Chen L, Shi Y, Jiang C, et al. Expression and prognostic role of pan-Ras, Raf-1, pMEK1 and pERK1 / 2 in patients with hepatocellular carcinoma. *Eur J Surg Oncol.* 2011; 37(6): 513-20.
23. Xie J. Activation of the hedgehog pathway in human hepatocellular carcinomas. *Carcinogenesis.* 2006; 27(7): 1334-40.
24. Feitelson M. Hedgehog signaling blockade delays hepatocarcinogenesis induced by hepatitis B virus X (HBx) protein. *Cancer Res.* 2012; 72(22): 5912-20.
25. Choi S. Upregulation of Hedgehog Pathway is Associated with Cellular Permissiveness for Hepatitis C Virus Replication. *Hepatology.* 2011; 54(5): 1580-90.
26. Tamura S, Kato T, Berho M, et al. Impact of histological grade of hepatocellular carcinoma on the outcome of liver transplantation. *Arch Surg.* 2001; 136(1): 25-30.
27. Kumari R, Tripathy A. The molecular connection of histopathological heterogeneity in hepatocellular carcinoma: A role of Wnt and Hedgehog signaling pathways. *PLoS One.* 2018; 13 (12): e0208194.
28. Chun HW, Hong R. Significance of the hedgehog pathway-associated proteins Gli-1 and Gli-2 and the epithelial-mesenchymal transition-associated proteins Twist and E-cadherin in hepatocellular carcinoma. *Oncol Lett.* 2016; 12(3): 1753-62.
29. Ataide EC, Machado RR, Ribeiro MBC, et al. Correlation of alpha - fetoprotein level, survival rate and tumor recurrence in patients undergoing liver transplantation. *Arq Bras Cir Dig.* 2011; 24: 43-47.
30. Forner A, Reig M, Bruix J. Alpha-fetoprotein for hepatocellular carcinoma diagnosis: the demise of a brilliant star. *Gastroenterology.* 2009; 137(1): 26-9.

31. Hirata K. Prognostic roles of preoperative α -fetoprotein and des- γ -carboxy prothrombin in hepatocellular carcinoma patients. *World J Gastroenterol.* 2015; 21(16): 4933-45.
32. Jason K. Sicklick, Yin-Xiong Li, et al. Dysregulation of the Hedgehog pathway in human hepatocarcinogenesis. *Carcinogenesis.* 2006; 27(4): 748-57.
33. Cucchetti A, Ercolani G, Vivarelli M, et al. Impact of model for end-stage liver disease (MELD) score on prognosis after hepatectomy for hepatocellular carcinoma on cirrhosis. *Liver Transpl.* 2006; 12(6): 966-71.
34. Ren J, Jia J, Yan-Hua Y, et al. Activation of sonic hedgehog signaling pathway is an independent potential prognosis predictor in human hepatocellular carcinoma patients. *Chin J Cancer Res.* 2012; 24(4): 323-31.

CORRESPONDING AUTHOR

Paula Vieira Teixeira Vidigal  0000-0002-7003-5159
pvidigal@medicina.ufmg.br



This is an open-access article distributed under the terms of the Creative Commons Attribution License.