

See discussions, stats, and author profiles for this publication at: <https://www.researchgate.net/publication/337415946>

Scanning Electron Microscopic/Energy-Dispersive X-Ray Analysis in Cases of Apical Periodontitis Refractory to Endodontic Treatment: A Case Series Study

Article in Iranian Endodontic Journal · August 2019

DOI: 10.22037/iej.v14i4.26018

CITATIONS

0

READS

66

5 authors, including:



Taia M B Rezende

Universidade Católica de Brasília

66 PUBLICATIONS 1,018 CITATIONS

[SEE PROFILE](#)



Ingrid Gracielle Martins da Silva

University of Brasilia

12 PUBLICATIONS 47 CITATIONS

[SEE PROFILE](#)



Antônio Paulino Ribeiro Sobrinho

Federal University of Minas Gerais

83 PUBLICATIONS 1,367 CITATIONS

[SEE PROFILE](#)

Some of the authors of this publication are also working on these related projects:



Project

Antimicrobial activity its immunomodulatory potencial against Candidemia [View project](#)



Project

In type 2 diabetics, eight weeks of resistance training does not reduce blood pressure but does prevent increases: A randomized controlled trial [View project](#)



Scanning Electron Microscopic/Energy-Dispersive X-Ray Analysis in Cases of Apical Periodontitis Refractory to Endodontic Treatment: A Case Series Study

Warley Luciano Fonseca Tavares^a , Taia Maria Berto Rezende^{bcd} , Ingrid Gracielle Martins da Silva^e , José Raimundo Corrêa^e , Luiz Carlos Feitosa Henriques^a , Antônio Paulino Ribeiro Sobrinho^a

^a Departamento de Odontologia Restauradora, Faculdade de Odontologia, Universidade Federal de Minas Gerais, Belo Horizonte, Minas Gerais, Brazil; ^b Faculdade de Odontologia, Universidade Católica de Brasília, Brasília, Distrito Federal, Brazil; ^c Programa de Pós-Graduação em Ciências Genômicas e Biotecnologia, Universidade Católica de Brasília, Brasília, Distrito Federal, Brazil; ^d Programa de Pós-Graduação em Ciências da Saúde, Universidade de Brasília, Brasília, Distrito Federal, Brazil; ^e Laboratório de Microscopia e Microanálises, Departamento de Biologia Celular, Instituto de Ciências Biológicas, Universidade de Brasília, Brazil

ARTICLE INFO

Article Type: Case Report

Received: 18 Jun 2019

Revised: 15 Aug 2019

Accepted: 31 Aug 2019

Doi: 10.22037/iej.v14i4.26018

*Corresponding author: Warley Luciano Fonseca Tavares. Avenida Antônio Carlos 6627, Minas Gerais, Brazil. E-mail: warleyt@hotmail.com



© The Author(s). 2018 Open Access This work is licensed under the terms of the Creative Commons Attribution-NonCommercial-ShareAlike 4.0 International.

ABSTRACT

This study aimed to present a case series of refractory endodontic treatment leading to persistent apical periodontitis. All cases were submitted to scanning electron microscopic/energy-dispersive X-ray analysis (SEM/EDS) of the external surface of the surgically removed samples and identification of the elements present in the specimens. Carbon, oxygen and calcium were elements present in all of the cases in this study. The presence of microorganisms in close contact with the periapical surrounding tissues induced the perpetuation of the inflammation process. Despite the presence of other elements different from those normally expected in the tissues, we may not attribute any interference in the periapical response to them.

Keywords: Apical Periodontitis; Bacterial Biofilm; Endodontic Failure; Extra Radicular Infection

Introduction

The goals of endodontic treatment are focused on maintaining the asepsis in vital pulp cases or on the complete removal of root canal infection in necrotic cases as well as on three-dimensional hermetic sealing with biocompatible materials [1, 2]. However, in some circumstances, the development or persistence of apical periodontitis is observed, even in those cases with radiographically apparent satisfactory root canal treatment [3].

Histological studies in cases of endodontic failure have demonstrated the presence of microorganisms in areas inaccessible to endodontic instruments and irrigating solutions, such as the isthmii, canal ramifications and deep dentinal tubules [4]. Refractory infection exhibits a more complex scenario with the aid of molecular identification methods when compared to culture [5]. Extra radicular infections are associated with apical periodontitis

lesions that have not responded favorably to the root canal treatment [6, 7]. In addition, the presence of a complex microbiota has been described in the external root surface of the tooth and is mainly associated with the pre-existing intracanal infection [4].

Although it has been stated that apical periodontitis is bacteria dependent, nonbacterial foreign materials located in the periapical tissue can induce and perpetuate a foreign body reaction that leads to apical inflammation and treatment failure [8, 9]. X-ray microanalysis indicated the presence of magnesium and silicon, presumably as the remnants of a talc-contaminated gutta-percha that protruded into the periapex and that had been resorbed during the follow-up period [8]. The presence of amalgam components, cellulose fibers, endodontic sealants and salts derived from the peri-apically extruded root canal dressing in periapical biopsies with a history of endodontic failure also have been reported [8, 10].

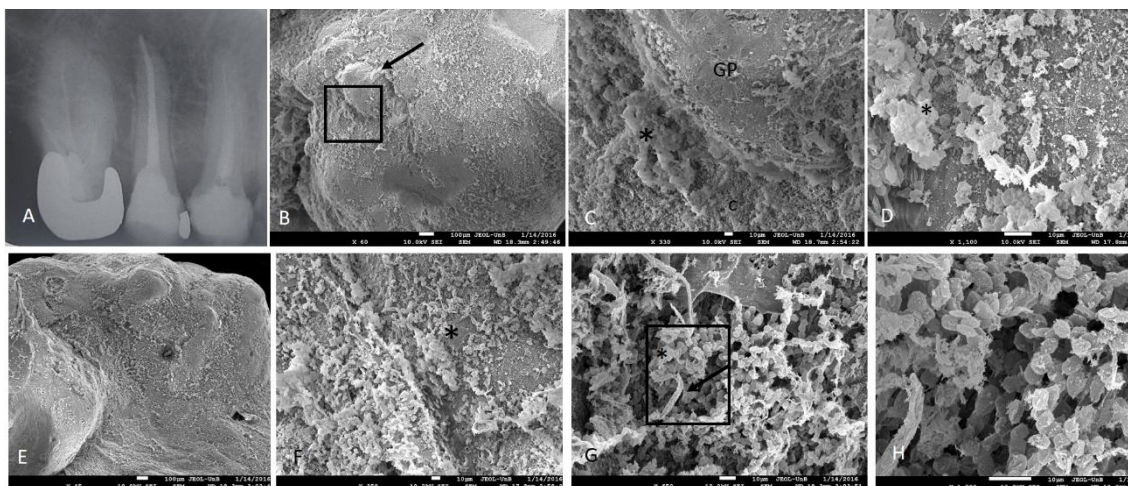


Figure 1. A) Rx exam of the right maxillary second premolar demonstrates apical periodontitis; B) SEM analysis (60× magnification) of apical root encompassing the gutta-percha cone that is seen in the foramen (arrow); C) Magnification of selected area in B. Interface between gutta-percha (GP) and cementum (c) with presence of dense bacterial biofilm (*); D) Higher magnification demonstrate bacterial agglomerate (*) in the outer root surface in the same region of C; E) Panoramic view of the lateral apical surface; F) Massive bacterial biofilm revealed in the root surface (*); G) Higher magnification in the same region of F. reveals presence of cocci (*) and filamentous bacteria (arrow); H) Detailed view of the selected area in G

However, information regarding the nonbacterial substances associated with cases of apical periodontitis persisting after root canal treatment and their role in the perpetuation of periapical diseases are not completely clear and are still a matter of debate. Thus, this study presents a case series of post-nonsurgical endodontic treatment leading to persistent apical periodontitis. All cases were submitted to scanning electron microscopic/energy-dispersive X-ray analysis (SEM/EDS) of the external surface of the surgically removed samples and identification of the elements present in the specimens.

Materials and Methods

The patients in the selected cases in this study presented with refractory apical periodontitis to endodontic treatment and an indication for apical surgery. An exception was the patient in case 4, who already had undergone unsuccessful apical surgeries and was indicated for extraction. The periodontal health of the cases were carefully examined, and none of them presented any probing depth. All patients were informed about the risks and benefits of the surgical procedures and signed a consent form to participate in this study.

Surgical procedure

In those patients indicated for apical surgery, after they received local anesthesia, a Newman's surgical access flap was created, and curettage of the periapical lesion was conducted. A 3-mm apical resection without bevel was then performed to remove apical ramifications, lateral canals and necrotic, infected tissue. The resected specimens were kept in 10% formaldehyde (Anidrol, São

Paulo, Brazil) until the analyses were performed. A retro cavity was prepared using an ultrasonic tip (Trinks TRI21D-A1, São Paulo, Brazil) under copious irrigation with sterile saline, followed by its filling with white mineral trioxide aggregate (MTA) (Angelus, Londrina, Brazil), and the flap was repositioned and sutured. For the patient in case 4, the tooth was carefully extracted with the use of a delicate periosteal elevator (Maximus, Belo Horizonte, Brazil), and the wound was cleaned from any granulations and washed with sterile saline before a suture was placed. All of the patients were followed up for a minimum period of two years.

Scanning electron microscopic/energy-dispersive X-ray analysis (SEM/EDS)

The root fragments removed during peri-radicular surgery or the tooth extracted was immediately immersed in 10% formaldehyde (Anidrol, São Paulo, Brazil). The samples were rinsed three times in sodium cacodylate buffer (0.1 M) and submitted to an additional fixative step in glutaraldehyde aqueous solution (2.5% v:v) for 48 h at 4 °C. The samples were rinsed three times in sodium cacodylate buffer (0.1 M) for 15 min each time and were then treated in aqueous osmium tetroxide solution (1%) for 30 min in a dark chamber. The samples were rinsed an additional three times in sodium cacodylate buffer (0.1 M) for 15 min each time and dehydrated in an aqueous acetone solution series of 30%, 50%, 70%, 90% and 100%. All of the dehydration steps were performed by sample immersion for 15 min at room temperature. The samples were dried with CO₂ to the critical point with the Balzers CPD 030 critical point dryer (New York, NY, USA). The samples were attached to aluminum stubs and were coated with

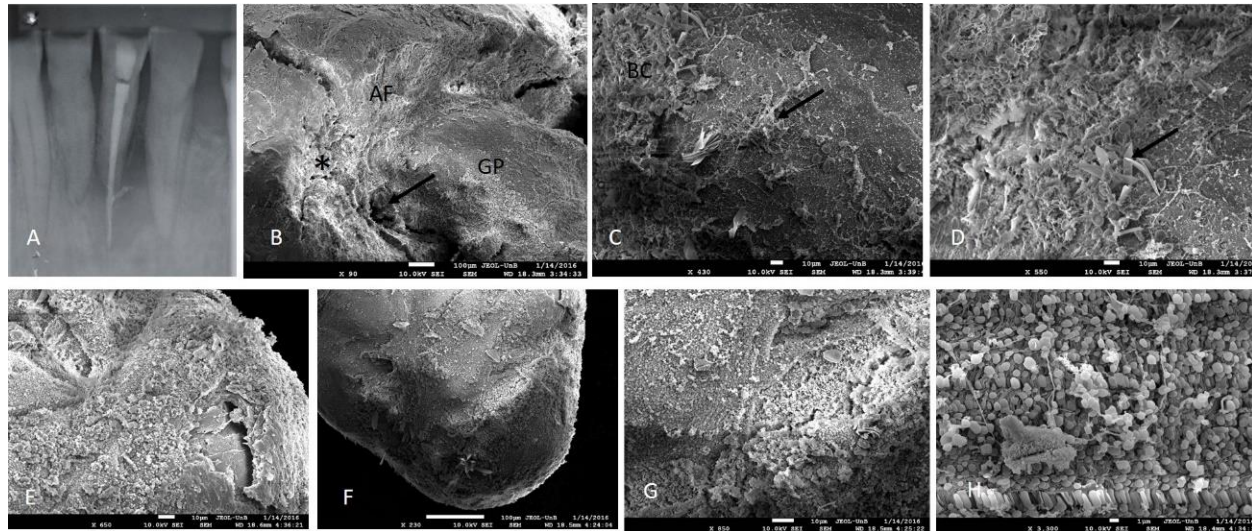


Figure 2. A) Rx exam of the left mandibular central incisor demonstrates severe extrusion of root canal filling; B) 90× magnified view of the interface between gutta-percha (GP) and the apical foramen (AF). A gap in the interface is evident (arrow), and an area of root resorption with erosions can be observed (*); C) Magnified view of the area in B. Fibrous tissue can be noticed recovering the gutta-percha and blood cells are demonstrated (BC); D) Magnified view of C. Presence of fibrous tissue and red blood cells and platelets suggests the presence of coagulum. A crystallographic structure that represents the gutta-percha can be noticed (arrow); E) Overview of the apical root surface demonstrates a dense bacterial biofilm; F) Apical extruded gutta-percha overview; G) Magnified view of F. Presence of biofilm covering the gutta-percha; H) Detailed view of the dense bacterial biofilm

20 nm of gold using the Balzers SCD 050 sputter coater (New York, NY, USA). The images were acquired with the JSM-70001F field emission scanning electron microscope (Akishima, Tokyo, Japan). After image acquisition was performed, the samples were submitted to EDS from multiple point-and-shoot spectrum collections to complete X-ray imaging.

Case Series

Case 1

A 60-year-old woman presented with persistent fistula of the right second maxillary premolar for two years after root canal treatment. As the root canal filling presented with a good quality, surgical apical resection was performed. The resected apical specimen was kept in 10% formaldehyde (Anidrol, São Paulo, Brazil) until the SEM analysis was performed. The presence of a bacterial biofilm in the interface between the gutta-percha and the cementum was demonstrated by SEM. High magnifications demonstrated the presence of cocci and filamentous bacteria in the external surface of the apical resection (Figure 1).

The X-ray microanalysis revealed the presence of carbon (C), oxygen (O) and calcium (Ca) elements. Any other substances different from those expected in biological tissues were not found in the 3 mm apical resection (Table 1).

Case 2

A 70-year-old woman was referred to apical surgery of the left mandibular central incisor. The tooth was previously retreated because of the presence of acute symptoms. However, after the retreatment, severe root canal filling extrusion occurred and pain persisted. The 3 mm apical root was resected and sent to undergo analysis, which indicated a gap between the gutta-percha and apical foramen. Areas of cementum resorption could be observed. An overview of the specimen showed the presence of a dense bacterial biofilm, which was also present in the surface of the extruded gutta-percha from the canal. At higher magnifications, the detailed morphology of the bacterial consortium was identified (Figure 2).

The X-ray microanalysis showed the presence of niobium (Nb) as a different element from those normally observed in biological samples (Table 1).

Case 3

A 26-year-old woman presented with acute symptoms arising from the right maxillary lateral incisor. A radiograph exam showed the presence of a fractured instrument and apical periodontitis. The tooth was retreated unsuccessfully. The broken instrument could not be bypassed, and a deviation occurred. The tooth remained with calcium hydroxide dressing for a period of 30 days before canal obturation and coronal sealing with a




Figure 3. A) Preoperative Rx of the right maxillary lateral incisor. Presence of a canal deviation and fractured instrument that prevented an adequate debridement of the root canal; B) Immediate post-operative Rx; C) SEM of the resected apical root. Note the presence of cracks associated with the canal where the fractured endodontic file is present; D) Apical analysis demonstrated the presence of coagulum derived from the surgical management and bacterial agglomerate (arrow)

composite resin were performed. After a 1-month retreatment, a sinus tract was presented, and apical surgery was indicated. The root was apically resected at a 3 mm level. The tooth was retro-prepared with ultrasound (Trinks TRI21D-A1, São Paulo, Brazil) and retro-filled with white MTA (Angelus, Londrina, Brazil). The resected apical specimen was then sent to undergo analysis.

In the surface of the root resection, the presence of cracks was associated with the canal, where a separated fragment of an endodontic file was present. Bacteria were not identified in the cracks near the broken file. The specimen was recovered with dense granular tissue, and bacteria were arranged in agglomerates on the external surface of the root (Figure 3).

The X-ray microanalysis indicated the presence of regular compounds of biological tissues in the apical area. On the surface of the resected root, platinum (Pt) was identified as a different substance (Table 1).

Case 4

A 46-year-old woman was referred to endodontic retreatment of the right mandibular first molar. The root canals were filled with silver cones, and despite it the patient being asymptomatic, apical periodontitis was noticed radiographically. Two years after retreatment, the tooth became symptomatic and edema was observed. As the radiographic radiolucency persisted in the mesial root, surgical resection was performed. After a two-year follow up,

the apical periodontitis persisted. At this time, a new resection was performed, and the mesial root was retro-prepared with ultrasound and a sealed MTA. At one year after the second surgical intervention, the apical healing was not noticed, and the tooth was thus extracted.

The SEM analysis revealed the presence of granular tissue in the apical third of the mesial and distal roots. Microcracks with intimate contact with granular tissue were noticed in the resected mesial root, and round bacterial cells were observed (Figure 4). The apical surface of the retro-filled mesial root could not be scanned as a dense biological granular tissue was covering it. In the distal root, the gutta-percha and endodontic sealer were observed as having fibrous connective tissue attached.

The X-ray microanalysis was performed in two different areas. In the medium third of the roots, Pt and Nb were present in association with the regular biological elements. However, in the apical third of the roots, Nb, but not Pt, was found (Table 1).

Discussion

As it was demonstrated by Miller [11], the diversity of the endodontic microbiota may be underestimated by culture methods as compared to microscopically examination. More than a century after these findings, the presence of filamentous bacteria, which had been rarely associated with endodontic




Figure 4. A) Preoperative Rx; B) SEM analysis overview. The presence of granular tissue can be noticed; C) Presence of cracks in the mesial roots (arrows); D) Granular tissue covering the mesial roots; E) Detailed view of the apical distal root. Note the presence of endodontic sealer arranged as layers; F) Augmented view to the apical endodontic sealer (*) in contact with the crystallographic arrangement of gutta-percha (arrow)

infection, was again identified as part of the endodontic microbial consortium with the aid of molecular methods [12]. In this study, filamentous bacteria were present in the extra radicular bacterial agglomerate. In all patients in this study, a dense mass of microorganism was identified in the external root. Molecular biology studies indicated that intra-radicular infection occurs in virtually all root canal-treated teeth evincing apical periodontitis [13, 14]. In the present study, although an intracanal bacterial sampling was not performed, we may assume that the external biofilm observed is an extension of the root canal infection that took place beyond the confines of the root canals.

When arranged in a biofilm, bacteria are more protected from the host defenses and antibiotics and can exert their virulence against the surrounding tissues, maintaining the inflammation response [15]. The position of the bacterial agglomerates in the surrounding external apex allows them to escape from the operator strategies of disinfection mechanical-chemical preparation of the root canals to the apical foramen, the use of a patency file, the foramen enlargement and root canal medications. Accordingly, the persistence of bacteria in the apical and lateral root canals and within the dentinal tubules was reported, even after long periods of intracanal calcium hydroxide placement, which could have led to the failure of endodontic treatment [6, 16].

It is noteworthy that SEM analysis could not be performed with a concomitant culture or molecular bacterial identification method in this study, as it was necessary to keep the apical specimens intact. The sampling for a culture or molecular method would interfere in the structure of the external root biofilm and reduce the reliability of the SEM results. Despite that we could not identify the species present in the biofilm, it presented with a diversity of bacteria phenotypes derived from the intracanal infection. These findings corroborate with a previous study that demonstrated that the microbial climax community in teeth refractory to endodontic treatment is much more complex than what was previously thought. These microbial communities not only harbor medically important species but also contain distinct microbial consortia present at different population levels [5].

In case 4, despite all the conventional and surgical efforts, the treatment failed. The presence of microorganisms was apically evident as being in close contact with cracks presented in that area, which enforce the possibility that the created fissures harbored an infection that was difficult to remove. Whether these cracks already existed at the time of endodontic retreatment is impossible to predict, but the patient had a history of bruxism and had fractured other teeth due to this parafunctional habit. Therefore, a sum of factors may be the answer for the unsuccessful result of this case.

In case 3, a lack of microorganisms inside the cracked area was noticed, and despite it reaching the cementum, bacteria were present only externally to the root. It must be emphasized that the SEM vacuum processing of the samples may cause tissue distortion and therefore induction of cracks. Thus, we may speculate that this is an explanation for the presence of cracks not associated to the presence of microorganism in the samples. It was noticed that the fractured instrument fragment in that case was not associated with bacteria, which reinforces the notion that external contamination was the main cause of the endodontic failure. In accordance with our findings, other studies also demonstrated by SEM that the maintenance of apical periodontitis occurred in response to a direct contact of infectious microbes with apical tissues [7, 17].

Carbon, oxygen and calcium were elements present in all of the cases in this study. In agreement with this finding, Koppang *et al.* [9] indicated the presence of basophilic fragments compatible with Ca salts from calcium hydroxide that extruded peri-apically and birefringent structures indicating C and O in post endodontic periapical granulomas and cysts. Pt was identified

in case 3, which is probably related to the presence of the fractured instrument. In case 4, this element may be associated with the silver cones, which were previously present from the endodontic retreatment.

Magnesium and silicon were indicated by X-ray microanalysis and were associated with the presence of vast numbers of multinucleate giant cells in a case of refractory apical periodontitis, which is most likely related to a talc- contaminated gutta-percha that protruded into the periapex [8]. In cases 2 and 4 of this study, the presence of the gutta-percha beyond the apex was associated with the presence of Nb. This element is presumably a compound of the gutta-percha cones or endodontic sealer. The incorporation of niobium pentoxide (Nb₂O₅) in dental materials could increase their radiopacity and microhardness [18] and can promote crystal growth and mineralization of the surrounding tissues [19]. The niobium phosphate glass presents a bioactivity and biocompatibility in vivo [20], contributing to hydroxyapatite deposition [21, 22]. Therefore, it is unlikely that this element is associated with the unsuccessful results of those cases.

Table 1. Characteristics of the cases

| Element Line | Net Counts | Weight % | Atom % | Formula | Compnd % |
|--------------|------------|----------|--------|---------|----------|
| C K | 709 | 38.35 | 47.78 | C | 38.35 |
| O K | 290 | 51.96 | 48.60 | O | 51.96 |
| Ca K | 40 | 9.69 | 3.62 | Ca | 9.69 |
| Total | | 100.00 | 100.00 | | 100.00 |
| C K | 651 | 24.46 | 54.89 | C | 24.46 |
| O K | 211 | 16.62 | 28.01 | O | 16.62 |
| Nb L | 1168 | 58.93 | 17.10 | Nb | 58.93 |
| Total | | 100.00 | 100.00 | | 100.00 |
| C K | 92 | 7.91 | 13.46 | C | 7.91 |
| O K | 160 | 51.64 | 65.93 | O | 51.64 |
| Ca K | 119 | 40.44 | 20.61 | Ca | 40.44 |
| Total | | 100.00 | 100.00 | | 100.00 |
| C K | 296 | 5.72 | 20.69 | C | 5.72 |
| O K | 396 | 17.87 | 48.53 | O | 17.87 |
| Ca K | 327 | 15.97 | 17.32 | Ca | 15.97 |
| Pt M | 1544 | 60.44 | 13.46 | Pt | 60.44 |
| Total | | 100.00 | 100.00 | | 100.00 |
| C K | 395 | 13.29 | 41.81 | C | 13.29 |
| O K | 195 | 14.25 | 33.67 | O | 14.25 |
| Ca K | 88 | 7.07 | 6.67 | Ca | 7.07 |
| Nb L | 418 | 24.33 | 9.90 | Nb | 24.33 |
| Pt M | 648 | 41.06 | 7.95 | Pt | 41.06 |
| Total | | 100.00 | 100.00 | | 100.00 |
| C K | 350 | 18.54 | 42.33 | C | 18.54 |
| O K | 183 | 21.56 | 36.94 | O | 21.56 |
| Ca K | 67 | 7.88 | 5.39 | Ca | 7.88 |
| Nb L | 625 | 52.02 | 15.35 | Nb | 52.02 |
| Total | | 100.00 | 100.00 | | 100.00 |

Case 3A. Apical portion of the specimen; B. Area in contact with the fractured instrument at 3 mm from the apex; Case 4A. Medium third of the root; B. Apical third of the root

Conclusion

The observations in this study led us to conclude that the presence of microorganisms in close contact with the periapical surrounding tissues induced the perpetuation of the inflammation process. Despite the presence of other elements different from those normally expected in the tissues, we may not attribute to them any interference in the periapical response. The cracks represent a bacteria harbor and are related to a difficult infection reduction despite the endodontic efforts during treatment.

Acknowledgment

This work was supported by the Fundação de Amparo à Pesquisa do Estado de Minas Gerais (FAPEMIG), Coordenação de Aperfeiçoamento de Pessoal de Nível Superior (CAPES), Conselho Nacional de Desenvolvimento Científico e Tecnológico (CNPq) and Pró-Reitoria de Pesquisa da Universidade Federal de Minas Gerais (PRPq-UFMG). The authors report that there are no conflicts of interest to disclose. The authors wish to thank the postgraduate program at the School of Dentistry of UFMG and the laboratory of electronic microscopy of the Universidade de Brasília.

Conflict of Interest: 'None declared'.

References

- Bender IB, Seltzer S, Soltanoff W. Endodontic success--a reappraisal of criteria. 1. Oral Surg Oral Med Oral Pathol. 1966;22(6):780-9.
- Lin LM, Pascon EA, Skribner J, Gangler P, Langeland K. Clinical, radiographic, and histologic study of endodontic treatment failures. Oral Surg Oral Med Oral Pathol. 1991;71(5):603-11.
- Nair PN. On the causes of persistent apical periodontitis: a review. Int Endod J. 2006;39(4):249-81.
- Ricucci D, Siqueira JF, Jr., Lopes WS, Vieira AR, Rocas IN. Extraradicular infection as the cause of persistent symptoms: a case series. J Endod. 2015;41(2):265-73.
- Henriques LC, de Brito LC, Tavares WL, Teles RP, Vieira LQ, Teles FR, Sobrinho AP. Microbial Ecosystem Analysis in Root Canal Infections Refractory to Endodontic Treatment. J Endod. 2016;42(8):1239-45.
- Ricucci D, Loghin S, Siqueira JF, Jr. Exuberant Biofilm infection in a lateral canal as the cause of short-term endodontic treatment failure: report of a case. J Endod. 2013;39(5):712-8.
- Signoretti FG, Endo MS, Gomes BP, Montagner F, Tosello FB, Jacinto RC. Persistent extraradicular infection in root-filled asymptomatic human tooth: scanning electron microscopic analysis and microbial investigation after apical microsurgery. J Endod. 2011;37(12):1696-700.
- Nair PN, Sjogren U, Krey G, Sundqvist G. Therapy-resistant foreign body giant cell granuloma at the periapex of a root-filled human tooth. J Endod. 1990;16(12):589-95.
- Koppang HS, Koppang R, Stølen SO. Identification of common foreign material in postendodontic granulomas and cysts. J Dent Assoc S Afr. 1992;47(5):210-6.
- Koppang HS, Koppang R, Solheim T, Aarnes H, Stølen SØ. Cellulose fibers from endodontic paper points as an etiological factor in postendodontic periapical granulomas and cysts. Journal of endodontics. 1989;15(8):369-72.
- Miller WD. An introduction to the study of the bacterio-pathology of the dental pulp. Dental Cosmos. 1894;36:505-28.
- Tavares WL, Neves de Brito LC, Teles RP, Massara ML, Ribeiro Sobrinho AP, Haffajee AD, Socransky SS, Teles FR. Microbiota of deciduous endodontic infections analysed by MDA and Checkerboard DNA-DNA hybridization. Int Endod J. 2011;44(3):225-35.
- Rocas IN, Siqueira JF, Jr., Aboim MC, Rosado AS. Denaturing gradient gel electrophoresis analysis of bacterial communities associated with failed endodontic treatment. Oral Surg Oral Med Oral Pathol Oral Radiol Endod. 2004;98(6):741-9.
- Siqueira JF, Jr., Rocas IN. Polymerase chain reaction-based analysis of microorganisms associated with failed endodontic treatment. Oral Surg Oral Med Oral Pathol Oral Radiol Endod. 2004;97(1):85-94.
- Chavez de Paz LE. Redefining the persistent infection in root canals: possible role of biofilm communities. J Endod. 2007;33(6):652-62.
- Ricucci D, Siqueira JF, Jr. Anatomic and microbiologic challenges to achieving success with endodontic treatment: a case report. J Endod. 2008;34(10):1249-54.
- Furusawa M, Asai Y. SEM observations of resected root canal ends following apicoectomy. Bull Tokyo Dent Coll. 2002;43(1):7-12.
- Leitune VC, Takimi A, Collares FM, Santos PD, Provenzi C, Bergmann CP, Samuel SM. Niobium pentoxide as a new filler for methacrylate-based root canal sealers. Int Endod J. 2013;46(3):205-10.
- Karlinsey RL, Hara AT, Yi K, Duhn CW. Bioactivity of novel self-assembled crystalline Nb₂O₅ microstructures in simulated and human salivas. Biomed Mater. 2006;1(1):16-23.
- Carbonari M. Development of bioactive niobium phosphate glasses [Ph. D. thesis]. Sao Paulo, Brazil: Energy and Nuclear Research Institute. 2003.
- Kokubo T, Takadama H. How useful is SBF in predicting in vivo bone bioactivity? Biomaterials. 2006;27(15):2907-15.
- Oh SH, Finones RR, Daraio C, Chen LH, Jin S. Growth of nano-scale hydroxyapatite using chemically treated titanium oxide nanotubes. Biomaterials. 2005;26(24):4938-43.

Please cite this paper as: Fonseca Tavares WL, Berto Rezende TM, Ingrid Martins da Silva G, Raimundo Corrêa J, Feitosa Henriques LC, Ribeiro Sobrinho AP. Scanning Electron Microscopic/Energy-Dispersive X-Ray Analysis in Cases of Apical Periodontitis Refractory to Endodontic Treatment: A Case Series Study. Iran Endod J. 2019;14(4): 306-12. *Doi:* 10.22037/iej.v14i4.26018.