

Immature mast cells predominate in skin wound repair in senescent mice

Coelho Monique Macedo, Barreto Rafaela De Melo, Resende Juliana Aparecida Pinto De, Monteiro Juan Filipi, Castro Rosiane Aparecida De, Pinto Flávia Carmo Horta, Carvalho Claudia Rocha & Costa Raquel Alves*

¹Natural Science, Federal University of São João del Rei-Brazil

Received 08 November 2022; revised 04 August 2023

Role of mast cells in various phases of skin wound healing is well reported in literature. However, there is much controversy about the importance of mast cells in skin wound repair. Few studies have demonstrated the presence of mast cells in skin wound repair in middle-aged and senescent individuals. The mast cells are resident cells in the skin and participate in the inflammatory process and wound repair response. It is known that there are major changes in the immune system with aging, including in the skin. In this work, we evaluated the density and maturation of mast cells (mature, intermediate and immature) at the edges of skin wounds in young, middle-aged and senescent mice by toluidine blue and alcianine-safranin blue staining. We found that there is a significant decrease in mast cells in senescent mice. There is a predominance of immature mast cells at all ages 5 days after injury. But the data are intriguing, as in senescent mice there are fewer mature mast cells. Further studies should be carried out to understand the role of mast cells during aging.

Keywords: Aging, Wound healing

Mast cells (MCs) are cells of the immune system, derived from pluripotent bone marrow cells that participate in processes such as acute and chronic inflammation, tissue repair, pathogens removal, maintenance of tissue homeostasis, allergies and some autoimmune diseases¹. MCs are distinguished by protease compounds, having predominantly tryptases, chymases or both^{2,3}. In connective tissue MCs are present that have both proteases with a granular heparin-rich profile, whereas MCs present in the mucosa have a predominance of chymases⁴. MCs considered mature have granules with a higher amount of proteases and those with a higher amount of proteoglycans are immature⁵. In addition, they express different patterns of tissue-specific cytokines and receptors that provide functions related to the cell context, being the immune system cell with the highest transcriptional activity⁶. These cells are resident in the skin and are found near blood vessels, lymphatic vessels, glands, smooth muscle, and nerves ensuring homeostasis^{7,8}. When have an injury to the skin there are phases of repair that are coordinated and overlapping: hemostasis, inflammation, tissue formation and remodeling⁹.

After injury, MCs release pro-inflammatory and immunomodulatory mediators, such as histamine and

*Correspondence:

Phone: +55 31 9 9778 5856

E-Mail: raquel.costa@ufsj.edu.br

TNF- α , responsible for inducing blood clotting, preventing exacerbated blood extravasation^{10,11}. In addition, keratinocytes and macrophages release monocyte chemoattractant protein-1 (MCP-1), which is responsible for recruiting mast cells from the peripheral blood. In the inflammatory phase they increase vascular permeability and allow recruitment of neutrophils and monocytes (which differentiate into macrophages) that produce pro-inflammatory cytokines (such as IL-1 α and TNF- α) for activation and proliferation of keratinocytes and fibroblasts and increasing angiogenesis^{10,12}. Resident MCs, along with recruited mast cells, secrete factors that mediate reepithelialization and angiogenesis of the injured site, among these factors are secreted vascular endothelial growth factor (VEGF), epidermal growth factor (EGF) and fibroblast growth factor (FGF)^{13,14}. In the final stage of repair, recruited MCs through the secretion of mediators indirectly stimulate fibroblasts by acting on their proliferation, synthesis of extracellular matrix, and differentiation of fibroblasts into myofibroblasts^{12,15}.

Depletion of mast cells does not interfere with wound repair^{16,17}. However, other studies demonstrate that their absence is also unrelated to bleomycin-induced decrease in fibrosis¹⁷. Skin wound models in diabetic mice have increased degranulation of these types of cells when compared to non-diabetic

animals¹⁸. However, it is believed that the discrepancies found in these studies are due to the different mice models used, which consequently show some alteration in the immune system¹⁹.

With skin aging there are also several changes, such as an excess of senescent cells, decreased cell proliferation/tissue recovery, decreased reepithelialization rate, alteration of the extracellular matrix with decreased collagen production and increased collagen degradation, pro-inflammatory environment that provides undesirable situations such as the appearance of pathologies and scars, resulting in decreased skin elasticity²⁰⁻²². Role of mast cells various phases of wound healing, particularly in the repair of skin wounds in middle-aged and senescent individuals has been reported already. In view of the great changes that occur in the immune system with aging, including in the skin, in this work, we evaluated the quantity and maturation of mast cells at the edges of skin wounds of young, middle-aged and senescent mice.

Material and Methods

Animals

For the experiment, male Swiss mice with 8, 40 and 67 weeks of age, identified as young, middle-aged and senescent, respectively, were used. The animals were kept in a breeding unit of the Natural Sciences Department, UFSJ, Brazil. After weaning they remained in the Experimental Animal Laboratory with standard mouse chow and water, according to the recommendations of the Ethics Committee on Animal Experimentation of UFSJ (Comitê de ética em experimentação animal- CEUA-UFSJ). Each group contained six mice per point time.

Wounding

Mice were anesthetized with i.p. 0.10 mL of a solution of Ketamine hydrochloride (97 mg/kg) (Dopalen injectable Vetbrands) and xylazine (16.5 mg/kg) (Dopaser solution for injection) diluted to a concentration of 1:3 in physiological saline. Afterward, the dorsal thoracic skin on the right side was shaved and wounded. A sagittal, 1cm long, full-thickness linear incisional lesion was made with a razor blade and immediately closed with a micropore tape. Animals were euthanized with lethal anesthesia within 5 days after injury, shaved when necessary, and the skin around the lesion was dissected. The sample was cut in half perpendicular to the lesion and the separate pieces were then fixed for histology.

Histology

For histology, skin was fixed immediately in Carlson formalin in Milloning buffer (pH=7.0 for 24 h) and embedded in paraffin. Serial 5 µm transverse sections from the middle of the wound. Toluidine blue stains were performed to identify mast cells and alcian blue-safranin to assess mast cell maturation. Digital images of tissues were obtained using a BX50 Olympus microscope (Olympus, Tokyo, Japan) and an Olympus Q colour 3 camera, which was connected to a computer running the Q-capture pro software program (Q Imaging, Surrey, BC, Canada).

Morphometric analysis in light microscopy

The photographs were acquired with an optical microscope (Olympus BX51) coupled to the MOTICAM 3000 image acquisition system (2.0 M pixel) and evaluated using ImageJ software version 1.44 (Research Service Branch, US National Institutes of Health, Bethesda, MD, USA).

Five fields per slide were obtained for toluidine blue staining and for Blue-Safranin staining at 400X magnification at five days after the lesion was made. Subsequently, a semi-randomization method was used to exclude altered areas (eg. accumulation of materials, blank spaces, and areas containing large structures such as sebaceous glands and pilosebaceous follicles) and ensure the representativeness of the photographs.

Statistical analysis

Statistical analyses were performed using the GraphPad Prism 7 software (GraphPad, USA) and the statistical significance of differences between groups for mast cells density or to identify mast cell maturation stages was determined by one-way ANOVA followed by the Student-Newman-Keuls test. Values of $P \leq 0.05$ were considered significant. Data are reported as mean \pm SD.

Results

To calculate the density of the number of mast cells, toluidine blue dye (Fig. 1) was used by counting the cells at the wound edge of each mouse, as described by Marcos Garcés *et al.*²¹, obtaining the average number of mast cells per experimental group by the area in square micrometers.

On slides stained with Alcian Blue-Safranin (Fig. 2), mast cells were classified according to their maturation. This staining can distinguish between mast cell granules containing weakly sulfated mucopolysaccharides with affinity for Alcian Blue

and strongly sulfated ones with affinity for Safranin by a colour change. First, mast cell granules are formed by a large synthesis and accumulation of a heparin precursor, which has a strong affinity for Alcian Blue, followed by synthesis and accumulation of heparin N-sulfated with chymases.

Finally, histamines that are part of the granules are synthesized, with affinity for safranin²³. Based on this colour change, we have identified and distinguished, three stages of mast cell maturity in this study. These stages include immature mast cells, strongly stained blue with Alcian Blue, intermediate mast cells, stained blue and red with the mixture of alcian blue

and safranin (purple), and mature mast cells stained red with safranin (Fig. 2 A-C).

When we evaluated the maturation of these mast cells with the alcian blue-safranin dye, it was observed that the decrease in mast cell density at senescence reflects in different maturation stages, such as: immature, intermediate and mature, with a predominance of immature mast cells at all ages (Figs 2C, 3C and 4).

Young mice have more mast cells than senescent animals, with a predominance of immature and mature mast cells (Figs 2C, 3^a and 4). On the other hand, middle-aged mice have a similar number of mast cells

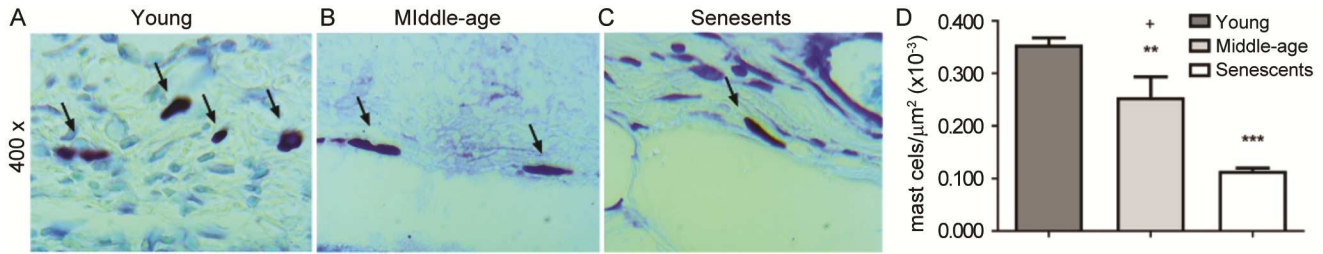


Fig. 1 — The total density of mast cells in mouse skin wounds decreases with aging. Mast cell count was performed at the edge of the incisional wound bed. Mast cells were identified as shown (black arrow) in (A) young mice; (B) middle-aged mice; and (C) senescent mice. (D) The total mast cell density per μm^2 was calculated from the number of total mast cells in five randomly selected fields, close to the wound, totaling an area of $50,000 \mu\text{m}^2$ at 400X magnification. Young mice are represented by the dark gray bar, middle-aged mice are represented by the light gray bar, and senescent mice are represented by the white bar. Slides were stained with Toluidine Blue (A, B, C). A-C: 400X. Data represent \pm SEM, $*P < 0.05$ and $***P < 0.0001$ indicates statistical differences in relation to the group of young mice, and $**P < 0.005$ indicates the statistical difference in relation to the group of middle-age mice, $n=5$.

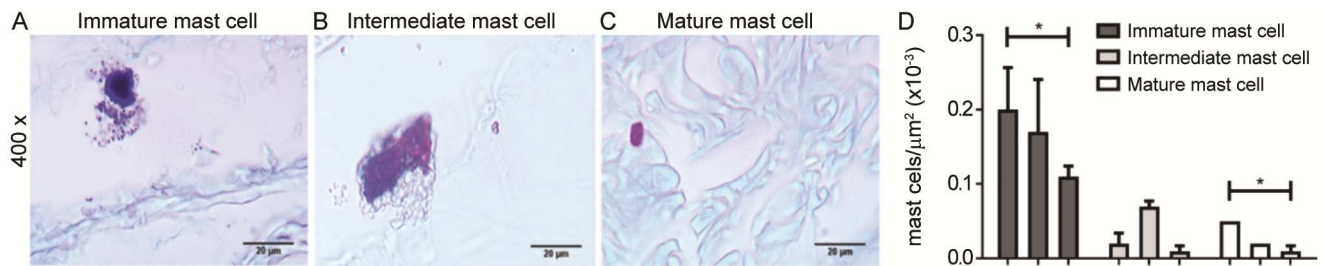


Fig. 2 — Mast cell maturation is different in aging mice skin wounds. Cells were classified as (A) immature; (B) intermediate; (C) mature stained, respectively, in blue, and purple (blue and red) and red. Scale bar: $20 \mu\text{m}$, A-C: 400X; and (D) The density of immature, intermediate and mature mast cells was calculated in five randomly selected fields, close to the wound, totaling an area of $50,000 \mu\text{m}^2$ at 400X magnification. Immature mast cell counts are represented by dark gray bars, intermediate mast cell counts were represented by light gray bars and mature mast cells are represented by white bars. Counting was performed on biopsies from the three experimental groups, young, middle-aged and senescent mice. Slides were stained with Alcian-Blue and Safranina. Data represent \pm SEM, $*P < 0.05$ indicates the statistical differences between the senescent animals and the group of young mice, $n=5$.

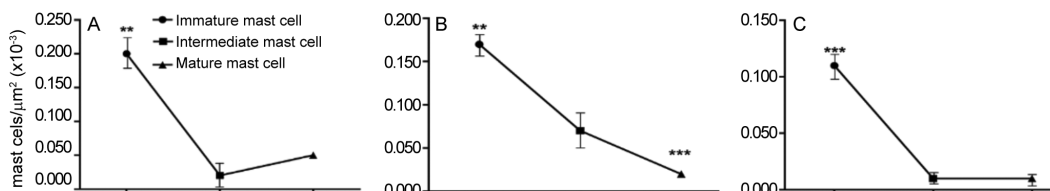


Fig. 3 — Mast cell kinetics in the skin wound of aging mice. Differences between the number of immature, intermediate and mature mast cells in (A) young mice; (B) middle-aged mice; and (C) senescent mice. $*P < 0.05$, $**P < 0.005$ and $***P < 0.0001$.

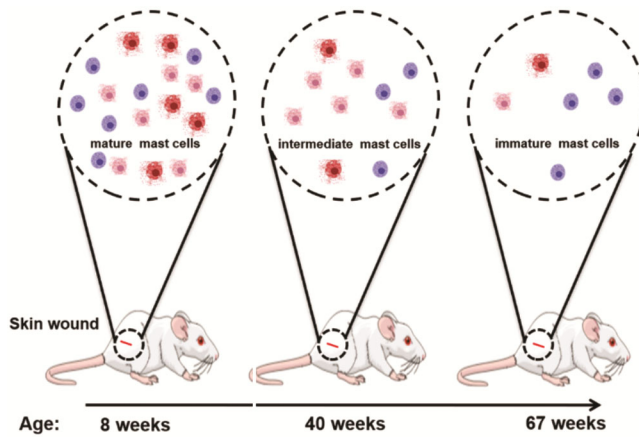


Fig. 4 — Schematic representation of the maturation of the most representative mast cells present on the edges of skin wounds in mice at different ages. Young mice have a greater number of mature mast cells, middle-aged mice have a greater number of intermediate mast cells, while senescent mice have a greater number of immature mast cells. Mast cell granules are formed by major synthesis and accumulation of a heparin precursor, followed by synthesis and accumulation of N-sulfated heparin with chymases, and finally, histamines are synthesized. The cells in the schematic drawing represent: red, mature mast cells; light red, intermediate mast cells; and blue, immature mast cells.

as young and senescent mice (Figs 2C and 3). In middle-aged mice, there is no statistically significant difference in intermediate or mature mast cells (Figs 3B and 4). Senescent animals have fewer mast cells compared to young mice (Figs 2D, 3 and 4). A decrease in mast cells is generally observed during aging in immature, intermediate and mature cells. As shown in figures 3 and 4, senescent animals have fewer immature and mature mast cells when compared to young animals. In addition, it is observed that there is a predominance of intermediate and immature mast cells in senescent animals (Figs 2C and 4).

Discussion

Resident mast cells rapidly degranulate after skin injury, releasing their preformed immunomodulatory mediators¹¹. By locating mast cells, commonly found close to blood vessels, lymphatic vessels and nerves²⁴ at the edges of wounds. It is important to highlight that the different ways of identifying mast cells in the wound bed can bring different interpretations, because several types of dyes are used to identify mast cells, such as toluidine blue, which is a metachromatic dye that binds in mast cell granules. There are works that mark chymases or tryptases present in the granules of mast cells²⁵. Another factor that differs is the age of the animals or humans, which is not the same in most

papers²⁵. Furthermore, some studies show that there are differences in the number of mast cells according to the age of the surgical or pathological scar, with an increase between 3 and 12 months after surgery^{26,27}. There is consensus that there are mast cells in all phases of skin wound repair, having in the inflammatory phase, granulation tissue and remodeling³. The study of mast cells in aging skin is still little explored and also controversial.

In this work we used toluidine blue dye that stains all mast cell granules and Alcian blue Toluidine to verify mast cell maturation²¹. Our results showed that there was a decrease in the number of these cells following aging. Corroborating our results, other studies have already shown that there is a decrease in mast cells in aged skin^{28,29}. In a study with rat skin, the mast cell count was higher in the intrauterine group and gradually decreased with age²⁸. Hart and colleagues suggest that as they age, BALB/c mice decrease the prevalence of dermal mast cells²⁹.

In addition, we observed a decrease in the maturation of mast cells at the edges of wounds with aging, indicating a decrease in cell activation and differences in the content of their granules. Some works indicate that changing the cellular context is possible to influence the expression of receptors^{30,31}, cytokines and the dominant content of mast cell granules⁵. In this way, it becomes possible for mast cells to be at different stages of maturation in the same tissue at different periods of life.

Mast cells have a role in the activation of fibroblasts leading to proliferation, activation and production of collagen, differentiation into myofibroblasts that is important in wound contraction with action, mainly, of chymases, histamines and some cytokines such as TGF- β 1, TNF^{32,33}. In this study we showed no evidence of impairment in wound closure compared to young and middle-aged animals (data not shown), but it is important that further studies are done to understand the activation of fibroblasts in general and by mast cells in senescent skin.

Several works highlight the changes in the skin that accompany aging. Among these changes are changes in the extracellular matrix such as the narrowing of the epidermis and dermis, increased water loss, and collagen and elastin fragmentation^{22,34}.

Changes in immune composition such as reduced Langerhans cells, decreased antigen-specific immunity,

and increased regulatory populations such as Foxp3+ regulatory T cells²². Finally, changes in the biomechanical properties of skin cells, such as fibroblasts in the dermis³⁵ and defects in the renewal and differentiation of epidermal keratinocytes, related to the abnormal expression of microRNAs that regulate cell death and autophagy³⁶. These modifications change the cellular context and may favor undesirable conditions, including the difficulty of repairing lesions^{20,35}. Yamashita *et al.* showed that Klotho mice, which have premature aging, had a slower rate of skin wound closure compared to control mice³⁷.

Studies have shown a positive correlation between the prevalence of mast cells and the expression of the receptor for the stem cell factor, c-Kit in these cells, suggesting a loss of mast cell function in the skin with aging²⁹. Pilkington and colleagues also showed that there is a change in the phenotype of mast cells in human skin biopsies with aging, suggesting that these cells have altered functionality and distribution. Although mast cells are more numerous in the papillary dermis, they appear to have a lower incidence of degranulation in aged skin biopsies than in young skin biopsies³⁸. Dileepan *et al.*⁵ suggest that mature mast cells express higher amounts of proteases and immature proteoglycans. However, there is evidence that β -1 tryptase is present in granules of immature, intermediate and mature mast cells, in addition, histamine at higher levels in mature mast cells, but without statistically significant difference. However, VEGF levels were higher in intermediate and mature mast cell granules³⁹.

Some works indicate that tryptase has chemotactic and mitogenic effects on dermal fibroblasts, it also stimulates the synthesis, contraction and differentiation of procollagen mRNA in myofibroblasts⁴⁰⁻⁴². Furthermore, studies suggest that histamine may increase collagen production by fibroblasts^{41,43,44} and VEGF may promote scarring in fetal wounds early in pregnancy^{45,46}. Our results suggest that over time, the changes that occur in the tissue niche may result in a decrease in the participation of mast cells in the repair process. Despite this, given that repair still takes place in aged skin and that cellular and molecular plasticity in the skin is a characteristic observed by many authors, the data from this work encourage us to suggest that there is a more active participation of other cell types, than mast cells, in the skin healing process in the elderly.

Conclusion

These data suggest that mast cell participates in the skin repair process in young and middle-aged mice. However, this activity appears to decline with aging. We also believe that other cell types must be participating more actively in the wound repair process in the aged skin, as the repair process continue to occur.

Acknowledgement

The authors thank the Pro-Rectorate of research of UFSJ for the financial support. The project was approved by the ethics committee of the Federal University of São João del Rei with the protocol CEUA 006/2015.

Conflict of Interest

Authors declare no competing interests.

References

- 1 Valent P, Akin C, Hartmann K, Nilsson G, Reiter A, Hermine O, Sotlar K, Sperr WR, Escibano L, George TI, Klun-Nelemans HC, Ustun C, Triggiani M, Brockow K, Gotlib J, Orfao A, Kovanen PT, Hadzijusufovic E, Sadovnik I, Horny HP, Arock M, Schwartz LB, Austen KF, Metcalfe DD & Galli SJ, Mast cells as a unique hematopoietic lineage and cell system: From Paul Ehrlich's visions to precision medicine concepts. *Theranostics*, 10 (2020) 10743.
- 2 Pejler G, Abrink M, Ringvall M & Wernersson S, Mast Cell Proteases. *Adv Immunol*, 95 (2007) 167.
- 3 Komi DEA, Khomtchouk K & Santa Maria PL, A Review of the Contribution of Mast Cells in Wound Healing: Involved Molecular and Cellular Mechanisms. *Clin Rev Allergy Immunol*, 58 (2020) 298.
- 4 Wernersson S & Pejler G, Mast cell secretory granules: armed for battle. *Nat Rev Immunol*, 14 (2014) 478.
- 5 Dileepan KN, Raveendran VV, Sharma R, Abraham H, Barua R, Singh V, Sharma R & Sharma M, Mast cell-mediated immune regulation in health and disease. *Front Med*, 10 (2023) 1213320.
- 6 Dwyer DF, Barrett NA & Austen KF, Expression profiling of constitutive mast cells reveals a unique identity within the immune system. *Nat Immunol*, 17 (2016) 878.
- 7 Ozgok Kangal MK & Regan JP, Wound Healing. *In StatPearls*, 1 (2023), 30571027.
- 8 Yang HW, Liu XY, Shen ZF, Yao W, Gong XB, Huang HX & Ding GH, An investigation of the distribution and location of mast cells affected by the stiffness of substrates as a mechanical niche. *Int J Biol Sci*, 14 (2018) 1142.
- 9 Sivaraj D, Chen K, Chattopadhyay A, Henn D, Wu W, Noishiki C, Magbual NJ, Mittal S, Mermin-Bunnell AM, Bonham CA, Trotsyuk AA, Barrera JA, Padmanabhan J, Januszzyk M & Gurtner GC, Hydrogel Scaffolds to Deliver Cell Therapies for Wound Healing. *Front Bioeng Biotechnol*, 9 (2021) 660145.
- 10 Dempsey LA, Choreographing tissue repair. *Nat Immunol*, 24 (2023) 1051.
- 11 Trautmann A, Toksoy A, Engelhardt E, Bröcker EB & Gillitzer R, Mast cell involvement in normal human skin wound healing:

- expression of monocyte chemoattractant protein-1 is correlated with recruitment of mast cells which synthesize interleukin-4 *in vivo*. *J Pathol*, 190 (2000) 100.
- 12 Chen L, Schrementi ME, Ranzer MJ, Wilgus TA & DiPietro LA, Blockade of Mast Cell Activation Reduces Cutaneous Scar Formation. *PLoS ONE*, 9 (2014) 85226.
 - 13 Hiromatsu Y & Toda S, Mast cells and angiogenesis. *Microsc Res Tech*, 60 (2003) 64.
 - 14 Wulff BC & Wilgus TA, Mast cell activity in the healing wound: more than meets the eye? *Exp Dermatol*, 22 (2013) 507.
 - 15 Bagher M, Larsson-Callert AK, Rosmark O, Hallgren O, Bjerner L & Westergren-Thorsson G, Mast cells and mast cell tryptase enhance migration of human lung fibroblasts through protease-activated receptor 2. *Cell Commun Signal*, 16 (2018) 59.
 - 16 Antsiferova M, Martin C, Huber M, Feyerabend TB, Förster A, Hartmann K, Rodewald HR, Hohl D & Werner S, Mast Cells Are Dispensable for Normal and Activin-Promoted Wound Healing and Skin Carcinogenesis. *J Immunol*, 191 (2013) 6147.
 - 17 Willenborg S, Eckes B, Brinckmann J, Krieg T, Waisman A, Hartmann K, Roers A & Eming AS, Genetic Ablation of Mast Cells Redefines the Role of Mast Cells in Skin Wound Healing and Bleomycin-Induced Fibrosis. *J Invest Dermatol*, 134 (2014) 2005.
 - 18 Tellechea A, Leal EC, Kafanas A, Auster ME, Kuchibhotla S, Ostrovsky Y, Tecilazich F, Baltzis D, Zheng Y, Carvalho E, Zabolotny JM, Weng Z, Petra A, Patel A, Panagiotidou S, Pradhan-Nabzdyk L, Theoharides TC & Veves A, Mast Cells Regulate Wound Healing in Diabetes. *Diabetes*, 65 (2016) 2006.
 - 19 Dong J, Chen L, Zhang Y, Jayaswal N, Mezghani I, Zhang W & Veves A, Mast Cells in Diabetes and Diabetic Wound Healing. *Adv Ther*, 37 (2020) 4519.
 - 20 Guimaraes GR, Almeida PP, de Oliveira Santos L, Rodrigues LP, de Carvalho JL & Boroni M, Hallmarks of Aging in Macrophages: Consequences to Skin Inflammation. *Cells*, 10 (2021) 1323.
 - 21 Marcos-Garcés V, Molina Aguilar P, Bea Serrano C, García Bustos V, Benavent Seguí J, Ferrández Izquierdo A & Ruiz-Sauri A, Age-related dermal collagen changes during development, maturation and ageing - a morphometric and comparative study. *J Anat*, 225 (2014) 98.
 - 22 Chambers ES & Vukmanovic-Stejic M, Skin barrier immunity and ageing. *Immunology*, 160 (2020) 116.
 - 23 Combs JW, Lagunoff D & Benditt EP, Differentiation and proliferation of embryonic mast cells of the rat. *J Cell Biol*, 25 (1965) 577.
 - 24 Fernandes A, Rodrigues PM, Pintado M & Tavaría FK, A systematic review of natural products for skin applications: Targeting inflammation, wound healing, and photo-ageing. *Phytomedicine*, 115 (2023) 154824.
 - 25 Wilgus TA, Inflammation as an orchestrator of cutaneous scar formation: a review of the literature. *Plast Aesthet Res*, 7 (2020) 54.
 - 26 Beer TW, Baldwin H, West L, Gallagher PJ & Wright DH, Mast cells in pathological and surgical scars. *Br J Ophthalmol*, 6 (1998) 691.
 - 27 Niessen FB, Schalkwijk J, Vos H & Timens W, Hypertrophic scar formation is associated with an increased number of epidermal Langerhans cells. *J Pathol*, 1 (2004) 121.
 - 28 Kazanci A, Kurus M & Atasever A, Analyses of changes on skin by aging. *Skin Res Technol*, 23 (2017) 48.
 - 29 Hart PH, Grimbaldeston MA, Hosszu EK, Swift GJ, Noonan FP & Finlay-Jones JJ, Age-related changes in dermal mast cell prevalence in BALB/c mice: functional importance and correlation with dermal mast cell expression of Kit. *Immunology*, 98 (1999) 352.
 - 30 Weller CL, Collington SJ, Brown JK, Miller HR, Al-Kashi A, Clark P, Jose PJ, Hartnell A & Williams TJ, Leukotriene B₄, an activation product of mast cells, is a chemoattractant for their progenitors. *J Exp Med*, 201 (2005) 1961.
 - 31 Al-Azzam N, Kondeti V, Duah E, Gombedza F, Thodeti CK & Paruchuri S, Modulation of Mast Cell Proliferative and Inflammatory Responses by Leukotriene D₄ and Stem Cell Factor Signaling Interactions. *J Cell Physiol*, 230 (2015) 595.
 - 32 Dong X, Zhang C, Ma S & Wen H, High concentrations of mast cell chymase facilitate the transduction of the transforming growth factor- β 1/Smads signaling pathway in skin fibroblasts. *Exp Ther Med*, 9 (2015) 955.
 - 33 Moretti L, Stalfort J, Barker TH & Abeyayehu D, The interplay of fibroblasts, the extracellular matrix, and inflammation in scar formation. *J Biol Chem*, 298 (2022) 101530.
 - 34 Toutfaire M, Bauwens E & Debacq-Chainiaux F, The impact of cellular senescence in skin ageing: A notion of mosaic and therapeutic strategies. *Biochem Pharmacol*, 142 (2017) 1.
 - 35 Boismal F, Serron K, Dobos G, Zuelgaray E, Bensussan A & Michel L, Vieillissement cutané. *Med Sci*, 36 (2020) 1163.
 - 36 Rorteau J, Chevalier FP, Fromy B & Lamartine J, Vieillissement et intégrité de la peau. *Med Sci*, 36 (2020) 1155.
 - 37 Yamashita K, Yotsuyanagi T, Yamauchi M & Young DM, Klotho Mice. *PRS: Global Open*, 2 (2014) 101.
 - 38 Pilkington SM, Barron MJ, Watson REB, Griffiths CEM & Bulfone-Paus S, Aged human skin accumulates mast cells with altered functionality that localize to macrophages and vasoactive intestinal peptide-positive nerve fibres. *Br J Dermatol*, 180 (2019) 849.
 - 39 Wulff BC, Parent AE, Meleski MA, DiPietro LA, Schrementi ME & Wilgus TA, Mast Cells Contribute to Scar Formation during Fetal Wound Healing. *J Invest Dermatol*, 132 (2012) 458.
 - 40 Albrecht M, Frungieri MB, Kunz L, Rämisch R, Meineke V, Köhn FM & Mayerhofer A, Divergent effects of the major mast cell products histamine, tryptase and TNF-alpha on human fibroblast behaviour. *Cell Mol Life Sci*, 62 (2005) 2867.
 - 41 Gailit J, Marchese MJ, Kew RR & Gruber BL, The Differentiation and Function of Myofibroblasts is Regulated by Mast Cell Mediators. *J Invest Dermatol*, 117 (2001) 1113.
 - 42 Gruber BL, Kew RR, Jelaska A, Marchese MJ, Garlick J, Ren S, Schwartz LB & Korn JH, Human mast cells activate fibroblasts: tryptase is a fibrogenic factor stimulating collagen messenger ribonucleic acid synthesis and fibroblast chemotaxis. *J Immunol*, 158 (1997) 2310.
 - 43 Hatamochi A, Fujiwara K & Ueki H, Effects of histamine on collagen synthesis by cultured fibroblasts derived from guinea pig skin. *Arch Dermatol Res*, 277 (1984) 60.
 - 44 Kupietzky A & Levi-Schaffer F, The role of mast cell-derived histamine in the closure of an *in vitro* wound. *Inflamm Res*, 45 (1996) 176.
 - 45 Liechty KW, Adzick NS & Crombleholme TM, Diminished interleukin 6 (IL-6) production during scarless human fetal wound repair. *Cytokine*, 12 (2000) 671.
 - 46 Wilgus TA, Ferreira AM, Oberyszyn TM, Bergdall VK & DiPietro LA, Regulation of scar formation by vascular endothelial growth factor. *Lab Invest*, 88 (2008) 579.