



## ANIMAL SCIENCE

# Effects of the use of synthetic astaxanthin in the feeding of *Lophiosilurus alexandri*, a neotropical siluriform fish

DANIEL P. DA COSTA, MÁRCIO JOSÉ S. SILVA, RICARDO MARCELO GERALDI, JOÃO PAULO LORENZINI, CRISTIANO C. MATTIOLI, AFONSO DE LIGUORI OLIVEIRA, RONALD K. LUZ & KLEBER CAMPOS MIRANDA-FILHO

**Abstract:** Aiming to test the capacity of retention of carotenoids in tissues, *Lophiosilurus alexandri* juveniles were fed diets containing 0, 25, 50, 100, 200, and 400 mg/kg of synthetic astaxanthin for 62 days. The inclusion of astaxanthin did not result in significant differences in growth, weight gain, apparent feed conversion, and feed efficiency of the fish. Blood biochemistry and liver histology did not change with the different treatments. At the level of 100 mg/kg of inclusion, there were the highest levels of carotenoids in the blood, and muscle and the smallest difference between the muscle x integument ratio.

**Key words:** additive, carotenoid, catfish, fish feed, pacamã, pigmentation, supplement.

## INTRODUCTION

Siluriform fish, also known as catfish, include species that mostly have great market acceptance, being widely cultivated and commercialized. Some genera such as *Pseudoplatystoma*, *Ictalurus*, *Rhamdia*, and *Clarias* already have a defined technological package and have a consolidated production chain (Liraço et al. 2011, Liu et al. 2012, Charo-Karisa et al. 2013, Martinelli et al. 2013). In other species such as the pacamã *Lophiosilurus alexandri*, the characteristics related to its potential as viable fish for aquaculture production are still being studied (Costa et al. 2014, Silva et al. 2018). As it is a species widely consumed by the local population of the São Francisco River (Brazil), a certain concern already exists regarding natural stocks. As a palliative action, the aquaculture activity is already working with research actions aimed at the production of *L. alexandri* in

captivity with a view to restocking and consuming the species.

A common characteristic of fillets of cultivated Siluriformes is naturally yellowish pigmentation (Bicudo et al. 2012, Hu et al. 2013). Which can give a positive aspect to the final product and also differ the product from similar ones. These fish can store several carotenoids that give a natural appearance to your skin and muscle (Tsushima et al. 2002, Maoka & Akimoto 2011, Liu et al. 2012, Costa & Miranda-Filho 2020). However, there is a need to research a way to use additives in the feed of these fish to provide an efficient and attractive pigmentation that stimulates the consumer to give preference to these species.

Synthetic astaxanthin is the most widely used pigment in aquaculture worldwide (Breitenbach et al. 2016, Dananjaya et al. 2017) and has an efficiency of use concerning natural sources of precursor carotenoids for several

aquaculture species (Göcer et al. 2006, Ingle de la Mora et al. 2006, Baron et al. 2008, Aguirre-Hinojosa et al. 2012, Costa et al. 2021a, b). In *L. alexandri* and other South American siluriforms, the efficiency of the use of synthetic astaxanthin has not yet been determined to promote increased pigmentation of muscles and skin. Additionally, it is not known whether the use of this substance could have any effect on the performance of this fish.

In this work, we aim to elucidate the use of synthetic astaxanthin in blood biochemistry, productive performance, liver integrity, and efficiency in the accumulation of the substance in the fillet and skin of *L. alexandri* juveniles.

## MATERIAL AND METHODS

### Experimental diets

A commercial feed for carnivorous fish from 2 to 4 mm in diameter (Guabi® Animal Nutrition and Health, Sales Oliveira, SP, Brazil) containing 90% dry matter, 42% crude protein, 11% stereo layer, 3% crude fiber, and 14% mineral matter in dry weight, having 16 mg/kg of total carotenoids from its basal ingredients, was used as a control diet and base of the other diets, in which 10% synthetic astaxanthin pigment, Carophyll® Pink (DSM Nutritional Products Ltd, Heerlen, Netherlands) in the proportions of 25, 50, 100, 200, and 400 mg/kg of astaxanthin in the feed. The pigment was dissolved in 70% alcohol and sprayed on the feed which was subsequently dehydrated at 30°C for 24 hours in a dark environment.

### Ethical note

This study was submitted for approval by the UFMG Animal Use Ethics Committee and approved through CEUA 202/2018 registration.

### Fish and experimental conditions

The pigmentation experiment was designed with a completely randomized design. Six fish of medium weight 17.66 g were used per repetition in 6 treatments with 4 repetitions in each of them in 12 L tanks with a 48 L/h recirculation system, with individual auxiliary aeration and filtering using an aerated moving bed system, with 15 x 30 mm nano media and density 192 kg/m<sup>3</sup> type MBBR (Nanoplastic®, São Paulo, SP, Brazil) in a single 250 L filter, 50% of which is covered with nano media. The acclimatization period was 7 days and the study was carried out for 62 days and one day of fasting at the end. The food was supplied twice a day in the proportion of 5% of the initial average live weight of the fish daily. Weighing was done on a precision scale 0.01 g BL series, (Shimadzu® do Brasil, Barueri, SP, Brazil) and the measurements were made with a 0.1 mm precision digital caliper.

The parameters of water quality, temperature, pH and salinity were measured with a Combo EC & pH multiparameter probe and dissolved oxygen (OD) by the HI9146 oximeter (Hanna Instruments®, Woonsocket, USA). Total ammonia (TA-N), nitrite (NO<sub>2</sub><sup>-</sup>-N), nitrate (NO<sub>3</sub><sup>-</sup>-N) and phosphate (PO<sub>4</sub><sup>-3</sup>-P), were determined according to the methodology described by UNESCO (1983). The measured water parameters were temperature = 27.48 ± 0.97°C, dissolved oxygen = 5.59 ± 0.52 mg/L, oxygen saturation = 85.04 ± 3.96%, pH = 6.91 ± 0.42, salinity = 0.16 ± 0.03‰, and total ammonia = 0.23 ± 0.11 mg/L.

### Zootechnical Indexes

The calculation of zootechnical indexes was made based on the following equations:

- Weight gain (WG) - is the final weight of the animal minus the initial weight of the animal. This calculation is obtained by the following formula (1):

$$WG = \text{final weight [g]} - \text{initial weight [g]}$$

- Length gain (LG) is the animal's final length minus the initial length. This calculation is obtained by the following formula (2):

$$LG = \text{final length [cm]} - \text{initial length [cm]}$$

- Gain in width (GW) is the final width of the animal minus the initial width. This calculation is made with the following formula (3):

$$GW = \text{final width [cm]} - \text{initial width [cm]}$$

- Apparent feed conversion (AFC) - equivalent to the amount of feed needed for the animal to gain 1 kg of live weight (4):

$$AFC = \frac{\text{feed consumed [g]}}{\text{final weight [g]} - \text{initial weight [g]}}$$

- Feed efficiency (FE) - constitutes the average weight gain per animal in the group, divided by the average feed consumption per individual. It demonstrates the efficiency that the animal had to convert the feed consumed into live weight (5):

$$FE (\%) = \frac{\text{mass gain [g]}}{\text{amount of feed ingested [g]}} \times 100$$

- Carotenoid retention rate% (CRR) in the fillet was measured using equation (6) described by Foss et al. (1984):

$$CRR (\%) = \frac{\frac{\text{mg}}{\text{kg}} \text{ of carotenoids in the fillet} \times (100)}{\frac{\text{mg}}{\text{kg}} \text{ of carotenoids in the diet}}$$

- Relative proportion of integument carotenoids and muscle (RPC) given by equation (7):

$$RPC = \frac{\frac{\text{mg}}{\text{kg}} \text{ carotenoids in the integument}}{\frac{\text{mg}}{\text{kg}} \text{ carotenoids in the muscle}}$$

### Blood Analysis

At the end of the experiment, *L. alexandri* juveniles were deprived of food for 24 h, and blood was sampled from the caudal vein using heparinized needles in 1 mL syringes. Glucose was measured with a portable glucometer (Bioeasy BioCheck, TD4225, Diagnostica Ltda, MG, Brazil) and hematocrit was determined by the microhematocrit method for 15 min at 10,000 rpm (or  $8944 \times g$ ), using Microspin-Spin1000; Micros-spin (Mikro) (Laborline, Barueri, SP, Brazil). Ethylenediaminetetraacetic acid (EDTA) was added to the remaining blood at a rate of 10% and centrifuged (75 g = 5 min and 679 g = 5 min) for plasma collection. Plasma protein was determined by a standard refractometer. Cholesterol and triglycerides were measured on an automatic spectrophotometer (Roche Cobas Mira Plus, Diagnostic Systems, Ramsey, MN, USA) using commercial kits (Synermed; Synermed-Westfield, IN, USA). Commercial kits (Synermed®) were used for the analysis of alanine aminotransferase (ALT), aspartate aminotransferase (AST), alkaline phosphatase (ALP). After blood collection, the fish were sacrificed by section of the cervical spine using a slide.

### Analysis of total carotenoids

The fish tissues were macerated in 96°GL ethanol and analyzed using a Libra S22 spectrophotometer (Biochrom®, Cambridge, UK) at a wavelength of 452 nm absorbance. The calculation was done by the Rodriguez-Amaya

(2001) and Rodriguez-Amaya & Kimura (2004) methodology, following equation (8), namely:

$$[\text{mg pigment} / \text{kg}] = \frac{\text{ABS} \times \text{DF} \times \text{V}}{\text{AC} \times [\text{g}]}$$

Where:

ABS = Absorbance of the pigment in the ethanol solution [nm]

DF = Dilution factor

V = Volume of the solution

AC = Absorption coefficient E 1% 1 cm of the pigment in ethanol

[g] = grams of sample used

### Histological analyzes

After blood collection and euthanasia, the liver of four fish per treatment was fixed in Bouin's solution for 12 h and then transferred to 70% ethanol for later histological analysis and stained with hematoxylin and eosin. The slides were examined and photomicrographs were performed with a light microscope for histopathological examination. The observed cells were classified according to Bernet et al. (1999) in three factors: (1) minimal pathological importance, where the damage is reversible after the end of the exposure to the toxic agent; (2) moderate pathological importance, in which the lesion is reversible in some cases after the end of the exposure; and (3) severe pathological importance, in which the lesion is typically irreversible and leads to the partial or total loss of organ function. All slides were assessed using a scale ranging from: 0 = unchanged, 2 = mild occurrence, 4 = moderate occurrence and 6 = serious occurrence.

### Statistical Analysis

To test the working hypothesis, a Unifactorial Analysis of Variance (One-Way ANOVA), Model I, and significance level  $\alpha = 0.05$  was used (Zar 2010). In cases where the assumptions were not

met, the transformation of the data through Log (X + 1) was applied. When the results were significant after the application of ANOVA, the assumptions of Normality of Distribution and Homogeneity of Variances were verified, through the application of the Shapiro-Wilk (W) and Levene tests, respectively, both with the level of significance  $\alpha = 0.05$  (Zar 2010).

To identify significant differences among treatments (pigmentation), the Tukey contrast test (HSD) was applied, with a significance level of  $\alpha = 0.05$  (Zar 2010). In situations where the tests for the transformed data rejected the assumptions of ANOVA, an alternative solution was the use of an ANOVA by Stations (ANOVA by Ranks), through the application of the Kruskal-Wallis test (Zar 2010). The tests were performed with the statistical program Infostat® version 2017 according to instructions in the software manual (Casanoves et al. 2012).

## RESULTS

### Zootechnical indexes

The Zootechnical indices did not have significant differences ( $P > 0.05$ ) regarding the treatments used (Table I).

### Blood tests

Among the blood parameters observed, only the AST was shown to be influenced by the treatments ( $P < 0.05$ ), being higher in the treatment with the addition of 400 mg/kg of astaxanthin, compared to the control and the treatment of 25 mg/kg. The other blood variables did not show significant differences ( $P > 0.05$ ) (Table II).

### Analysis of total carotenoids

The concentration of total carotenoids in the blood plasma (Fig. 1) was shown to be higher in the treatment with 100 mg/kg of inclusion of

**Table I. Zootechnical index in juvenile *L. alexandri* feed 62 days by diets with different level of synthetic astaxanthin.**

Variables	Astaxanthin added in feed (mg/kg)							
		0	25	50	100	200	400	Total
Initial Weight (g)	mean	19.17	18.09	16.24	17.24	16.81	17.80	17.56
	± SD	3.59	3.81	1.35	0.79	1.42	1.21	2.30
Final weight (g)	mean	36.47	36.43	32.54	34.93	32.95	37.98	35.22
	± SD	4.06	7.58	2.17	0.85	3.99	6.66	4.71
Weight gain (g)	mean	17.30	18.35	16.30	17.70	16.15	20.18	17.66
	± SD	2.50	3.85	1.51	1.50	2.71	6.30	3.38
Initial length (cm)	mean	11.81	11.80	11.49	11.63	11.36	11.66	11.63
	± SD	0.29	0.50	0.28	0.10	0.54	0.26	0.36
Final length (cm)	mean	14.42	14.73	14.12	14.33	14.01	14.42	14.34
	± SD	0.58	0.51	0.66	0.55	0.91	0.28	0.59
Length gain (cm)	mean	2.61	2.93	2.63	2.70	2.65	2.75	2.71
	± SD	0.45	0.33	0.44	0.58	0.84	0.07	0.46
Initial width (cm)	mean	1.81	1.88	1.70	1.82	1.68	1.85	1.79
	± SD	0.16	0.35	0.25	0.29	0.09	0.37	0.25
Final width (cm)	mean	2.50	2.60	2.48	2.49	2.43	2.24	2.46
	± SD	0.18	0.26	0.13	0.09	0.09	0.12	0.18
Width gain (cm)	mean	0.69	0.72	0.78	0.66	0.75	0.39	0.67
	± SD	0.30	0.13	0.20	0.35	0.13	0.43	0.28
AFC	mean	1.63	1.51	1.57	1.57	1.66	1.38	1.55
	± SD	0.09	0.11	0.18	0.06	0.13	0.04	0.15
FE (%)	mean	61.64	66.47	59.24	63.79	60.61	72.73	64.07
	± SD	3.62	4.97	5.82	2.35	4.57	2.14	5.88

AFC = Apparent Feed Conversion, FE = Feed Efficiency. Different letters on the same line demonstrate significant differences by Tukey's test ( $P < 0.05$ ).

astaxanthin concerning the control groups and 25 mg/kg ( $P < 0.05$ ).

As for the tegument pigmentation (Fig. 2), the treatments with 100, 200, and 400 mg/kg of astaxanthin obtained significantly superior results in comparison to the control ( $P < 0.05$ ). The treatment with 400 mg/kg is also higher than the treatments with 25 and 50 mg/kg ( $P < 0.05$ ).

In Figure 3a, it is possible to observe the greater muscle accumulation of total carotenoids in the treatment with the addition of 100 mg/kg of astaxanthin ( $P < 0.05$ ), in relation to the other

treatments with the exception of the 200 mg/kg treatment, which showed similarity ( $P > 0.05$ ).

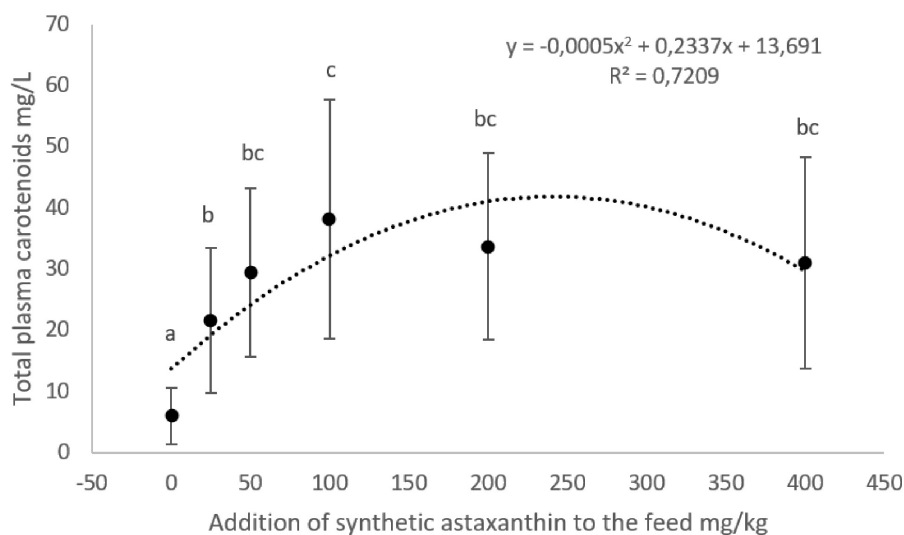
In Table III, we can see that the correlations between carotenoids in muscle x blood plasma ( $P = 0.2267$ ) were not significant. Carotenoids in blood plasma x integument ( $P = 0.0002$ ) and carotenoids in integument x muscle ( $P = 0.0046$ ) showed a positive correlation with each other.

Muscle retention of carotenoids (Fig. 3b) has been shown to suffer a gradual drop in the percentage of utilization of carotenoids added to food as the level of inclusion increased ( $P < 0.05$ ).

**Table II. Blood parameters in juvenile *L. alexandri* feed by diets with different levels of synthetic astaxanthin.**

Variables		Astaxanthin added in feed (mg/kg)						Total
		0	25	50	100	200	400	
Alanine aminotransferase	mean	2.15	2.33	2.65	2.64	3.83	2.08	2.61
	± SD	0.26	0.98	0.48	0.75	1.52	0.88	1.00
Aspartate aminotransferase	mean	68.23 <sup>b</sup>	76.16 <sup>b</sup>	59.38 <sup>ab</sup>	46.53 <sup>ab</sup>	55.46 <sup>ab</sup>	27.23 <sup>a</sup>	55.50
	± SD	17.47	11.31	30.51	12.29	7.51	15.92	22.27
Glucose	mean	54.81	45.77	40.03	36.93	34.18	46.44	43.03
	± SD	20.90	16.95	10.59	11.06	10.00	22.24	15.87
Alkaline phosphatase	mean	8.44	6.52	9.73	5.72	8.59	8.20	7.86
	± SD	2.39	3.57	2.57	1.03	2.86	2.12	2.64
Cholesterol	mean	72.75	67.76	73.53	70.72	80.54	83.54	74.80
	± SD	7.99	14.25	11.58	11.68	6.97	13.93	11.55
Triglycerides	mean	245.51	243.35	230.15	203.45	261.67	263.75	241.32
	± SD	14.72	50.38	51.24	24.28	37.18	45.56	40.79
Total plasmatic protein	mean	2.12	2.15	2.14	2.20	2.32	2.44	2.23
	± SD	0.13	0.33	0.26	0.19	0.03	0.45	0.26
Hemoglobin	mean	6.21	6.12	6.94	5.99	6.31	5.74	6.22
	± SD	0.52	0.27	0.74	0.61	0.55	0.19	0.59
Hematocrit	mean	22.81	22.44	19.38	22.06	20.75	22.06	21.58
	± SD	1.96	2.18	2.95	1.77	0.54	0.83	2.06

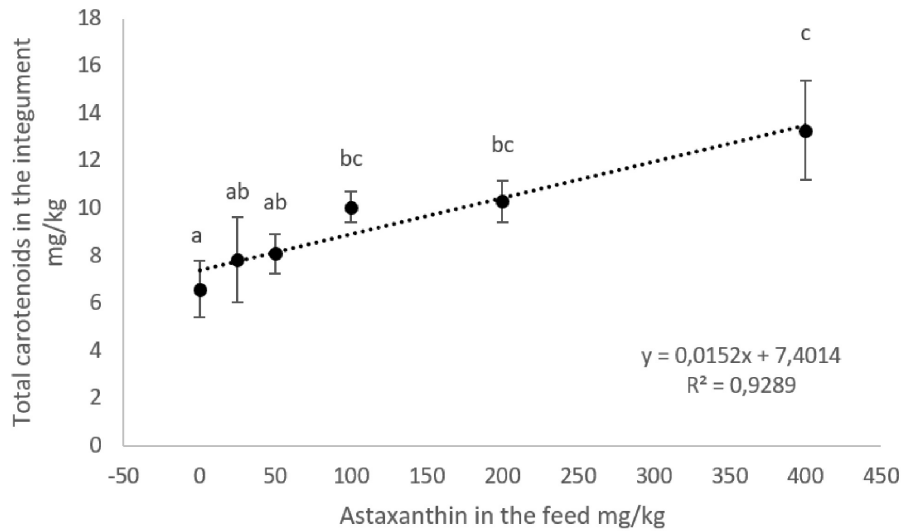
Different letters on the same line demonstrate significant differences by Tukey's test (P<0.05).



**Figure 1. Total carotenoids in the blood plasma of *L. alexandri* fed a diet containing different levels of inclusion of synthetic astaxanthin. Different letters above the data show a significant difference (P<0.05) by the Kruskal - Wallis nonparametric test.**

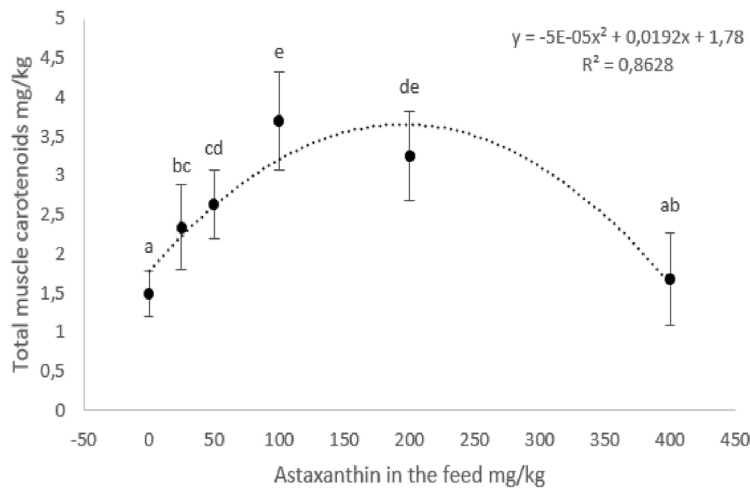
The treatment with the inclusion of 100 mg/kg of astaxanthin was the one that obtained the least disproportion among the carotenoids accumulated in the integument and the muscle

(Fig. 4) concerning the control a to the treatment of 400 mg/kg, which obtained the disproportion for all groups with added pigment (P<0.05). In this case, and the control group, there was a greater



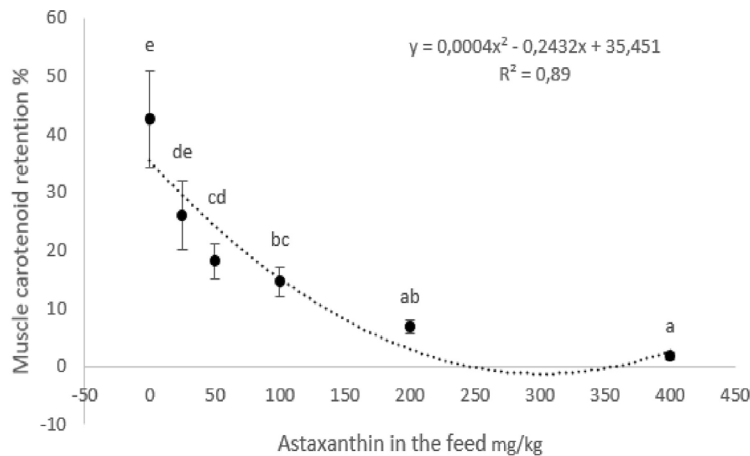
**Figure 2.** Total carotenoids in the integument of *L. alexandri* fed with ration containing different levels of inclusion of synthetic astaxanthin. Different letters show a significant difference ( $P < 0.05$ ) by the Kruskal - Wallis nonparametric test.

**a**



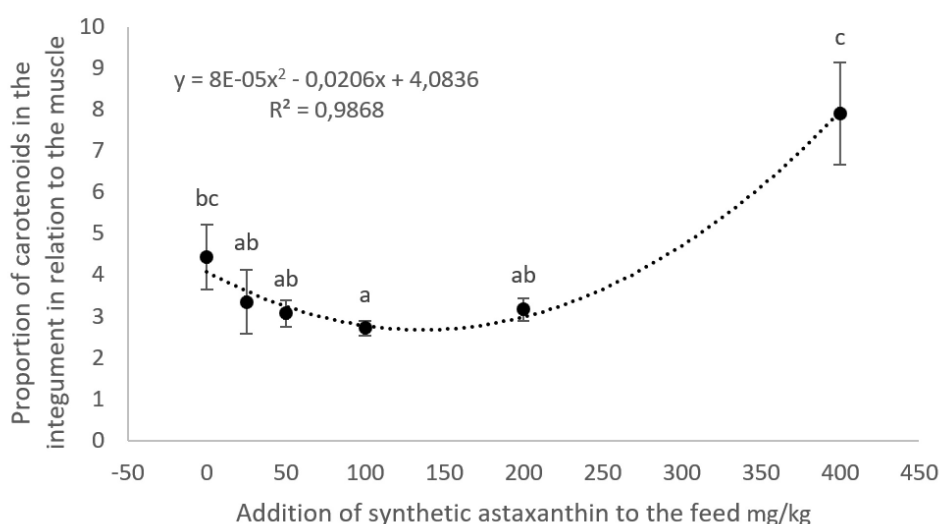
**Figure 3. a -** Total carotenoids in the muscle of *L. alexandri* fed with food containing different levels of inclusion of synthetic astaxanthin. **b -** Retention of total carotenoids (%) in the muscle of *L. alexandri* fed with food containing different levels of inclusion of synthetic astaxanthin. Different letters above the data show a significant difference ( $P < 0.05$ ) by the Kruskal - Wallis nonparametric test.

**b**



**Table III. Correlation between tecidual and plasma levels of total carotenoid content in *L. alexandri* analyzed by Spearman correlation (*r*).**

Material	R <sup>2</sup>	P
Muscle x plasma	0.25	0.2267
Plasma x tegument	0.70	0.0002
Tegument x muscle	0.56	0.0046

**Figure 4. Proportion of total carotenoids of the integument in relation to the muscle (x:y) in *L. alexandri* fed with ration containing different levels of inclusion of synthetic astaxanthin. Different letters show a significant difference ( $P < 0.05$ ) by the Kruskal-Wallis nonparametric test.**

accumulation of carotenoids in the skin than in the muscle compared to the other treatments.

### Histological analyzes

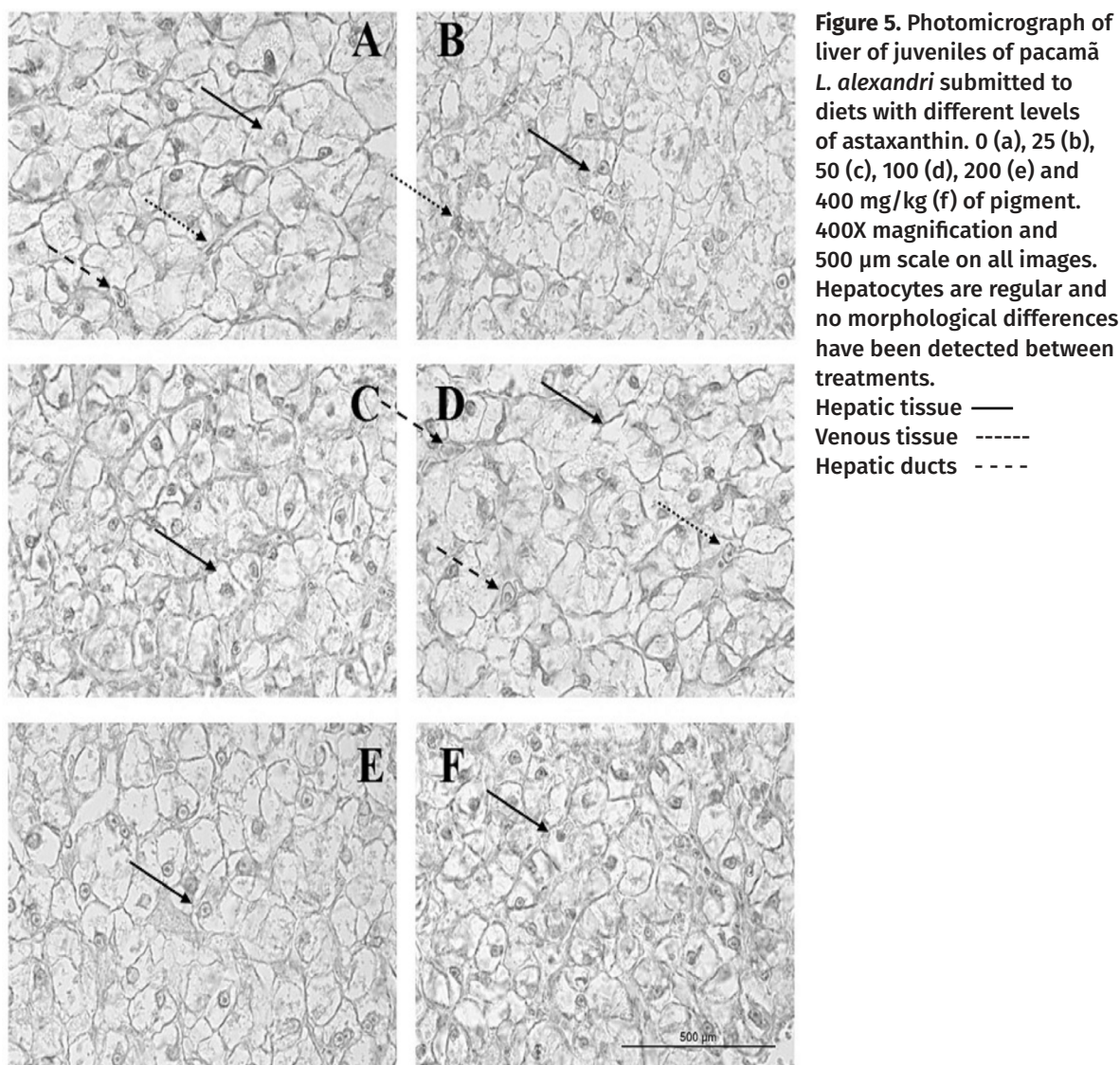
The images of hepatic tissue, hepatic venous tissue, and hepatic ducts showed no morphological or histopathological differences between treatments. All carotenoid concentrations were similar, becoming impossible to make a scoring assignment (Fig. 5).

## DISCUSSION

Astaxanthin presented in the diet promotes several benefits for fish such as increased resistance to stress and increased immunity in yellow catfish *Pelteobagrus fulvidraco* (Liu et al. 2016); increased growth, weight gain, and

coloration in wells catfish *Silurus glanis* (Začková et al. 2011); increase in egg fertility and survival of *Gadus morhua* cod larvae (Hansen et al. 2014); increase in the size of juveniles of long snout seahorse *Hippocampus guttulatus* (Palma et al. 2016). In the present study, zootechnical indices were not altered by the inclusion of astaxanthin in the diet as observed in juveniles of other fish species such as channel catfish, *Ictalurus punctatus* (Li et al. 2007), large yellow croaker *Larimichthys croceus* (Yi et al. 2014), discus fish *Symphysodon* spp. (Song et al. 2016) characins, *Hyphessobrycon callistus* (Wang et al. 2006), and Australian snapper *Pagrus auratus* (Doolan et al. 2009).

The addition of natural or synthetic astaxanthin promotes liver integrity in fish and this can be assessed through the concentration of liver enzymes in the blood (Nakano et al. 1995).



Page et al. (2005) found no significant differences between AST levels in the blood plasma of rainbow trout *Oncorhynchus mykiss* fed with 100 mg/kg of astaxanthin. Sheikhzadeh et al. (2012) worked with the same species and had the same result up to 3 g/kg of the addition of green algae *Haematococcus pluvialis* included in the feed as a source of astaxanthin. However, by increasing the amount to 10 g/kg, they obtained lower levels of this enzyme in the blood of this fish. Which suggests an improvement in the liver condition by using this food supplement. The same happened in the present study concerning the

control and 25 mg/kg when the highest pigment concentration (400 mg/kg) was used. Although the ALT enzyme did not differ in our work, it can also indicate the liver condition of the fish, being influenced in some cases by the pigment concentrations in the diet of fish subjected to high-temperature stress as recorded in pufferfish *Takifugu obscurus* (Cheng et al. 2017) or a high concentration of ammonia in tetra-serpae *Hyphessobrycon eques* (Pan et al. 2011). In the case of oxygen availability in water, both in normoxia and hypoxia, ALT concentration was lower with the supplementation of astaxanthin

in the Tetra-Blood *H. callistus* diet (Pan et al. 2010).

In the case of ALP, in some cases its concentration may increase depending on the amount of astaxanthin in the diet (Řehulka 2000), suggesting that astaxanthin could increase serum levels of ALP, and neutralize the impact of environmental stressors (Cheng et al. 2017). But this was not seen in the present study. In addition, the increase in astaxanthin levels did not influence the levels of triglycerides and cholesterol in the blood of pufferfish (Cheng et al. 2017) and cholesterol in Atlantic salmon *O. mykiss* (Chimsung et al. 2013), similar to the results obtained with *L. alexandri*. The hemoglobin, hematocrit, and plasma protein values did not change in the blood of common carp *Cyprinus carpio* (Jagruthi et al. 2014). In the study by Li et al. (2014), with *L. crocea*, the blood glucose index decreased as the astaxanthin increased, and the cholesterol and triglyceride data had a response significantly proportional to the glucose level in the treatments. However, in the present study, despite the averages showing the same trend until the addition of 200 mg/kg, it was not possible to observe this difference due to the heterogeneity of the data with a high standard deviation ( $P > 0.05$ ). But, as in the previous case, the response was similar in the three indicators, with no significant change in any of them in the current case.

The amount of carotenoid in the blood can be influenced by its concentration in the diet, as observed with rainbow trout fed with various levels of cyanobacteria *Spirulina* as a source of pigments (Teimouri & Amirkolaie 2013). The presence of astaxanthin or beta-carotene in the diet also significantly increased the presence of pigment in the blood of tetra-serpae *Hyphessobrycon eques* (Pan et al. 2011). In the case of *L. alexandri*, an increase in the rate of carotenoids in the blood was observed

up to the inclusion of 100 mg/kg, after this concentration, the levels were lower, probably due to the physiological limitation of the animal to assimilate/transport this pigment in the blood when in large amounts in the food due to the action of fish enzyme inhibitors as suggested by Tyssandier et al. (2002). Or the dietary amount of carotenoid transporters in the blood such as triglyceride, cholesterol, cholesteryl ester, and phospholipid associated with lipoproteins, which can limit the amount of circulating carotenoids in the plasma (Chimsung et al. 2013).

Song et al. (2016) observed that discus fish *Symphysodon* spp. increased skin pigmentation with the inclusion of astaxanthin in the diet up to 200 mg/kg of feed. However, with higher values (300 and 400 mg/kg), the authors observed the same accumulation values as in the 200 mg/kg treatment. In the present study, the concentration of carotenoid pigments in the integument increased according to the proportion of astaxanthin supplemented in the diet up to the highest concentration (400 mg/kg). The highest concentration of carotenoids in the *L. alexandri* muscle was between treatments with 100 and 200 mg/kg of astaxanthin. However, the rate of carotenoid retention in the muscle was inversely proportional to the proportion of inclusion of astaxanthin in the diet as noted by Song et al. (2016). For Choubert et al. (1995), the use of different amounts of carotenoids does not always result in better results of retention of carotenoids in the muscle, as this depends on the digestive/accumulative physiology of the fish. The fact was also observed by Safari & Atashi (2015).

Again in the treatment with the addition of 100 mg/kg of astaxanthin, there was the lowest index of carotenoid concentration in the integument concerning the muscle than in the treatments of lesser and greater supplementation. In a way,

this result is interesting from the point of view that, in the case of *L. alexandri*, we commercially recommend the color of the fillet and the color of the skin is of secondary importance. Differences in the concentration of carotenoids in the skin and muscle occur and differ as the supplemented amount of carotenoids in the fish diet changes (Teimouri & Amirkolaie 2013), making it necessary to establish the priority (skin or muscle) according to the specificity of the use of fish (ornamental or for food). The higher accumulation of carotenoids in the integument in relation to the muscle is the result of the higher concentration of lipids, cholesterol, and monounsaturated fatty acids (MUFA) in this tissue, as observed by Merdzhanova et al. (2018) in a study with African catfish *C. gariepinus*.

Although astaxanthin is widely used as the normal carotenoid for muscle pigmentation in aquatic organisms, some species may have a greater capacity for assimilation and accumulation of other pigments, since the ability to use a given carotenoid for pigmentation varies according to the fish species (Matsuno et al. 1980, Metusalach et al. 1997, Olsen & Baker 2006, Choubert 2010). Future studies may show that *L. alexandri* has better muscle retention rates than other xanthophylls, such as another siluriform, channel catfish *I. punctatus*, which accumulates more carotenoids when its diet is supplemented with lutein or canthaxanthin than with astaxanthin, beta carotene, and zeaxanthin (Li et al. 2007). Astaxanthin was detected minority or was absent in the pigmentary profile of 12 species of siluriforms from 8 different families by Tsushima et al. (2002), where the predominant carotenoids were zeaxanthin and lutein. According to Parolini et al. (2018), the physiological conditions of the liver may be indicative of the beneficial action of carotenoids in the fish organism. Histology is one of the tools to identify and compare

data on the physiological condition associated with the cellular morphology of the liver of fish and the use of additives in their artificial diets (Rodríguez-Lozano et al. 2017). This study did not find any morphological difference that shows the effect of treatments on the histological or histopathological condition in the hepatic tissues of *L. alexandri*.

## CONCLUSIONS

The *L. alexandri* manages to take advantage of the dietary astaxanthin for deposition of carotenoids in the muscle and skin, without influencing its development and nutritional condition in the life phase studied for the period of cultivation of two months. However, high doses of this pigment seem to contribute to the reduction of liver enzyme AST levels without influencing the histological condition of the liver. For the best use of synthetic astaxanthin as pigmentation and a more balanced coloring between the muscle and the integument, the level of inclusion in the *L. alexandri* diet of 100 mg/kg of this carotenoid is recommended.

## Acknowledgments

The authors would like to thank Coordenação de Aperfeiçoamento de Pessoal de Nível Superior (CAPES) for the scholarship to Daniel Pereira da Costa. Kleber C. Miranda-Filho and Ronald K. Luz are research fellows of Conselho Nacional de Desenvolvimento Científico e Tecnológico (CNPq, No. 302286/2018-7; No. 308547/2018-7). Poli-Nutri® animal nutrition by donating astaxanthin, and Nanoplastic® for donating filter media. The authors declare no conflict of interest. The founding sponsors had no role in the design of the study; in the collection, analyses, or interpretation of data; in the writing of the manuscript, and in the decision to publish the results. The authors declare that they have no known competing financial interests or personal relationships that could have appeared to influence the work reported in this paper.

## REFERENCES

- AGUIRRE-HINOJOSA E, PIÑA-VALDEZ, P, GARZA-AGUIRRE MC, GUZMÁN-RAMIREZ LD, MONTOYA-OLVERA R, TORRES-QUIROGA J & NIEVES-SOTO M. 2012. Efecto de las xantofilas de la flor de cempaschúhil *Tagetes erecta* L. em la acumulación de astaxantina y la sobrevivência de postlavas del camarón blanco *Litopenaeus vannamei* (Boone 1931). *Rev Mex Ing Quím* 11(2): 249-257.
- BARON M, DAVIES S, ALEXANDER D, SNELGROVE D & SLOMAN KA. 2008. The effect of dietary pigments on the coloration and behavior of flame red dwarf gourami, *Colisa lalia*. *Animal Behav* 75(3): 1041-1051. <https://doi.org/10.1016/j.anbehav.2007.08.014>.
- BERNET D, SCHMIDT H, MEIER W, BURKHARDT-HOLM P & WAHLI T. 1999. Histopathology in fish: proposal for a protocol to assess aquatic pollution. *J Fish Dis* 22(1): 25-34. <https://doi.org/10.1046/j.1365-2761.1999.00134.x>.
- BICUDO AJA, BORGHESI R, DAIRIKI JK, SADO RY & CYRINO JEP. 2012. Performance of juvenile of *Pseudoplatystoma fasciatum* fed graded levels of corn gluten meal. *Pesq Agropec Bras* 47(6): 838-845. <https://doi.org/10.1590/S0100-204X2012000600015>.
- BREITENBACH J, NOGUEIRA M, FARRÉ G, ZHU C, CAPELL T, CHRISTOU P, FLECK G, FOCKEN U, FRASER PD & SANDMANN G. 2016. Engineered maize as a source of astaxanthin: processing and application as fish feed. *Transg Res* 25(6): 785-793. <https://doi.org/10.1007/s11248-016-9971-3>.
- CASANOVES F, BALZARINI MG, DI RIENZO JA, GONZALEZ L, TABLADA M & ROBLEDO CW. 2012. InfoStat. User Manual, Córdoba, Argentina.
- CHARO-KARISA H, OPIYO M, MUNGUTI J, MARIJANI E & NZAYISENGA L. 2013. Cost-benefit analysis and growth effects of pelleted and unpelleted on-farm feed on African catfish (*clarias gariepinus* burchell 1822) in earthen ponds. *African J Food Agri Nutr Develop* 14(4): 8019-8033.
- CHENG C-H, GUO Z-X, YE CX & WANG A-L. 2017. Effect of dietary astaxanthin on the growth performance, non-specific immunity, and antioxidant capacity of pufferfish (*Takifugu obscurus*) under high temperature stress. *Fish Physiol Biochem* 44(1): 209-218. <https://doi.org/10.1007/s10695-017-0425-5>.
- CHIMSUNG N, LALL SP, TANTIKITTI C, VERLHAC-TRICHET V & MILLEY JE. 2013. Effects of dietary cholesterol on astaxanthin transport in plasma of Atlantic salmon (*Salmo salar*). *Comp Biochem Physiology Part B* 165(1): 73-81. <https://doi.org/10.1016/j.cbpb.2013.02.007>.
- CHOUBERT G. 2010. Response of rainbow trout (*Oncorhynchus mykiss*) to varying dietary astaxanthin/canthaxanthin ratio: Colour and carotenoid retention of the muscle. *Aquac Nutr* 16(5): 528-535. <https://doi.org/10.1111/j.1365-2095.2009.00692.x>.
- CHOUBERT G, MILICUA JG, GOMEZ R, SANCÉ S, PETIT H, NÈGRE-SADARGUES G, CASTILLO R & TRILLES J-P. 1995. Utilization of carotenoids from various sources by rainbow trout: muscle color, carotenoid digestibility and retention. *Aquac Int* 3(3): 205-216. <https://doi.org/10.1007/BF00118102>.
- COSTA DP, CASTILHO CL, SANTOS URA, GEMAQUE TC, DAMASCENO LF, LIMA JF & MIRANDA-FILHO KC. 2021a. Effect of dietary carotenoids on reproducers of Amazon river prawn *Macrobrachium amazonicum*. Part 1: Metabolism, morphometric / zootechnical indexes, body composition and gametes. *J Agric Stud* 9: 32-56. <https://doi.org/10.5296/jas.v9i2.18156>.
- COSTA DP, CASTILHO CL, SANTOS URA, GEMAQUE TC, DAMASCENO LF, LIMA JF & MIRANDA-FILHO KC. 2021b. Effect of dietary carotenoids on reproducers of Amazon river prawn *Macrobrachium amazonicum*. Part 2: External coloration, accumulation of astaxanthin in body tissues and pigment stability in feed. *J Agric Stud* 9: 57-72. <https://doi.org/10.5296/jas.v9i2.18159>.
- COSTA DP, LEME FOP, TAKATA R, COSTA DC, SILVA WS, MELILLO-FILHO R, MICCOLI GA & LUZ RK. 2014. Effects of temperature on growth, survival and physiological parameters in juveniles of *Lophiosilurus alexandri*, a carnivorous neotropical catfish. *Aquac Res* 47(6): 1706-1715. <https://doi.org/10.1111/are.12594>.
- COSTA DP & MIRANDA-FILHO KC. 2020. The use of carotenoid pigments as food additives for aquatic organisms and their functional roles. *Rev Aquac* 12(3): 1567-1578. <https://doi.org/10.1111/raq.12398>.
- DANANJAYA SHS, MUNASINGHE DM, ARIYARATNE HBS, LEE J & DE ZOYSA. 2017. Natural bixin as a potential carotenoid for enhancing pigmentation and colour in goldfish (*Carassius auratus*). *Aquac Nutr* 23(2): 255-263. <https://doi.org/10.1111/anu.12387>.
- DOOLAN BJ, BOOTH M, GEOFF LA & PAUL LJ. 2009. Changes in skin colour and cortisol response of Australian snapper *Pagrus auratus* (Bloch & Schneider, 1801) to different background colours. *Aquac Res* 40(5): 542-550. <https://doi.org/10.1111/j.1365-2109.2008.02126.x>.
- FOSS P, STOREBAKKEN T, SCHIEDT K, LIAAEN-JENSEN S, AUSTRENG E & STREIFF K. 1984. Carotenoids in diets for salmonids. I. Pigmentation of rainbow trout with the individual optical isomers of astaxanthin in comparison with canthaxanthin. *Aquaculture* 41(3): 213-226. [https://doi.org/10.1016/0044-8486\(84\)90284-9](https://doi.org/10.1016/0044-8486(84)90284-9).

- GÖÇER M, YANAR M, KUMULU M & YANAR Y. 2006. The effects of red pepper, marigold flower and syntetic astaxanthin on pigmentation, growth and proximate composition of *Penaeus semisulcatus*. Turk J Vet Anim Sci 30(4): 359-365.
- HANSEN Ø, PUVANENDRAN V & BANGERA R. 2014. Broodstock diet with water and astaxanthin improve condition and egg output of brood fish and larval survival in Atlantic cod, *Gadus morhua* L. Aquac Res 47(3): 819-829. <https://doi.org/10.1111/are.12540>.
- HU B, ROY L & DAVIS D. 2013. Correlations of xanthophylls in catfish fillets, plankton, shad and snails in catfish production ponds in west Alabama. Aquaculture 402-403: 46-49. <https://doi.org/10.1016/j.aquaculture.2013.03.022>.
- INGLE DE LA MORA G, ARREDONDO-FIGUEROA JL, PONCE-PALAFIX JT, BARRIGA-SOCA IA & VERNON-CARTER JE. 2006. Comparison of red chilli (*Capsicum annuum*) oleoresin and astaxanthin on rainbow trout (*Oncorhynchus mykiss*) fillet pigmentation. Aquaculture 258(1-4): 487-495. <https://doi.org/10.1016/j.aquaculture.2006.04.005>.
- JAGRUTHI C, YOGESHWARI G, ANBAZHAN SM, MARI LSS, AROCKIARAJ J, MARIAPPAN P, SUDHAKAR GRL, BALASUNDARAM C & HARIKRISHNAN R. 2014. Effect of dietary astaxanthin against *Aeromonas hydrophila* infection in common carp, *Cyprinus carpio*. Fish Shellfish Immunol 41(2): 674-680. <https://doi.org/10.1016/j.fsi.2014.10.010>.
- LI M, WU W, ZHOU P, XIE F, ZHOU Q-C & MAI K. 2014. Comparison effect of dietary astaxanthin and *Haematococcus pluvialis* on growth performance, antioxidant status and immune response of large yellow croaker *Pseudosciaena crocea*. Aquaculture 434: 227-232. <https://doi.org/10.1016/j.aquaculture.2014.08.022>.
- LI MH, ROBINSON EH, OBERLE DF & ZIMBA PV. 2007. Effects of various dietary carotenoid pigments on fillet appearance and pigment absorption in channel catfish, *Ictalurus punctatus*. J World Aquac Soc 38(4): 557-563. <https://doi.org/10.1111/j.1749-7345.2007.00130.x>.
- LIRANÇO ADS, ROMAGOSA E & SCORVO-FILHO JD. 2011. Desempenho produtivo de *Pseudoplatystoma corruscans* estocados em sistemas de criação: semi-intensivo (viveiro escavado) e intensivo (tanque-rede). Ciênc Rural 41(3): 524-530. <https://doi.org/10.1590/S0103-84782011000300027>.
- LIU F, SHI H, GUO Q, YU Y, WANG A, LVF & SHEN W. 2016. Effects of astaxanthin and emodin on the growth, stress resistance and disease resistance of yellow catfish (*Pelteobagrus fulvidraco*). Fish Shellfish Immunol 51: 125-135. <https://doi.org/10.1016/j.fsi.2016.02.020>.
- LIU S, LI Y, WU Y, BELL L, DAVIS D & WANG Y. 2012. Extraction, identification and quantitation of carotenoids in discolored channel catfish (*Ictalurus punctatus*) fillets. J Food Comp Anal 26(1-2): 154-159. <https://doi.org/10.1016/j.jfca.2012.01.006>.
- MAOKA T & AKIMOTO N. 2011. Structures of minor carotenoids from the Japanese common catfish, *Silurus asotus*. Chem Pharm Bull 59(1): 140-145.
- MARTINELLI SG, RADÜNZ NETO J, SILVA LP, BERGAMIN GT, MASCHIO D, FLORA MALD, NUNES M, LM & POSSANI G. 2013. Densidade de estocagem e frequência alimentar no cultivo de jundiã em tanques-rede. Pesq Agropec Bras 48(8): 871-877. <https://doi.org/10.1590/S0100-204X2013000800009>.
- MATSUNO T, NAGATA S, KATSUYAMA M, MATSUTAKA H, MAOKA T & AKITA T. 1980. Comparative biochemical studies of carotenoids in fishes - XVIII: Carotenoids of cultured fishes, Japanese char, Brook trout, Lake trout, Masu trout, Red-Spotted Masu trout, Rainbow trout and Brown trout. Nippon Suisan Gakk 46: 473-478. <https://doi.org/10.2331/suisan.46.473>.
- MERDZHANOVA A, DOBREVA D & PANAYOTOVA V. 2018. Comparison of fatty acids, cholesterol, fat soluble vitamins and carotenoids content of skin and edible tissue of farmed African catfish (*Clarias gariepinus*, Burchell 1822). Ovidius Univ Ann Chem 29(1): 41-47. <https://doi.org/10.2478/auoc-2018-0006>.
- METUSALACH JA, BROWN J & SHAHIDI F. 1997. Effects of stocking density on colour characteristics and deposition of carotenoids in cultured Arctic charr (*Salvelinus alpinus*). Food Chem 59(1): 107-114. [https://doi.org/10.1016/S0308-8146\(96\)00205-1](https://doi.org/10.1016/S0308-8146(96)00205-1).
- NAKANO T, TOSA M & TAKEUCHI M. 1995. Improvement of biochemical features in fish health by red yeast and synthetic astaxanthin. J Agri Food Chem 43: 1570-1573. <https://doi.org/10.1021/jf00054a029>.
- OLSEN R & BAKER RTM. 2006. Lutein does not influence flesh astaxanthin pigmentation in the Atlantic salmon (*Salmo salar* L.). Aquaculture 258(1-4): 558-564. <https://doi.org/10.1016/j.aquaculture.2006.03.031>.
- PAGE GI, RUSSELL PM & DAVIES SJ. 2005. Dietary carotenoid pigment supplementation influences hepatic lipid and mucopolysaccharide levels in rainbow trout (*Oncorhynchus mykiss*). Comp Biochem Physiol Part B 142(4): 398-402. <https://doi.org/10.1016/j.cbpb.2005.09.001>.
- PALMA J, ANDRADE JP & BUREAU D. 2016. The impact of dietary supplementation with astaxanthin on egg quality and growth of long snout seahorse (*Hippocampus guttulatus*) juveniles. Aquac Nutr 23(2): 304-302. <https://doi.org/10.1111/anu.12394>.

- PAN C-H, CHIEN Y-H & WANG Y-J. 2010. The antioxidant capacity response to hypoxia stress during transportation of characins (*Hyphessobrycon callistus* Boulenger) fed diets supplemented with carotenoids. *Aquac Res* 41(7): 973-981. <https://doi.org/10.1111/j.1365-2109.2009.02380.x>.
- PAN C-H, CHIEN Y-H & WANG Y-J. 2011. Antioxidant defence to ammonia stress of characins (*Hyphessobrycon eques* Steindachner) fed diets supplemented with carotenoids. *Aquac Nutr* 17(3): 258-266. <https://doi.org/10.1111/j.1365-2095.2009.00747.x>.
- PAROLINI M, IACOBUZIO R, POSSENTI C, BASSANO B, PENNATI R & SAINO N. 2018. Carotenoid-based skin coloration signals antioxidant defenses in the brown trout (*Salmo trutta*). *Hydrobiologia* 815(1): 267-280. <https://doi.org/10.1007/s10750-018-3571-6>.
- ŘEHULKA J. 2000. Influence of astaxanthin on growth rate, condition, and some blood indices of rainbow trout, *Oncorhynchus mykiss*. *Aquaculture* 190(1-2): 27-47. [https://doi.org/10.1016/S0044-8486\(00\)00383-5](https://doi.org/10.1016/S0044-8486(00)00383-5).
- RODRIGUEZ-AMAYA DB. 2001. A guide to carotenoid analysis in foods. Washington, EUA: Internacional Life Sciences Institute Press, 64 p.
- RODRIGUEZ-AMAYA DB & KIMURA M. 2004. Handbook for carotenoid analysis. Washington, EUA: HarvestPlus, 58 p. (HarvestPlus Technical Monograph, 2).
- RODRÍGUEZ-LOZANO A, BORGES P, ROBAINA L, BETANCOR M, HERNANDEZ-CRUZ M, ROMERO GARCÍA J, CABALLERO MJ, VERGARA JM & IZQUIERDO M. 2017. Effect of different dietary vitamin E levels on growth, fish composition, fillet quality and liver histology of meagre (*Argyrosomus regius*). *Aquaculture* 468(1): 475-138. <https://doi.org/10.1016/j.aquaculture.2016.10.006>.
- SAFARI O & ATASHI MMS. 2015. The effects of dietary supplement of annatto (*Bixa orellana*) seed meal on blood carotenoid content and fillet color stability in rainbow trout (*Oncorhynchus mykiss*). *Aquaculture* 473(1): 275-281. <https://doi.org/10.1016/j.aquaculture.2014.12.012>
- SHEIKHZADEH N, TAYEFI-NASRABADI H, KHANIAO & NAJAFI H. 2012. Effects of *Haematococcus pluvialis* supplementation on antioxidant system and metabolism in rainbow trout (*Oncorhynchus mykiss*). *Fish Physiol Biochem* 38(2): 413-419. <https://doi.org/10.1007/s10695-011-9519-7>.
- SILVA MJS, COSTA FFB, LEME FP, TAKATA R, COSTA DC, MATTIOLI CC, LUZ RK & MIRANDA-FILHO KC. 2018. Biological responses of Neotropical freshwater fish *Lophiosilurus alexandri* exposed to ammonia and nitrite. *Sci Total Environ* 616-617: 1566-1575. <https://doi.org/10.1016/j.scitotenv.2017.10.157>.
- SONG X, WANG L, LI, X, CHEN Z-Z, LIANG G & LENG X. 2016. Dietary astaxanthin improved the body pigmentation and antioxidant function, but not the growth of discus fish (*Symphysodon* spp.). *Aquac Res* 48(4): 1359-1367. <https://doi.org/10.1111/are.13200>.
- TEIMOURI M & AMIRKOLAIE AK. 2013. The effects of synthetic pigments on pigmentation of *Pethia conchonius* (Hamilton, 1822). *Aquac Res* 46(5): 1156-1161. <https://doi.org/10.1111/are.12271>.
- TSUSHIMA M, IKUNO Y, NAGATA S, KODAMA K & MATSUNO T. 2002. Comparative biochemical studies of carotenoids in catfishes. *Comp Biochem Physiol* 133(3): 131-136. [https://doi.org/10.1016/S1096-4959\(02\)00159-8](https://doi.org/10.1016/S1096-4959(02)00159-8).
- TYSSANDIER V, CHOUBERT G, GROLIER P & BOREL P. 2002. Carotenoids, mostly the xanthophylls, exchange between plasma lipoproteins. *Int J Vit Nutr Res* 72(5): 300-308. <https://doi.org/10.1024/0300-9831.72.5.300>.
- UNESCO. 1983. Chemical methods for use in marine environmental monitoring. Manual and Guides 12. Intergovernmental Oceanographic Commission. Paris, France, 53 p.
- WANG Y-J, CHIEN Y-H & PAN C-H. 2006. Effects of dietary supplementation of carotenoids on survival, growth, pigmentation, and antioxidant capacity of Characins, *Hyphessobrycon callistus*. *Aquaculture* 261(2): 641-648. <https://doi.org/10.1016/j.aquaculture.2006.08.040>.
- YI X, XU W, ZHOU H, ZHANG Y, LUO Y, ZHANG W & MAI K. 2014. Effects of dietary xanthophylls/astaxanthin ratios on the growth and skin pigmentation of large yellow croaker *Larimichthys crocea* (Richardson, 1846). *Aquaculture* 433(4): 377-383. <https://doi.org/10.1016/j.aquaculture.2014.06.038>.
- ZAR JH. 2010. Biostatistical Analysis, 5th Edition. Northern Illinois University, 960 p.
- ZAŤKOVÁ I, SERGEJEVOVÁ M, URBAN J, VACHTA R, STYS D & MASOJÍDEK J. 2010. Carotenoid-enriched microalgal biomass as feed supplement for freshwater ornamentals: Albinic form of wels catfish (*Silurus glanis*). *Aquac Nutr* 17(3): 278-286. <https://doi.org/10.1111/j.1365-2095.2009.00751.x>.

#### How to cite

COSTA DP, SILVA MJS, GERALDI RM, LORENZINI JP, MATTIOLI CC, OLIVEIRA AL, LUZ RK & MIRANDA-FILHO KC. 2022. Effects of the use of synthetic astaxanthin in the feeding of *Lophiosilurus alexandri*, a neotropical siluriform fish. *An Acad Bras Cienc* 94: e20210434. DOI 10.1590/0001-3765202220210434.

*Manuscript received on March 23, 2021;  
accepted for publication on April 5, 2022*

**DANIEL P. DA COSTA<sup>1</sup>**

<https://orcid.org/0000-0002-8261-9899>

**MÁRCIO JOSÉ S. SILVA<sup>2</sup>**

<https://orcid.org/0000-0002-9389-567X>

**RICARDO MARCELO GERALDI<sup>2</sup>**

<https://orcid.org/0000-0002-0908-7275>

**JOÃO PAULO LORENZINI<sup>2</sup>**

<https://orcid.org/0000-0002-4271-5309>

**CRISTIANO C. MATTIOLI<sup>2</sup>**

<https://orcid.org/0000-0002-4271-5309>

**AFONSO DE LIGUORI OLIVEIRA<sup>3</sup>**

<https://orcid.org/0000-0002-5207-3063>

**RONALD K. LUZ<sup>2</sup>**

<https://orcid.org/0000-0002-1021-5772>

**KLEBER C. MIRANDA-FILHO<sup>2</sup>**

<https://orcid.org/0000-0002-3026-4491>

<sup>1</sup>Universidade do Estado do Amapá, Campus Território dos Lagos, Av. Desiderio Coelho 420, Sete Mangueiras, 68950-000 Amapá, AP, Brazil

<sup>2</sup>Universidade Federal de Minas Gerais, Departamento de Zootecnia, Escola de Veterinária, Av. Antônio Carlos, 6627, 31270-901 Belo Horizonte, MG, Brazil

<sup>3</sup>Universidade Federal de Minas Gerais, Departamento de Tecnologia e Inspeção de Produtos de Origem Animal, Escola de Veterinária, Av. Antônio Carlos, 6627, 31270-901 Belo Horizonte, MG, Brazil

Correspondence to: **Kleber Campos Miranda-Filho**

E-mail: [kmiranda2010@ufmg.br](mailto:kmiranda2010@ufmg.br), [kleber08@gmail.com](mailto:kleber08@gmail.com)

### Author contributions

All authors contributed equally for the conception and writing of the manuscript. All authors critically revised the manuscript and approved of the final version.

