


CASE HISTORY REPORT

WILEY

Intraoral granulocytic sarcoma as a manifestation of myelofibrosis: A case report and review of the literature

Laiz Fernandes Mendes Nunes DDS¹ | Amanda Leal Rocha DDS² |
 Gustavo Henrique Romani Magalhães, MD, MSc³ | Frederico Henrique Corrêa de Melo, MD,
 MSc⁴ | Denise Vieira Travassos DDS, MSc, PhD⁵ | Ricardo Alves Mesquita DDS, MSc, PhD² |
 Tarcília Aparecida Silva DDS, MSc, PhD² 

¹Dental Surgeon Resident, Hospital das Clínicas, Universidade Federal de Minas Gerais, Minas Gerais, Brazil

²Department of Oral Surgery and Pathology, Faculty of Dentistry, Universidade Federal de Minas Gerais, Minas Gerais, Brazil

³Department of Hematology and Oncology, Ambulatory of Chronic Myeloproliferative Diseases, Universidade Federal de Minas Gerais, Minas Gerais, Brazil

⁴Department of Pathology, Hospital das Clínicas, Universidade Federal de Minas Gerais, Minas Gerais, Brazil

⁵Department of Community and Preventive Dentistry, Faculty of Dentistry, Universidade Federal de Minas Gerais, Minas Gerais, Brazil

Correspondence

Tarcília Aparecida da Silva, Department of Oral Surgery and Pathology, Faculty of Dentistry, Universidade Federal de Minas Gerais, UFMG - Av. Presidente Antônio Carlos, 6627 - Pampulha, Belo Horizonte - MG, 31270-901, Brazil.
 Email: silva.tarcilia@gmail.com

Funding information:

This research did not receive any specific grant from funding agencies in the public, commercial, or not-for-profit sectors.

Abstract

Granulocytic sarcoma (GS) is an extramedullary tumor associated with myelodysplastic syndromes or myeloproliferative diseases. Intraoral manifestations are considered uncommon, with a reasonable number of cases, and are mostly related to leukemia. The association of oral GS and myelofibrosis is very rare and only three cases have been published. In this paper, we report the fourth case of oral lesion in a patient with a diagnosis of myelofibrosis. The aim of this study was to present a review of the literature, discussing the current and previous cases of oral GS associated with myelofibrosis or other hematological disorders and the importance of accurate diagnosis through clinical, microscopic, and immunohistochemical features.

KEYWORDS

mouth neoplasms, myeloid sarcoma, primary myelofibrosis

1 | INTRODUCTION

Granulocytic sarcoma (GS), also known as myeloid sarcoma (MS) or chloroma, is an extramedullary tumor mass of myeloid precursor cells, myeloblasts, or immature myeloid cells occurring outside the bone marrow or bone.¹ The literature demonstrates the association between GS, myelofibrosis,^{2–4} and acute myeloid leukemia (AML).⁵ It is estimated that 46.3% of GS cases occur in patients with AML.⁵ The lesion coexists with, follows, or rarely precedes the presentation of AML, and it appears as a blastic

transformation of an underlying chronic myeloproliferative disease or myelodysplastic syndrome.¹

GS originates from bone marrow and spreads via Haversian canals to reach the subperiosteal bone region, spreading the tumor cells to other regions of the body.⁶ The most common site of GS is the skin, presenting as multiple papules, plaques, and nodules. The head and neck region is affected in 12% to 43% of GS cases,⁷ and intraoral involvement is uncommon. Intraoral GS may appear as a solitary or multiple asymptomatic nodule, diffuse gingival enlargement, or as an intraosseous lesion.^{4,6,8–10}

The aim of this paper is to report a rare case of gingival GS in a patient with a diagnosis of myelofibrosis and to present a review of the literature discussing three previous cases of oral GS associated with myelofibrosis. We also present a description of previous intraoral GS cases associated with other hematological disorders.

2 | CASE REPORT

An 81-year-old Caucasian man was referred by his hematologist to the Dentistry Service of the Clinical Hospital, Federal University of Minas Gerais (HC-UFMG) in April 2016 for evaluation of bleeding and swelling in the gingiva with undefined evolution time. The patient was first diagnosed with myelofibrosis in 2012 with V617F Jak-2 mutation positive, bcr-abl fusion gene negative, and cytogenetic analysis without changes (46,XY[30/30]). Bone marrow biopsy showed diffuse fibrosis and myeloproliferative patterns in the initial evaluation. He was initially treated with only hydroxyurea with partial response. In the anamnesis, the patient reported use of the following medications: Isosorbide Mononitrate, Clopidogrel, Carvedilol, Amlodipine Besylate, Allopurinol, Rosuvastatin, Metformin, Glimepiride, Bromazepam, Fluoxetine, Hydroxyurea (Hydrea®), and Ruxolitinib (Jakavi®). He had arterial hypertension, type II diabetes mellitus, and unstable angina as comorbidities. The socioeconomic condition was not contributory and extraoral examination did not show important changes.

Upon intraoral examination, an asymptomatic, well-defined, soft swelling was observed on the right maxilla associated with vestibular gingiva of the first and second premolars. The lesion presented a smooth and wavy surface and was nodular, sessile, purple in color, and measured about 2 × 2 × 1 cm (Figure 1A). It was soft and bleeding on palpation. The associated teeth showed significant mobility, and no mobility was detected in other teeth during clinical examination. There was no history of local trauma or recent dental treatment, and oral hygiene was satisfactory.

The periapical radiography showed a radiolucent area localized between the first and second premolars on the right side of the maxilla. It was a single lesion with extensive destruction of alveolar bone and ill-defined borders. There was also an irregular enlargement of the periodontal ligament spaces around the premolars, destruction of the lamina dura, and no evidence of root resorption. There was also widening of bone marrow spaces around the lesion. In addition, there was a radiolucent image in the cervical area in the first premolar, suggesting carious lesion (Figure 1B).

2.1 | Diagnosis

The patient underwent surgical extraction of the right maxillary first and second premolars under local anesthesia. As both

teeth presented significant alveolar bone loss and teeth mobility, extraction was the indicated treatment. The extraction procedure consisted of intrasulcular incision, detachment of the periodontal ligament, luxation with an elevator, and removal with forceps, without need of osteotomy. Then, the alveolar socket was vigorously curetted and sutured. After the surgical procedure, the nodular lesion was dissected from the teeth and the specimen was sent to the Pathology Service of HC-UFMG for analysis.

Microscopically, hematoxylin-eosin-stained (H&E) sections showed a proliferation of blast cells arranged in sheets. The cells had ovoid nuclei, a small amount of lightly eosinophilic cytoplasm, fine chromatin, and distinct nucleoli. The immature myeloid cells showed nuclear atypia (Figures 2A and B). Immunohistochemistry was performed, and the cells demonstrated positivity for CD68 (Figure 2C), myeloperoxidase (MPO) (Figure 2D), and Ki-67 (≈50%) (Figure 2F). Rare cells were positive for CD34 (Figure 2E) and a diagnosis of GS was made.

2.2 | Management

After diagnosis of GS, panoramic radiography and cone beam computed tomography (CBCT) were requested to investigate the presence of other lesions in maxillary and mandibular bones. In both exams, it was possible to notice the absence of other lesions (Figure 3).

The hematologist also requested a Fan beam computed tomography of the chest and abdomen, and there was no other extramedullary lesion. The current therapy was based on the use of Hydrea® (Hydroxyurea) and Jakavi® (Ruxolitinib).

The patient's follow-up period was 24 months, and the clinical examination (Figure 4A), periapical radiography (Figure 4B), and CBCT showed that the previous lesion area was completely repaired with no signs or symptoms of recurrence.

2.3 | Differential diagnosis

Based on the clinical features, radiographic findings of periodontal ligament irregular widening associated with bone resorption, and the medical diagnosis of myelofibrosis, the diagnostic hypothesis included, besides the GS, other malignant lesions such as Kaposi sarcoma (KS) and non-Hodgkin lymphoma (NHL). As localized, gingival overgrowths frequently manifest nonneoplastic processes which are sequela of nonspecific inflammatory reactions in response to the underlying local irritants,¹ the following conditions were also considered as differential diagnosis: pyogenic granuloma (PG), peripheral giant cell lesion (PGCL), and peripheral ossifying fibroma (POF). It is important to note that PG, PGCL, POF, and KS rarely cause bone destruction, but the clinical findings are similar to our case.

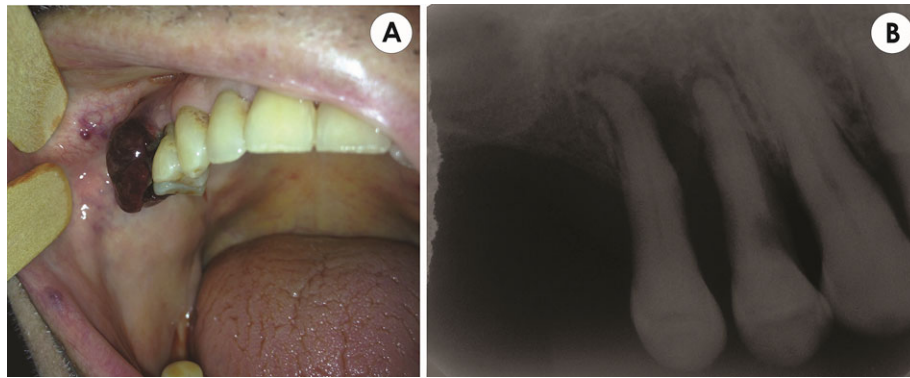


FIGURE 1 Clinical and radiographic initial findings. (A) Intraoral view showing a sessile, purple nodule localized at the vestibular gingiva between the maxillary right first and second premolars. (B) Periapical radiograph of first and second maxillary right premolars before extraction, showing a single lesion with irregular borders. There is irregular enlargement of the spaces of the periodontal ligaments around the premolars and destruction of the lamina dura

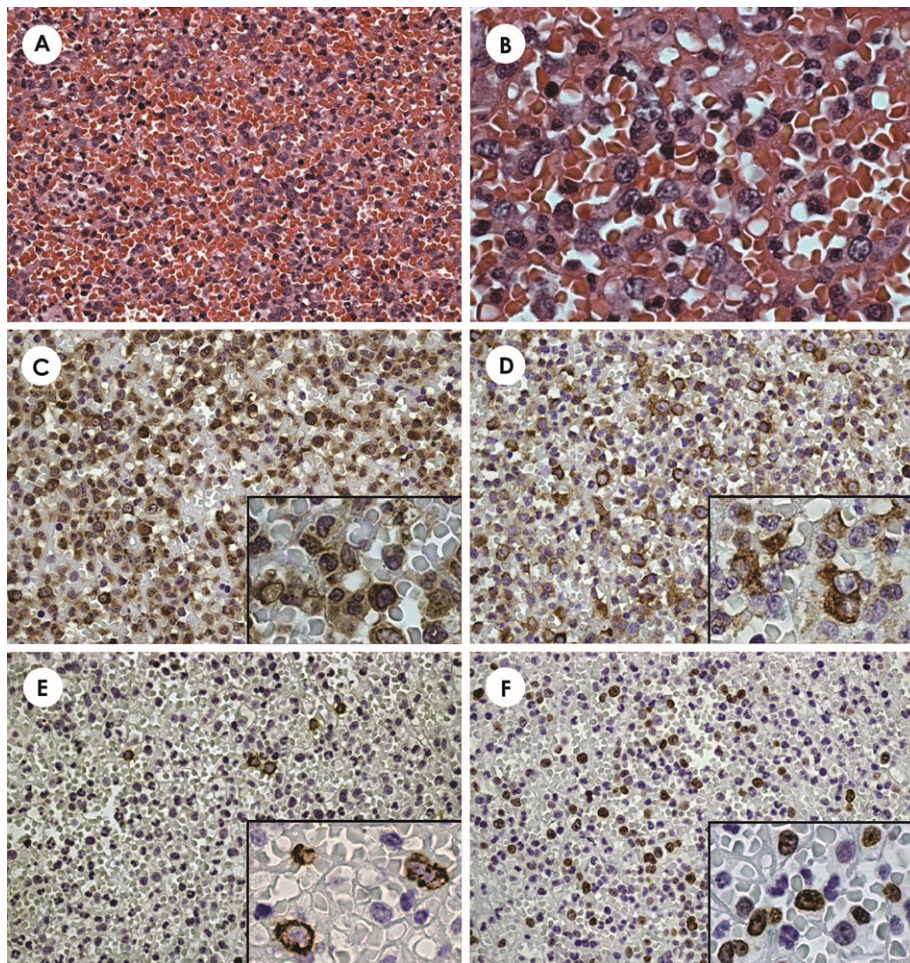


FIGURE 2 Histological and immunohistochemical findings. (A) Proliferation of blast cells (H&E stain, x400). (B) Immature myeloid cells showing ovoid nuclei, fine chromatin, distinct nucleoli, and nuclear atypia (H&E stain, x1000). (C) Strong immunoreactivity to the marker CD68 (IHC stain, x400) (IHC stain, x1000). (D) Tumor cells strongly positive for myeloperoxidase (MPO) (IHC stain, x400) (IHC stain, x1000). (E) Pale positive reaction with CD34 (IHC stain, x400) (IHC stain, x1000). (F) Positive reaction with Ki67, ~50% (IHC stain, x400) (IHC stain, x1000)

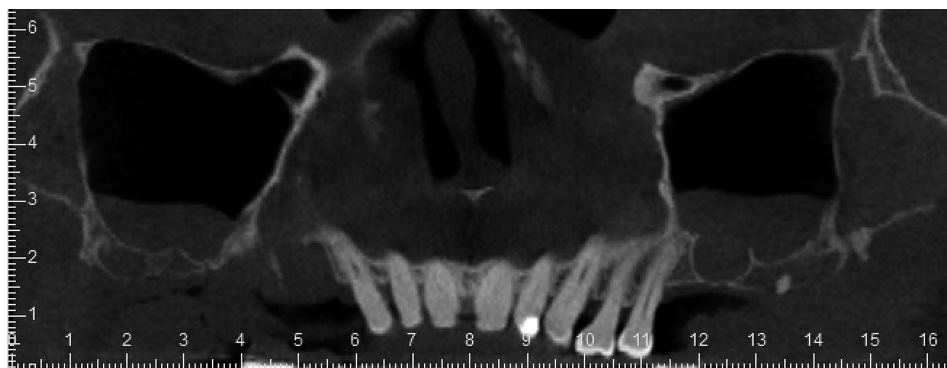


FIGURE 3 Panoramic view of computed tomography 10 days after the surgical procedure. No lesion was observed in other regions of the maxillary bone

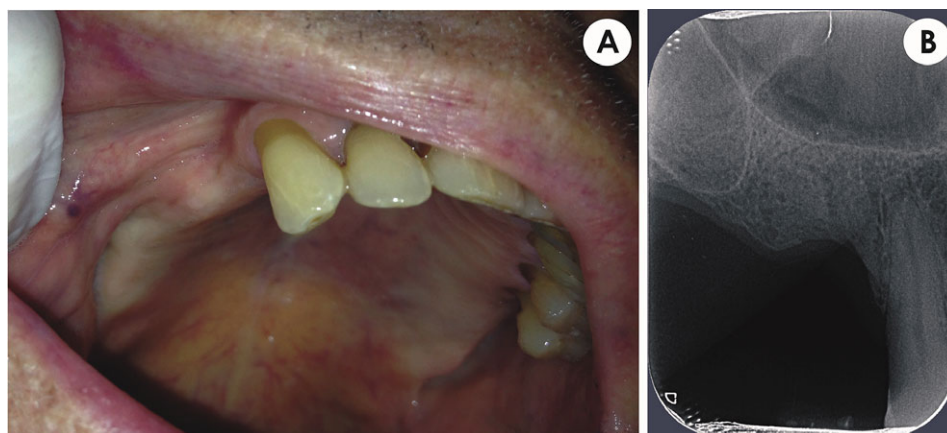


FIGURE 4 Patient image at 24 months postoperatively. (A) Intraoral view without alterations in oral mucosa. (B) Periapical radiograph showing the previous lesion area completely repaired with no signs of recurrence

KS is a rare vascular neoplasm associated with human herpes virus 8 infection (HHV-8). It is locally aggressive and typically presents as cutaneous lesions in the form of multiple patches, plaques, or nodules, but it may also involve mucosal sites. There are four epidemiological KS categories. Of these, only the AIDS-related (acquired immunodeficiency syndrome) type is associated with oral manifestations. Oral KS most frequently occurs on the hard palate, followed by the gingiva and the tongue, as purplish, reddish blue, or dark brown macules, plaques, and nodules that may ulcerate.¹¹ The second most frequent site, gingiva, and the clinical presentation of oral KS are consistent with the present case but there was no previous diagnosis of AIDS.

NHL occurs mainly in the lymph nodes but it can occur in extranodal sites. About 20% to 40% of NHL cases arise from extranodal sites, including the oral cavity.¹² NHL can develop in the soft oral tissues or in the maxillary and mandibular bones. NHL represents the third most common malignancy in the oral cavity, after squamous cell carcinoma and malignancies of the salivary glands, but the involvement of the oral cavity is a rare event (0.1% to 5%). It is described

most frequently in the maxilla than in the mandible, and the most common sites involved are palate and gingiva,^{12,13} which is consistent with the present case. NHL of the oral cavity has no specific clinical features and can mimic other diseases such as periodontal disease, osteomyelitis, and other malignancies.¹² Common presentations include asymptomatic localized swelling with spongy consistency, a red color with destruction of hard and soft tissues, tooth mobility, or as a sessile soft tissue mass.^{12,13} As in the present case, the lesion was red and presented destruction of hard tissues and tooth mobility.

PG is a benign mucocutaneous inflammatory lesion which presents an exuberant tissue that clinically appears as a sessile or pedunculated swelling with a smooth or lobulated surface that may easily bleed or ulcerate.¹ The color of the lesion varies from pink to red and purple, depending on the vascularity, as was the lesion in this case. Radiographic findings are not common in PG and typically it develops asymptotically. Gingiva is the most affected site, representing 75% of cases, with the maxillary gingiva more commonly affected on the buccal side,¹⁴ as in the present case. The lesion is caused

by a local irritation or trauma, including poor oral hygiene, which is not similar with the present case. PG is most common in young adult females, probably due to the vascularization effects of estrogen and progesterone,¹⁴ which is inconsistent with the gender and age of the patient in this case.

Another diagnosis that was considered was PGCL. It is a reactive, extraosseous and exophytic, nodular lesion, located in the gingiva or nonedentulous alveolar ridge. The lesion clinically presents as a sessile or pedunculated nodule, ranging from pink to purplish-blue color, with an occasionally ulcerated surface,¹ which was observed in the present case. Although PGCL develops within the soft tissues, a “cup” resorption of the underlying alveolar bone can sometimes be observed. This lesion may occur both in the anterior and posterior region of the gingiva or alveolar ridge, with the mandible being slightly more affected than the maxilla.¹⁵ Again, except for significant alveolar bone destruction seen in the present case, the general profile of PGCL was observed in our patient.

POF was initially included in the differential diagnosis because it occurs in the gingiva as a nodular mass, sessile, or pedunculated, that usually has its origins in the interdental papilla.¹⁶ It shows a reddish or pink pigmentation or is similar in color to the adjacent mucosa. Females are more commonly affected, and the anterior maxilla is the most prevalent location of involvement.¹⁷ The lesion can present different radiographic features and in some reports calcifications can be observed at the center of the lesion.¹ Therefore, the radiographic findings of POF are not compatible with the present lesion.

3 | DISCUSSION

GS is an extramedullary malignant tumor composed of immature myeloid precursor cells. This tumor is strongly associated with AML and myelodysplastic syndromes or myeloproliferative diseases.¹⁸ This association can be demonstrated in the present case since the patient had myelofibrosis. GS may develop in a variety of anatomic regions, including the skin, bones, gastrointestinal tract, and upper respiratory tract.^{19–21} Oral GS is considered an uncommon lesion with a reasonable number of cases, mostly associated with AML (Table 1).

The patient in this case had the medical diagnosis of myelofibrosis previous to the nodular manifestation in the oral cavity. The association of oral GS and myelofibrosis is very rare and only three cases have been published.^{2–4} Different from the present case, all previously described patients were women. In the Jacobs and Sellars² clinical report, the patient was 54 years old and presented a nontender firm swelling in the malar region of the face. The radiography showed diffuse soft tissue swelling overlying the zygomatic process. The patient was treated with local radiotherapy and remission

occurred within 4 weeks. In the follow-up, widespread GS was seen with hematological evidence of myeloblastic transformation and extensive leukemic involvement.² Nevertheless, the diagnosis of this case was made only based on H&E. Two years later, Saleh *et al.*³ described the case of a 62-year-old patient with a right mandibular mass and diagnosis of acute myelofibrosis. The biopsy specimen analysis revealed that the blasts had myeloblastic morphology and reacted with myeloid markers. The initial treatment consisted of low-dose subcutaneously chemotherapy, but the disease progressed, with pancytopenia and an increasing number of blasts in the peripheral blood. Then, the proposed scheme was standard systemic chemotherapy.³ In a report by Fasanmade *et al.*,⁴ a 75-year-old patient presented a mandibular right canine tooth with mobility associated with an erythematous gingiva. The periapical radiograph showed localized alveolar bone loss. The diagnosis of GS was made with immunophenotyping, demonstrating positivity for CD68, CD34, and CD117. The bone marrow biopsy did not show any evidence of leukemic infiltrate, and the treatment consisted of focal radiotherapy.⁴

In a review of the English literature performed from 1974 to 2018, 74 cases of oral GS were retrieved (Table 1). Only cases with a diagnosis based on immunohistochemistry or histochemistry were included. Thus, five cases were excluded because the diagnosis was only established using H&E staining. This criterion was adopted due to the fact that for the confirmation of granulocytic differentiation of myeloblasts, the use of specific markers is necessary.¹ Articles in non-English language were not included, and only complete case reports were analyzed. A total of 12 publications were excluded because they did not meet these criteria.

The review of previously reported cases revealed that the age of affected patients ranged widely from 11 months to 89 years, with no gender predilection. The most common clinical manifestation described by the authors was swelling or a mass. The lesion usually appeared as a localized, solitary, painless, or moderately painful nodule.¹⁰ However, it could also appear as multiple oral masses, diffuse gingival enlargement, or as intraosseous lesion.⁴ Overlying mucosa can be intact or present superficial ulceration. Bone involvement appears radiographically as localized alveolar bone loss, but also as generalized and severe bone resorption (Table 1). In our case, radiographic features of malignant lesions were observed, which is compatible with GS.

In the present case, the patient was an 81-year-old man, presenting a nodular, sessile lesion, measuring about 2 cm at its largest point, and was purple and hemorrhagic. In accordance with the literature, the patient was asymptomatic, but the mandible represented the majority of the oral manifestations,^{22,23} which is not consistent with this case; however, GS has been reported at almost all intraoral sites (Table 1).

TABLE 1 Literature review of oral granulocytic sarcoma cases with diagnosis based on immunohistochemistry and histochemistry

References	Age/Sex	Clinical presentation	Location	Radiographic findings	Microscopic diagnosis	Disease
Neiman et al. (1981) ²⁹	NR	NR	soft palate	NR	HSHS- chloroacetate esterase IHC – lysozyme	NR
Hansen et al. (1982) ³⁰	83/F	Tumor	maxilla	No	HSHS - chloroacetate esterase	AML
Conran et al. (1982) ³¹	2/F	Swelling	Mandible	Yes	Electron micrograph	DF
Takagi et al. (1983) ³²	25/F	Swelling	mandibular gingiva	Yes	HSHS - chloroacetate esterase	AML
Reichart et al. (1984) ³³	35/F	Swelling	Mandible	Yes	HSHS - chloroacetate esterase	AML
Castella et al. (1984) ³⁴	89/F	Mass, ulcerated gray-white	Hard palate	NR	HSHS - chloroacetate esterase	DF
Timmis et al. (1986) ³⁵	52/M	Mass	Mandible retromolar	Yes	HSHS - chloroacetate esterase IHC - CD14, HLA	DF
Ficarra et al. (1987) ³⁶	67/F	Swelling	Hard palate	No	HSHS - chloroacetate esterase	AML
Saleh et al. (1987) ³	62/F	Mass	Mandible	NR	NR (myeloid markers)	MF
Dreizen, McCredie, Keating (1987) ^{37,‡}	NR	Bulging bosselated surface	Gingiva and adjacent palatal mucosa	NR	HSHS- chloroacetase esterase	AML/CML
Barker and Sloan (1988) ³⁸	4/F	Swelling	Maxilla, palate	Yes	HSHS - chloroacetate esterase	AML
De Vicente et al. (1990) ³⁹	56/M	Mass, reddish lesion	Mandibular gingiva	Yes	HSHS- chloroacetate esterase IHC - CD15, lysozyme, Mac 387	DF
Cho et al. (1990) ⁴⁰	3/M	Swelling	Mandible	Yes	HSHS - chloroacetate esterase	AML
Eisenberg et al. (1991) ⁴¹	33/M	Multiple nodules	Maxilla and mandible	NR	HSHS - Sudan black, α -naphthyl butyrate esterase; IHC- MPO	AML
Stack and Ridley (1993) ⁴²	70/M	Mass	Mandible	Yes	HSHS - chloroacetate esterase IHC - antilysozomal immunoperoxidase	CML
Ritter et al. (1994) ⁴³	41/F	Mass	Submandibular	NR	IHC- MPO, CD43, lysozyme,, Mac387, MB2	NR
Roth et al. (1995) ⁴⁴	47/M	NR	Gingiva	NR	HSHS - chloroacetate esterase IHC – CD43, lysozyme	AML
Lynch et al. (1998) ⁴⁵	86/F	Mass	Maxillary gingiva	Yes	IHC – MPO	AML
Menasce et al. (1999) ⁴⁶	54/F	Swelling	Gum	NR	HSHS- chloroacetate esterase IHC- MPO, CD43, lysozyme	MDS
Tomás et al. (2000) ²⁰	60/F	Tumefaction	Mandible	No	IHC – lysozyme	CML
Tong et al. (2000) ⁴⁷	76/F	Diffuse, ulcerative, granular lesion	Buccal sulcus of maxilla	No	IHC – MPO, CD45	AML
Lee et al. (2001) ⁴⁸	43/F	Swelling, firm, black-pigmented lesion	Maxillary gingiva	Yes	IHC – MPO, CD45	DF
Amin et al. (2002) ¹⁸	58/M	Swelling/mass	Hard palate	NR	IHC - CD34 (weak)	AML
Jordan et al. (2002) ⁴⁹	62/F	Periapical radiolucency	Mandible	Yes	IHC – MPO, CD15, CD43	ML
Antmen et al. (2003) ⁵⁰	12/F	Mass	Maxillary gingiva	Yes	IHC – MPO, lysozyme	AML

(Continues)

TABLE 1 (Continued)

References	Age/Sex	Clinical presentation	Location	Radiographic findings	Microscopic diagnosis	Disease
Asna, Cohen, Ben-Yosef (2003) ⁵¹	72/F	Fleshy-red lesion and a central crater	Tongue	No	IHC – MPO	MDS
Stoopler et al. (2004) ⁵²	50/M	Ulcerative lesion	Labial mucosa	No	IHC - CD43	AML
Colella et al. (2005) ¹⁹	62/F	Swelling	Maxillary gingiva	No	IHC - MPO, lysozyme, CD45, CD68	DF
Koudstaal et al. (2006) ⁵³	36/M	Swelling	Hard palate	No	IHC- CD4,CD43,CD45, HLA-DR	AML
Yoon et al. (2006) ⁵⁴	63/M	Diffuse enlargement	Mandibular and maxillary gingiva	NR	IHC - MPO,CD45,CD117	AML
Goteri et al. (2006) ⁵⁵	84/M	Ulcerated, nodular, infiltrative mass	Hard palate	Yes	IHC - CD34,CD43, CD45,CD117	DF
Yinjun, Jie, Zhimei (2006) ⁵⁶	44/F	Enlargement	Maxillary gingiva	NR	IHC - MPO,CD68	DF
Matsushita et al. (2007) ²⁶	50/M	Diffuse, ulcerative, and granular-appearing lesion	Maxillary tuber and palatinal mucosa	Yes	IHC - MPO,CD43	AML
Xie et al. (2007) ²¹	32/F	Multiple masses	Maxillary and mandibular gingiva	Yes	IHC - MPO,CD33,CD43	CML
Mohamedbhai et al. (2008) ⁵⁷	45/M	Ulcerated lesion	Tongue	No	IHC - MPO,CD45,CD68	AML
Srinivasan et al. (2008) ⁹	77/M	Indurated ulcer	Lower lip	No	HSHS - chloroacetate esterase, Ki67 (50%)	AML
Cheng, Tzen, Ji (2009) ⁵⁸	56/M	Mass	Buccal mucosa	Yes	IHC - MPO,CD46	AML
Kim et al. (2009) ²⁷	4/F	Facial swelling	mandible	Yes	IHC - MPO,CD34,CD43, CD79A,	AML
Ostern et al.(2009) ⁸	23/F	Tumor	Mandible	NR	IHC - MPO,CD45,CD68	AML
Fasanmade et al.(2010) ⁴	75/F	Erythema and gingival recession and bone loss	Mandibular gingiva	Yes	IHC - CD34,CD68,CD117	MF
Papamantios et al.(2010) ¹⁰	70/F	ulcerated mass	mandible	No	IHC - MPO,CD43, lysozyme	AML
Pau et al.(2010) ²⁴	NR	reddish swelling	maxilla	Yes	IHC - MPO, CD14,CD45RO, CD66,CD68, lysozyme	CML
Silva-Santos et al.(2010) ²⁵	47/F	gingival overgrowth	maxillary and mandibular gingiva	NR	IHC – MPO,lysozyme,TdT	CML
Seema et al. (2011) ⁵⁹	5/M	soft tissue swelling	mandible	Yes	IHC - MPO,TdT	AML
Colovic et al.(2011) ⁶⁰	52/F	swelling	mandible	NR	IHC- CD13,CD68,CD117, lysozyme,HLA-DR, Ki67 (90%), LCA	AML
Yoon et al.(2012) ⁶¹	2/M	swelling	maxillary sinus, maxilla and lip	Yes	IHC - MPO,CD99,vimentin	AML
Zhou, Bell, Medeiros(2012) ⁶²	77/F	lesion with bleeding	tongue	NR	IHC- MPO,CD4, CD11c,CD33, CD43,CAE CD68,CD117, CD163, lysozyme	MDS

(Continues)

TABLE 1 (Continued)

References	Age/Sex	Clinical presentation	Location	Radiographic findings	Microscopic diagnosis	Disease
“	55/M	NR	mandible	NR	IHC- MPO,CD43	CML
“	65/F	mass	inner and lower lips	NR	IHC-CD33, CD43, CD45, CD68, CD163,lysozyme	AML
“	55/M	mass	maxillary gingiva	NR	IHC-MPO,CD11c,CD33, CD43,CD68, lysozyme	CML
“	48/M	NR	maxillary and mandibular gingiva	NR	IHC- MPO,CD33,CD43, CD45,CD68, CD117,lysozyme,CAE	MDS
“	77/M	NR	maxillary ridge	NR	IHC-MPO,CD43, lysozyme,CAE	MDS
“	56/M	NR	mandibular gingiva	NR	IHC- MPO,CD4, CD11c,CD33, CD34,CD43, CD45, CD68, CD117, CD163, lysozyme	AML
“	85/F	NR	upper lip	NR	IHC- MPO,CD117, lysozyme	AML
“	17/F	NR	buccal soft tissue	NR	IHC-CD43, CD45,CD68, CD117,lysozyme	AML
Mei, Lin, Chang(2013) ⁶³	56/M	soft and solid mass	cheek and maxillary sinus	Yes	IHC - MPO,CD34, CD45, CD56, CD117,	DF
Kurdoğlu et al.(2013) ⁶⁴	29/F	sessile swelling	maxillary gingiva	No	IHC - MPO,CD117	AML
Kirnauer et al.(2013) ⁶⁵	77/F	swelling	maxillary gingiva	Yes	IHC - MPO, CD15 (30%),CD68, CD117(50%), Ki67 (70-80%)	AML
Guastafierro et al.(2013) ⁶⁶	56/F	swelling	maxilla	NR	IHC - MPO,CD45, CD68, lysozyme	DF
Yamashita et al.(2013) ²³	1/M	bone-like hard tumor	mandible	Yes	IHC - CD45 FC: MPO,CD33, CD65	AML
Moshref et al.(2014) ⁶⁷	45/M	proliferative lesions	maxillary and mandibular gingiva	Yes	IHC - CD117, LCA	DF
Ponnam et al.(2014) ⁶	45/F	swelling	maxillary gingiva	Yes	IHC – MPO,CD45,CD68,CD117,	DF
Sharma et al.(2014) ⁶⁸	9/M	swelling	maxilla	Yes	IHC - MPO,CD31,CD99,vimentin	DF
Wang et al.(2014) ⁶⁹	27/M	mass	buccal mucosa	No	IHC - MPO,CD34,CD68,CD117, TdT	DF
Yap et al.(2014) ⁷⁰	73/M	erythematous and hyperplastic	mandibular gingiva	No	IHC - MPO, lysozyme	AML
“	65/M	raised lesion	maxillary gingiva	Yes	IHC - MPO,CD68, lysozyme	AML
Dineshkumar et al.(2016) ⁷¹	62/F	generalized enlargement	maxillary and mandibular gingiva	Yes	IHC - MPO,CD43	DF
Jin et al.(2016) ²⁸	52/M	swelling	maxillary gingiva	Yes	IHC - MPO, CD34,CD45,CD117	MDS
Sengupta et al.(2016) ⁷²	2/M	circumscribed swelling	mandible	Yes	IHC - CD45; CD68; lysozyme	DF
Kumar et al.(2017) ²²	28/M	swelling	mandible	Yes	IHC - MPO,CD45	DF
“	5/M	swelling and ulceration	mandible	Yes	IHC - MPO,CD34	AML
Andrade et al.(2017) ⁷³	24/F	gingival swelling	mandibular gingiva	No	IHC – MPO,CD99, Ki67(60%)	AML
Gaal, Chisholm, Egbert (2017) ⁷⁴	0/F	facial swelling	maxillary gingiva	Yes	IHC-MPO,CD11b, CD11c,CD13,CD15, CD33,CD64, CD4,CD56,HLA-DR,	AML

(Continues)

TABLE 1 (Continued)

References	Age/Sex	Clinical presentation	Location	Radiographic findings	Microscopic diagnosis	Disease
Nunes et al. – 2017 [†]	81/M	swelling	maxilla	Yes	IHC – MPO	MF
Shen et al. (2018) ⁷⁵	41/F	gingival swelling	maxillary and mandibular gingiva	Yes	IHC – MPO, CD68, CD117, Ki67	DF

ML - Myelomocytic Leukemia; AML - Acute Myeloid Leukemia; CML - Chronic Myeloid Leukemia; MPO-Myeloperoxidase; IHC – Immunohistochemistry; HS – Histochemical Staining; DF - Disease Free; F - Female; M – Male; FC - Flow Cytometry; NR -Not Reported; MF – Myelofibrosis; MDS - Myelodysplastic Syndrome; TdT - Terminal deoxynucleotidyl transferase.

[†]Present case.

[‡]Intraoral cases not detailed.

As the clinical features of this lesion are nonspecific, a diagnosis based only on clinical and radiographic features is difficult, especially in patients with unknown hematological disease. Oral GS can be misdiagnosed as NHL or squamous cell carcinoma.^{6,10} Regarding the analysis of biopsies, Pau *et al.*²⁴ stated that histological examination can be difficult, and distinguishing oral GS from NHL remains the main histopathologic differential diagnosis. However, a careful anamnesis and investigation of the medical history of the patient may help in the oral GS diagnosis. In the present study, the history of hematologic disease was determinant to guide the correct diagnosis.

Microscopically, the tumor mass has diffuse sheets of blast cells, which often show a single file pattern of infiltration in some areas. The blast cells have round or ovoid nuclei, very fine nuclear chromatin, small but distinct nucleoli, and a small to moderate amount of lightly eosinophilic cytoplasm.⁵ Furthermore, diagnosis of GS using only H&E staining is difficult by the diversity of its morphologic features. The use of immunohistochemistry is necessary to help in reaching a definitive diagnosis and in most of the reports it was determinant to the diagnosis. Myeloid cells contain distinctive primary granules that are not seen in lymphomas.²¹ Immunohistochemically, GS tumor cells lack specific B or T cell markers and express myeloid markers as MPO, CD13, CD33, CD117, CD68, neutrophil elastase, and lysozyme. MPO is the most sensitive and specific, with a positive rate of 83.6% to 100.0%.^{5,25} MPO is synthesized early in the differentiation and it is localized in the primary granules of myeloid cells.¹⁸ In the present case report, the lesion had a positive reaction to CD68 and MPO.

The current therapeutic management of GS includes chemotherapy, radiotherapy, or surgical resection.^{10,26,27} The recommended treatment regimen in patients presenting isolated GS or GS presenting concomitantly with AML is conventional AML-type chemotherapy.²⁸ Although some studies have recommended that chemotherapy is more effective than radiotherapy or surgical resection, there is no consensus regarding the management. It was reported that GS associated with chronic myeloid leukemia (CML) or

myelodysplastic syndrome has a worse clinical outcome when compared to MS with AML.²² In addition, GS prognosis may be poor, with survival times varying among different studies.⁵

In the present case, at the time of the dental reference, bone marrow aspiration with immunophenotyping and cytogenetic was performed. There were no signs of acute leukemia transformation. The medical decision of not to perform bone marrow transplantation or acute leukemia like treatment was due to poor performance status (ECOG Performance Status 3) and the age of the patient (81 years). The current case was successfully treated with surgical management and the patient is disease free in the oral cavity and jaw.

CONCLUSION

The diagnosis of GS lesions involving oral regions is based on clinical, microscopic, and immunohistochemical features, as well as the previous history of myeloid neoplasm.


ACKNOWLEDGEMENTS

T. A. Silva and R. A. Mesquita are fellowships of National Council for Scientific and Technological Development (CNPq, # 309322/2015-4). L. F. M. Nunes received scholarship from Ministry of Education and A. L.R. has scholarship from CAPES.

CONFLICTS OF INTEREST

No conflict of interest to disclose. This research did not receive any specific grant from funding agencies in the public or commercial sectors. R.A.M. and T.A.S. are research fellows of CNPq. L.F.M.N. has a scholarship from Brazilian Ministry of Education and A.L.R. has scholarship from CAPES.

ORCID

Tarcília Aparecida Silva DDS, MSc, PhD 
<http://orcid.org/0000-0001-9623-7835>

REFERENCES

1. El-Naggar AK, Chan JKC, Grandis JR, Takata T, Slootweg PJ. *Classification of head and neck tumours*. 2017 4th ed. Lyon: IARC Press:131.
2. Jacobs P, Sellars S. Granulocytic sarcoma preceding leukaemic transformation in myelofibrosis. *Postgrad Med J*. 1985;61:1069–1071.
3. Saleh MN, Rodu B, Prchal JT, De Leon ER. Acute myelofibrosis and multiple chloromas of the mandible and skin. *Int J Oral Maxillofac Surg*. 1987;16:108–111.
4. Fasanmade A, Pring M, Pawade J, Guest P, Bell C. Rapidly progressing mass of anterior mandible following a dental extraction. *Oral Surg Oral Med Oral Pathol Oral Radiol Endod*. 2010;109:330–334.
5. Wang HQ, Li J. Clinicopathological features of myeloid sarcoma: report of 39 cases and literature review. *Pathol Res Pract*. 2016;212:817–824.
6. Ponnamm SR, Srivastava G, Jampani N, Kamath VV. A fatal case of rapid gingival enlargement: case report with brief review. *J Oral Maxillofac Pathol*. 2014;18:121–126.
7. Neiman RS, Barcos M, Bernanr C, et al. Granulocytic sarcoma: a clinical pathologic study of 61 biopsied cases. *Cancer*. 1981;48:1426–1437.
8. Osterne RLV, Brito RGM, Alves APNN, et al. Oral granulocytic sarcoma: a case report. *Med Oral Patol Oral Cir Bucal*. 2009;14:232–235.
9. Srinivasan B, Ethunandan M, Anand R, Hussein K, Ilankovan V. Granulocytic sarcoma of the lips: report of an unusual case. *Oral Surg Oral Med Oral Pathol Oral Radiol Endod*. 2008;105:34–36.
10. Papamantios MK, Kolokotronis AE, Skulakis HE, Fericean AMA, Zorba MT, Matiakis AT. Acute myeloid leukaemia diagnosed by intra-oral myeloid sarcoma. A case report. *Head Neck Pathol*. 2010;4:132–135.
11. Agaimy A, Mueller SK, Harrer T, Bauer S, Thompson LDR. Head and neck Kaposi sarcoma: clinicopathological analysis of 11 cases. *Head Neck Pathol*. 2018:1–6.
12. Silva TDB, Ferreira CBT, Leite GB, Pontes JRM, Antunes HS. Oral manifestations of lymphoma: a systematic review. *Ecancer Med Sci*. 2016;10:1–15.
13. McCord C, Johnson L. Oral manifestations of hematologic disease. *Atlas Oral Maxillofac Surg Clin North Am*. 2017;25:149–162.
14. Kamal R, Dahiya P, Puri A. Oral pyogenic granuloma: various concepts of etiopathogenesis. *J Oral Maxillofac Pathol*. 2012;16:79–82.
15. Kashyap B, Reddy PS, Nalini P. Reactive lesions of oral cavity: a survey of 100 cases in Eluru, West Godavari district. *Contemp Clin Dent*. 2012;3:294–297.
16. Ashok S, Gupta AA, Ashok KP, Mhaske SA. Peripheral ossifying fibroma: a rare case affecting maxillary region. *Indian J Dent*. 2016;7:141–143.
17. Agrawal R, Agrawal S, Agrawal R. A case of peripheral ossifying fibroma with review of literature. *Intl J Prevent Clin Dental Res*. 2016;3:216–220.
18. Amin KS, Ehsan A, McGuff HS, Albright SC. Minimally differentiated acute myelogenous leukemia (AML-M0) granulocytic sarcoma presenting in the oral cavity. *Oral Oncol*. 2002;38:516–519.
19. Colella G, Tirelli A, Capone R, Rubini C, Guastafierro S. Myeloid sarcoma occurring in the maxillary gingiva: a case without leukemic manifestations. *Int J Hematol*. 2005;81:138–141.
20. Tomás Carmona I, CameselleTeijeiro J, Diz Dios P, Fernández Feijoo J, Limeres Posse J. Intra-alveolar granulocytic sarcoma developing after tooth extraction. *Oral Oncol*. 2000;36:491–499.
21. Xie Z, Zhang F, Song E, Ge W, Zhu F, Hu J. Intraoral granulocytic sarcoma presenting as multiple maxillary and mandibular masses: a case report and literature review. *Oral Surg Oral Med Oral Pathol Oral Radiol Endod*. 2007;103:44–48.
22. Kumar P, Singh H, Khurana N, Urs AB, Augustine J, Tomar R. Diagnostic challenges with intraoral myeloid sarcoma: report of two cases and review of world literature. *Exp Oncol*. 2017;39:78–85.
23. Yamashita Y, Isomura N, Hamasaki Y, Goto M. Case of pediatric acute promyelocytic leukemia presenting as extramedullary tumor of the mandible. *Head Neck*. 2013;35:310–313.
24. Pau M, Beham-Schmid C, Zemmann W, Kahr H, Kärcher H. Intraoral granulocytic sarcoma: a case report and review of the literature. *J Oral Maxillofac Surg*. 2010;68:2569–2574.
25. Silva-Santos PS, Silva BSF, Coracin FL, Yamamoto FP, Pinto-Junior DS, Magalhães MG. Granulocytic sarcoma of the oral cavity in a chronic myeloid leukemia patient: an unusual presentation. *Med Oral Patol Oral Cir Bucal*. 2010;15:350–352.
26. Matsushita K, Abe T, Takeda Y, et al. Granulocytic sarcoma of the gingiva: two case reports. *Quintessence Int*. 2007;38:817–820.
27. Kim K, Velez I, Rubin D. A rare case of granulocytic sarcoma in the mandible of a 4-year-old child: a case report and review of the literature. *J Oral Maxillofac Surg*. 2009;67:410–416.
28. Jin S-H, Park G, Youngkyung K, Park JB. Myeloid sarcoma of the Gingiva with myelodysplastic syndrome a case report. *Medicine (Baltimore)*. 2016;95:1–4.
29. Neiman R, Barcos M, Berard C, et al. Granulocytic sarcoma: a clinicopathologic study of 61 biopsies cases. *Cancer*. 1981;48:1426–1437.
30. Hansen LS, Merrell PW, Bainton DF, Taylor KL. Granulocytic sarcoma: an aleukemic oral presentation. *CDA J*. 1982;10:41–46.
31. Conran MJ, Keohane C, Kearney PJ. Chloroma of the mandible: a problem of diagnosis and management. *Acta Paediatr Scand*. 1982;71:1041–1043.
32. Takagi M, Ishikawa G, Kamiyama R. Granulocytic sarcoma of the jaw. *Bull Tokyo Med Dent Univ*. 1983;30:1–7.
33. Reichart PA, van-Roemeling R, Krech R. Mandibular myelosarcoma (chloroma): primary oral manifestation of promyelocytic leukemia. *Oral Surg Oral Med Oral Pathol*. 1984;58:424–427.
34. Castella A, Davey FR, Elbadawi A, Gordon GB. Granulocytic sarcoma of the hard palate: report of the first case. *Hum Pathol*. 1984;15:1190–1192.
35. Timmis DP, Schwartz JG, Nishioka G, Tio F. Granulocytic sarcoma of the mandible. *J Oral Maxillofac Surg*. 1986;44:814–818.

36. Ficarra G, Silverman S, Quivey JM, et al. Granulocytic sarcoma (chloroma) of the oral cavity: a case with a leukemic presentation. *Oral Surg Oral Med Oral Pathol.* 1987;63:709–714.
37. Dreizen S, McCredie KB, Keating MJ. Mucocutaneous granulocytic sarcomas of the head and neck. *J Oral Pathol.* 1987;16:57–60.
38. Barker GR, Sloan P. Maxillary chloroma: a myeloid leukaemic deposit. *Br J Oral Maxillofac Surg.* 1988;26:124–128.
39. De Vicente Rodriguez JC, Lopez Arranz JS, Fresno Forcelledo M. Isolated granulocytic sarcoma: report of a case in the oral cavity. *J Oral Maxillofac Surg.* 1990;48:748–752.
40. Cho JS, Kim E, Jae HR, et al. Mandibular chloroma demonstrated by magnetic resonance imaging. *Head Neck.* 1990;12:507–511.
41. Eisenberg E, Peters E, Krutchkoff DJ. Granulocytic sarcoma (chloroma) of the gingiva. *J Oral Maxillofac Surg.* 1991;49:1346–1350.
42. Stack BC, Ridley MB. Granulocytic sarcoma of the mandible. *Otolaryngol Head Neck Surg.* 1994;110:591–594.
43. Ritter JH, Goldstein NS, Argenyi Z, Wick M. Granulocytic sarcoma: an immunohistologic comparison with peripheral T-cell lymphoma in paraffin sections. *J Cutan Pathol.* 1994;21:207–216.
44. Roth MJ, Medeiros J, Elenitoba-Johnson K, et al. Extramedullary myeloid cell tumors: an immunohistochemical study of 29 cases using routinely fixed and processed paraffin-embedded tissue sections. *Arch Pathol Lab Med.* 1995;119:790–798.
45. Lynch DP, Conlon TO, Maxwell GR, Martinez F. Exophytic gingival mass in a geriatric patient. *Oral Surg Oral Med Oral Pathol Oral Radiol Endod.* 1998;85:5–7.
46. Menasce LP, Banerjee SS, Beckett E, Harris M. Extra-medullary myeloid tumour (granulocytic sarcoma) is often misdiagnosed: a study of 26 cases. *Histopathology.* 1999;34:391–398.
47. Tong ACK, Lam KY. Granulocytic sarcoma presenting as an ulcerative mucogingival lesion: report of a case and review of the literature. *J Oral Maxillofac Surg.* 2000;58:1055–1058.
48. Lee S-S, Kim H-K, Choi S-C, Lee J-II. Granulocytic sarcoma occurring in the maxillary gingiva demonstrated by magnetic resonance imaging. *Seoul Natl Univ Oral Maxillofacial Radiol.* 2001;92:689–693.
49. Jordan RCK, Glenn L, Treseler PA, Regezi JA. Granulocytic sarcoma: case report with an unusual presentation and review of the literature. *J Oral Maxillofac Surg.* 2002;60:1206–1211.
50. Antmen B, Haytac MC, Sasmaz I, et al. Granulocytic sarcoma of gingiva: an unusual case with a leukemic presentation. *J Periodontol.* 2003;74:1514–1519.
51. Asna N, Cohen Y, Ben-Yosef R. Primary radiation therapy for solitary chloroma of the tongue. *Isr Med Assoc J.* 2003;5:452.
52. Stoopler ET, Pinto A, Alawi F, et al. Granulocytic sarcoma: an atypical presentation in the oral cavity. *Spec Care Dentist.* 2004;24:65–69.
53. Koudstaal MJ, Van der Wal KGH, Lam KH, Meeuwis CA, Speleman L, Levin MD. Granulocytic sarcoma (chloroma) of the oral cavity: report of a case and literature review. *Oral Oncol EXTRA.* 2006;42:70–77.
54. Yoon AJ, Pulse C, Cohen LD, et al. Myeloid sarcoma occurring concurrently with drug-induced gingival enlargement. *J Periodontol.* 2006;77:119–122.
55. Goteri G, Ascani G, Messi M, et al. Myeloid sarcoma of the maxillary bone. *J Oral Pathol Med.* 2006;35:254–256.
56. Yinjun L, Jie J, Zhimei C. Granulocytic sarcoma of the gingiva with trisomy 21. *Am J Hematol.* 2006;81:79–80.
57. Mohamedbhai S, Pule M, Conn B, et al. Acute promyelocytic leukaemia presenting with a myeloid sarcoma of the tongue. *Br J Haematol.* 2008;141:565.
58. Cheng CY, Tzen CY, 2 Ji Liu CJ. Buccal granulocytic sarcoma (chloroma). *J Dent Sci.* 2009;4:202–206.
59. Seema S, Jay GR, Devi CS, et al. Granulocytic sarcoma of the oral cavity. *Indian J Cancer.* 2011;48:378–380.
60. Colovic N, Jurisic V, Terzic T, Djordje J, Colovic M. Alveolar granulocytic sarcoma of the mandible in a patient with HIV. *Onkologie.* 2011;34:55–58.
61. Yoon SW, Chung EJ, Kim SY, Ko JH, et al. Multiple extramedullary relapses without bone marrow involvement after second allogeneic hematopoietic stem cell transplantation for acute myeloid leukemia. *Pediatr Transplant.* 2012;16:125–129.
62. Zhou J, Bell D, Medeiros J. Myeloid sarcoma of the head and neck region. *Arch Pathol Lab Med.* 2013;137:1560–1568.
63. Mei KD, Lin YS, Chang SL. Myeloid sarcoma of the cheek and the maxillary sinus regions. *J Chin Med Assoc.* 2013;76:235–238.
64. Kurdoğlu B, Öztemel A, Barış E, Sengüven B. Primary oral myeloid sarcoma: report of a case. *J Oral Maxillofac Pathol.* 2013;17:413–416.
65. Kirnbauer B, Wolfler A, Sill H, Beham, et al. Myeloid sarcoma in the oral cavity; an unusual case of therapy-related myeloid neoplasm. *Intl J Stomatol Occlusion Med.* 2013;6:65–70.
66. Guastafierro S, Falcone U, Colella G. Gingival swelling and pleural effusion: non-leukemic myeloid sarcoma. *Eur J Haematol.* 2013;91:94.
67. Moshref M, Lotfi A, Mashhadi-Abbas F, Kargahi N. Granulocytic sarcoma (chloroma) presenting as multiple sites in oral cavity: report of a case. *Iran J Cancer Prev.* 2014;7:53–57.
68. Sharma A, Singh HP, Gupta AA, et al. Granulocytic sarcoma in non-leukaemic child involving maxillary sinus with long term follow up: a rare case report. *Ann Maxillofac Surg.* 2014;4:90–95.
69. Wang C-C, Chang K-P, Chang M-S, Chen R-Y. Isolated myeloid sarcoma of the buccal region. *Br J Hosp Med.* 2014;75:468–469.
70. Yap M, Hewson I, McLean C, Ciciulla J. Oral myeloid sarcoma: two case reports. *Aust Dent J.* 2014;59:511–515.
71. Dineshkumar T, Suresh V, Ramya R, Rajkumar K. Primary intraoral granulocytic sarcoma: a rare case presenting as generalized gingival enlargement. *J Oral Maxillofac Pathol.* 2016;20:523–526.
72. Sengupta M, Chatterjee U, Majumdar B. *De novo* myeloid sarcoma involving mandible in a child: report of a rare occurrence. *J Oral Maxillofac Pathol.* 2016;20:304–307.

73. Andrade B, Farneze R, Agostini M. Myeloid sarcoma of the oral cavity: a case report and review of 89 cases from the literature. *J Clin Exp Dent*. 2017;9:e1167–e1171.
74. Gaal A, Chisholm K, Egbert M. How rare is an oral presentation of myeloid sarcoma in the infant. *J Oral Maxillofac Surg*. 2017;21: 1–7.
75. Shen Y, Zhao L, Wu Y, Huang P. Multifocal occurrence of intraoral isolated MS in a patient without leukemic presentation: a case report and literature review. *Oral Surg Oral Med Oral Pathol Oral Radiol*. 2018;125:42–48.

How to cite this article: Nunes LFM, Rocha AL, Magalhães GHR, et al. Intraoral granulocytic sarcoma as a manifestation of myelofibrosis: A case report and review of the literature. *Spec Care Dentist*. 2018;1–12. <https://doi.org/10.1111/scd.12325>