

# Research & Reviews: Journal of Medical and Health Sciences

## A Cross-Sectional Study of the Factors Affecting the Periapical Status of Endodontically Treated Teeth

Suelleng Maria Cunha Santos Soares<sup>1</sup>, Janir Alves Soares<sup>1\*</sup>, Márcio Alexandre Homem<sup>1</sup>, José Cristiano Ramos Glória<sup>1</sup>, Rodrigo Dantas Pereira<sup>2</sup>, Manoel Brito-Júnior<sup>3</sup>, Allyson Nogueira Moreira<sup>4</sup>, Cláudia Silami de Magalhães<sup>4</sup>

<sup>1</sup>DDS, MSc, Adjunct Professor, Department of Dentistry, Federal University of Jequitinhonha and Mucuri Valleys, Diamantina, Brazil

<sup>2</sup>MSc, Professor, Dental School, United Universities of the North of Minas - Funorte, Montes Claros, MG, Brazil

<sup>3</sup>MSc, Professor, Department of Dentistry, State University of Montes Claros, Montes Claros, Brazil

<sup>4</sup>DDS, MSc, Associate Professor, Department of Restorative Dentistry, Federal University of Minas Gerais, Belo Horizonte, Brazil

### Research Article

Received date: 12/04/2016  
Accepted date: 04/05/2016  
Published date: 11/05/2016

#### \*For Correspondence

Janir Alves Soares, Department of Dentistry, Federal University of Jequitinhonha and Mucuri Valleys, Diamantina, Brazil.

**E-mail:** janirsoares@msn.com

**Keywords:** Coronal restoration quality, Endodontic treatment, Periapical status, Root canal-filling quality.

#### ABSTRACT

The objective of the study was to evaluate the relation of various clinical and radiographic factors on the periapical status of teeth treated endodontically by postgraduate students. Radiographic and clinical parameters related to root canal fillings, periodontal condition, coronal restorations, caries, endodontic signs and symptoms, and treatment-related complications were evaluated. Bivariate analysis and a multiple logistic regression model were used to analyze the data. In total, 157 endodontically treated teeth in 124 patients were investigated, 86 (54.8%) of which were molars. Radiographically, 136 (86.6%) teeth had periapical normality and 141 (90.5%) were asymptomatic. Only 20 (12.7%) of the root canal fillings were deficient, but 77 (49.1%) coronal restorations were inadequate. Thirty-six (22.9%) teeth had caries, whereas 60 (38.2%) had periodontal disease. Bivariate analysis showed that only the type of caries ( $p = 0.019$ ) and ideal apical limit of the root canal filling ( $p = 0.03$ ) were significantly related to the periapical status. However, multiple logistic regression analysis indicated no significant relationships between the periapical status and the parameters studied. In conclusion teeth treated endodontically by postgraduate students showed high-quality root canal fillings and periapical normality. Moreover, the presence of caries, inadequate coronal restorations, and periodontal disease were not related to periapical status of these teeth.

### INTRODUCTION

The prevalence of periapical lesions in endodontically treated teeth varies from 50% to 80% [1,2]. This high prevalence underlines a serious problem in dental public health and has economic, medical, and ethical repercussions, because such pathology can cause local and systemic complications [3,4].

Epidemiological studies of root canal fillings in different populations worldwide [1,3-10] have emphasized that their poor technical quality is associated with apical periodontitis [3-7,10,11]. Other investigations have also shown a relation between inadequate coronal restorations and high rates of apical periodontitis [5,6,10,12]. Given that coronal restorations protect the contiguous fillings from microleakage of fluids and oral microorganisms [2,12,13], restoration failure allows microbial microinfiltration [12,13] and facilitates root canal infection, in turn affecting periapical health [6,14]. Endodontically treated teeth are also susceptible to caries and periodontal disease, which would change their health status [15-17]. Some studies [3,18] showed a positive relation between extensive caries

in endodontically treated teeth and increased incidence of apical periodontitis. Furthermore, pulpal infection is a risk factor for periodontitis, which can affect the repair of alveolar bone loss [17,19]. However, limited information is available on periodontal condition and other clinical parameters related to periapical status of endodontically treated teeth [15,17,20,21].

Thus, the purpose of this study was to evaluate the relation of various clinical and radiographic factors on the periapical status of teeth treated endodontically by postgraduate students.

## MATERIALS AND METHODS

This cross-sectional study was approved by the Human Research Ethics Committee of the Federal University of Jequitinhonha and Mucuri Valleys (UFVJM). Patients who had received endodontic treatment at the Clinic of Specialization in Endodontics, UFVJM, between 2002 and 2005 were contacted by either telephone or a home visit and invited to participate in the study. Data were collected through anamnesis and clinical and radiographic evaluations. The clinical evaluation was performed by an examiner with previously assessed expertise (SMCSS). Orthoradial periapical radiographs (Ultra-speed film, Eastman Kodak Co., Rochester, NY) were obtained by an experienced professor (JAS) using the bisecting-angle technique and manually processed using the temperature-time technique. Three different examiners with previously assessed expertise performed the radiographic evaluation.

The intraexaminer and interexaminer correlation values were 0.82–0.92 and 0.76–0.80, respectively, as determined by intraclass correlation coefficients. Disagreements were resolved by consensus.

### Clinical and radiographic parameters

The following parameters were analyzed:

I) Age (classified into 4 age groups), gender, type of endodontically treated teeth (topographically classified into 4 groups), and presence of adjacent and opposing teeth to the endodontically treated teeth.

II) Endodontic signs and symptoms (induced or spontaneous painful sensitivity, sinus tract, edema, erythema, and exudation) and treatment-related complications (ledge, perforation, calcified root canal, broken instruments, and overfilling).

III) Coronal restoration

a) Type of material (permanent or temporary).

b) Extension (inlay, onlay, or full crown).

c) Number of involved surfaces ( $\leq 2$  or  $>2$  surfaces).

d) Clinical quality (adequate: intact permanent restoration, appropriate margins, and no fissure during probing; inadequate: permanent restoration with excess material, secondary caries, open margins or fractures, presence of temporary restoration, or no coronal restoration).

e) Radiographic quality (adequate: well-adapted restoration; inadequate: restoration with excess material in contiguous areas, open margins, or recurrent caries).

In the final classification of coronal restoration, clinical and radiographic parameters were simultaneously considered.

f) Intraradicular post (present or absent, length of remaining gutta-percha, and presence of a space between the filling material and the post).

IV) Root canal-filling quality: Three independent examiners assessed the quality of the root canal fillings by developing the periapical radiographs in the dark room, with a 6-fold increase on a millimeter grid. Apical limit, taper, and homogeneity were graded according to ideal or altered scores. The combination of these scores defined the quality of root canal fillings, as illustrated in **Figure 1**.

V) Periapical status: The periapical status was assessed radiographically as follows:

a) Normal (no change or the apical periodontal ligament space does not exceed twice the lateral periodontal ligament space).

b) Periapical lesion (periapical radiolucency exceeding at least twice the lateral periodontal ligament space).

VI) Caries: Teeth were classified according to the presence or absence of caries, type of caries (primary or secondary), degree of involvement of mineralized structures (enamel and dentin), presence or absence of cavitation, and activity (active or inactive).

VII) Periodontal condition: Four surfaces (vestibular, lingual/palatine, mesial, and distal) were examined. Altogether, 6 positions for the anterior teeth and premolars and 8 positions for the molars were evaluated and higher values or worse condition were considered at each location. The results were classified as follows:

a) Visible plaque<sup>(22)</sup> (absent: no visible plaque in every evaluated region; present: visible plaque in at least 1 position).

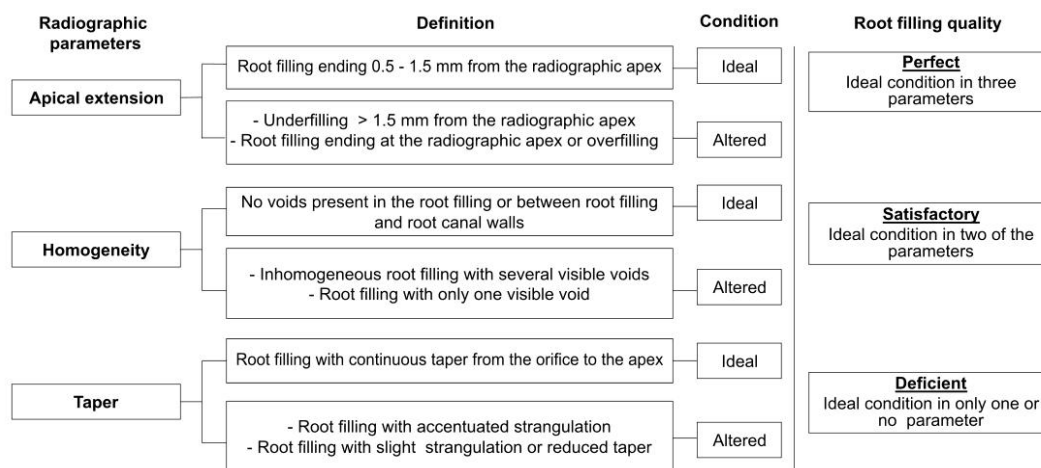


Figure 1. "Drawing of root filling quality standard as a function of radiographic parameters<sup>(11)</sup>."

- b) Bleeding on probing<sup>(1)</sup> (present: visible bleeding until 15 s after probing in at least 1 position; or absent).
- c) Degree of mobility<sup>(15)</sup> (absent or present).
- d) Furcation involvement<sup>(15)</sup> (absent or present).
- e) Periodontal disease<sup>23</sup> (present: tooth simultaneously presenting probing depth  $\geq 4$  mm and insertion loss  $\geq 3$  mm at 1 or more sites; absent).

In this study, the tooth was considered a sample unit. Therefore, for multirooted teeth, the periapical status and condition of the root canal with the worst root filling quality were evaluated. Endodontic treatment was deemed clinically successful if induced or spontaneous painful symptoms were absent and contiguous tissues were normal. Radiographic success was based on the normality of the apical periodontal ligament space. The combination of the clinical and radiographic evaluations determined the success or failure of the treatment.

## STATISTICAL ANALYSIS

The data were initially analysed by a descriptive approach, using frequency distributions. Pearson's chi-square and Fisher's exact tests were used to identify the potential relations between the dependent variable (periapical status) and the independent variables. Then, multivariate forward logistic regression analysis was performed to verify the possible relations between these variables and the periapical status of the endodontically treated teeth. The level of significance was set at 5% ( $p < 0.05$ ).

## RESULTS

The study included 124 patients (35 men and 86 women; age range, 19–65 years; mean  $39.9 \pm 11.5$ ). In total, 157 endodontically treated teeth were evaluated, including anterior teeth (17.2%), premolars (28%), maxillary molars (26.1%), and mandibular molars (28.7%). Radiographically, 136 (86.6%) teeth had periapical normality; therefore, periapical lesions were infrequent (21 [13.4%] teeth;  $p = 0.001$ ). About 20.0% of the teeth had some treatment-related complications.

The root canal-filling quality was significantly related to the type of endodontically treated teeth ( $p = 0.001$ ): 63% of the anterior teeth had perfect root fillings, whereas 17.1% of the maxillary molars had deficient root fillings ( $p < 0.05$ ). However, the quality of the root filling did not affect the periapical status ( $p = 0.858$ ; **Table 1**). Further, the 3 filling quality-related parameters frequently had high ideal scores ( $p > 0.05$ ), but only the ideal apical limit was significantly related to the periapical status ( $p = 0.03$ ; **Table 1**).

Table 1. Influence of independent variables in the periapical status of endodontically treated teeth.

Variables		Periapical Status		p-value*
		Normal n (%)	Lesion n (%)	
Gender	Male	30 (85.7)	5 (14.3)	0.59
	Female	79 (88.8)	10 (11.2)	
Age	19-29	19 (76.0)	6 (24.0)	0.55
	30-39	28 (93.3)	2 (6.7)	
	40-49	33 (86.8)	5 (13.2)	
	>50	29 (93.5)	2 (6.5)	
Tooth groups	Anterior	26 (96.3)	1 (3.7)	0.27
	Premolars	39 (88.6)	5 (11.4)	
	Mandibular molars	38 (84.4)	7 (15.6)	
	Maxillary molars	33 (80.5)	8 (19.5)	

Adjacent teeth	Present	131 (87.3)	19 (12.7)	0.23
	Absent	5 (71.4)	2 (28.6)	
Opposite teeth	Present	126 (86.3)	20 (13.7)	0.55
	Absent	10 (90.9)	1 (9.1)	
Signs and symptoms	Present	14 (93.3)	1 (6.7)	0.69
	Absent	122 (85.9)	20 (14.1)	
	Absent	108 (86.4)	17 (13.6)	
Complicating factors	Separated	18 (81.8)	4 (18.2)	0.37
	Combined	10 (100.0)	0 (0.0)	
	Perfect	60 (87.0)	9 (13.0)	
Quality of filling	Satisfactory	58 (85.3)	10 (14.7)	0.85
	Deficient	18 (90.0)	2 (10.0)	
Apical limit	Ideal	79 (84.0)	15 (16.0)	0.03
	Altered	57 (90.5)	6 (9.5)	
Homogeneity	Ideal	127 (86.4)	20 (13.6)	0.9
	Altered	9 (90.0)	1 (10.0)	
Taper	Ideal	108 (88.5)	14 (11.5)	0.29
	Altered	28 (80.0)	7 (20.0)	

\* Fischer's exact test

The coronal restoration-related parameters did not significantly alter the periapical status ( $p > 0.05$ ; **Table 2**). Therefore, no relations were observed on quality of root canal filling/restoration with the periapical status ( $p > 0.05$ ). With regard to caries, only the type of caries was significantly related to the periapical status ( $p = 0.01$ ; **Table 3**). Periodontal disease was diagnosed in 38.2% of the endodontically treated teeth; however, no periodontal condition-related parameters were significantly related to the periapical status ( $p > 0.05$ ).

**Table 2.** Association between clinical and radiographic findings of the coronal restoration and respective periapical status.

Variables		Periapical Status		p-value*
		Normal n(%)	Lesion n(%)	
Occurrence	Present	114 (87.0)	17 (13.0)	0.74
	Absent	22 (84.6)	4 (15.4)	
Type	Permanent	99 (86.8)	15 (13.2)	0.93
	Temporary	15 (88.2)	2 (1.8)	
Surfaces	$\leq 2$	23 (92.0)	2 (8.0)	0.41
	$> 2$	91 (85.8)	15 (14.2)	
Extension	Intracoronal	31 (88.6)	4 (11.4)	0.87
	Onlay	30 (83.3)	6 (16.7)	
	Full crown	53 (88.3)	7 (11.7)	
Quality	Adequate	71 (88.8)	9 (11.3)	0.42
	Inadequate	65 (84.4)	12 (15.6)	
Intracanal post	Present	38 (82.6)	8 (17.4)	0.34
	Absent	98 (88.3)	13 (11.7)	
Visible space between the gutta percha and intracanal post	Present	29 (87.9)	4 (12.1)	0.19
	Absent	9 (69.2)	4 (30.8)	
Remaining gutta percha apical	$\geq 4$	31 (83.8)	6 (16.2)	0.64
	$< 4$	7 (77.8)	2 (22.2)	

\*Fischer's exact test

**Table 3.** Association between periodontal parameters and caries and respective periapical status.

	Variables		Periapical Status		p-value*
			Normal n (%)	Lesion n (%)	
Periodontal parameters	Visible plaque	Present	97 (87.4)	14 (12.6)	0.66
		Absent	39 (84.8)	7 (15.2)	
	Bleeding upon probing	Present	124 (85.5)	21 (14.5)	0.15
		Absent	12 (100.0)	0 (0.0)	
	Mobility	Present	31 (86.1)	5 (13.9)	0.91
		Absent	105 (86.8)	16 (13.2)	
	Furcation involvement	Present	7 (77.8)	2 (22.2)	0.42
		Absent	129 (87.2)	19 (12.8)	
	Periodontal disease	Present	52 (86.7)	8 (18.3)	0.99
		Absent	84 (86.6)	13 (13.4)	
	Type	Primary	5 (55.6)	4 (44.4)	0.01
		Secondary	24 (88.9)	3 (11.1)	

Caries	Activity	Inactive	12 (80.0)	3 (20.0)	0.47
		Active	17 (81.0)	4 (19.0)	
	Involvement	Enamel	3 (75.0)	1 (25.0)	0.44
		Dentin	26 (81.3)	6 (18.7)	
	Cavity	Present	19 (86.4)	3 (13.6)	0.2
		Absent	10 (71.4)	4 (28.6)	

\* Fischer's exact test

## DISCUSSION

In the present study, contrary to other investigations <sup>[1,2,7,10]</sup>, low prevalence of periapical lesions (13.4%), deficient root canal fillings (12.7%), and symptomatic teeth (9.5%) were observed. Furthermore, 44% of the root canal fillings had ideal scores in all the quality-related parameters, and 44.3% had altered scores only one parameter; therefore, 88.3% of these fillings presented high technical quality. The prevalence of periapical normality (~86.6%) was similar to that in other studies carried out in similar settings with standardized clinical protocols <sup>[11,21-24]</sup>. The prevalence of treatment-related complications was 20%, which could be explained by the fact that approximately 55% of the endodontic treatments were performed in molars, whose complex root canal anatomy would be technically challenging for the operator <sup>[2,24]</sup>. These results have been largely attributable to the skill of postgraduate students. Endodontic treatment performed by specialists is generally assumed to be of better quality and more successful than that performed by general practitioners or graduate students <sup>[5,24]</sup>. Nevertheless, Kereks and Tronstad<sup>18</sup> showed high-quality root canal fillings in treatments performed by students who followed standardized clinical protocols.

With regard to the parameters influencing the technical quality of the root canal fillings, 93.6% of the teeth had the ideal homogeneity, 77.7% had the ideal taper, and 59.8% had the ideal apical limit. However, bivariate analysis showed that only the ideal apical limit was significantly related to the periapical status, confirming previous outcomes <sup>[2,21]</sup>.

Corroborating the findings of Kirkevang et al. <sup>[23]</sup> and Ørstavik et al. <sup>[25]</sup>, no significant relation was observed between the periapical status and the root canal-filling quality or type of teeth. Similarly, Sidaravicius et al. <sup>[40]</sup> found that the quality of the root filling has little impact on the periapical status of endodontically treated teeth, except for cases of overfillings. Moreover, Chen et al. <sup>[3]</sup> showed that properly root-filled teeth have a similar rate of periapical lesions to those with deficient root fillings.

Analysis of the parameters related to coronal restorations revealed that 49.1% of the restorations were clinically and radiographically inadequate, and among these, 33.7% were absent. However, none of these parameters was significantly related to the periapical status of the teeth, as previously reported <sup>[3,5,6,17]</sup>. Conversely, other studies showed a significant effect of the coronal restoration quality on periapical normality <sup>[10,12,18]</sup>. In the present study, only 4 (15.4%) teeth without coronal restorations had periapical lesions, confirming the results found in previous investigations <sup>[10,26]</sup>. With regard to the presence of intraradicular posts or space between the posts and the filling material, no significant differences were found in the periapical status of the teeth. Eventually, this space might have developed in most of the teeth (80.4%), which had remaining gutta-percha with satisfactory length (>4 mm) <sup>[20,27,28]</sup>.

In addition, the quality of the coronal restorations had no relation with the periapical status of the teeth, again confirming previous findings <sup>[29,30]</sup>. Siqueira Jr et al. <sup>[14]</sup> observed that the coronal restoration quality affected the periapical status of inadequately root-filled teeth or those without restorations. However, a significant prevalence of periapical lesions has also been observed in adequately root-filled teeth. Considering this, coronal restoration-related parameters have almost no relation with the presence of periapical lesions in adequately root-filled teeth. In vitro studies have shown bacterial microleakage in root canal fillings when the coronal seal is inadequate <sup>[13,20]</sup>. However, for the development of a pathological periapical process, it would be necessary to consider the interaction between the amount of microorganisms, their virulence capacities, and the immunological defense mechanisms of the patient <sup>[26]</sup>.

Periodontal and periapical lesions have similar microbiota and pathophysiology, in addition to the communication links between the periodontium and the endodontium. Therefore, cross-infection between these environments might occur <sup>[17]</sup>. In this study, approximately 40% of the endodontically treated teeth had periodontal disease. However, similar to previous observations <sup>[21,25]</sup>, none of the periodontal condition-related parameters was related to the periapical status. On the other hand, Chen et al. <sup>[3]</sup> and Stassen et al. <sup>[17]</sup> showed that the presence of apical periodontitis dictates the severity of horizontal bone loss and periodontal attachment.

In this study, primary caries were significantly related to the periapical status of the endodontically treated teeth, confirming the results of Kirkevang, et al. <sup>[23]</sup>. Although the teeth radiographically presented high-quality root canal fillings, microorganisms in the carious lesions might have infiltrated the root canal system to reach the periapex and cause lesions <sup>[3]</sup>. In a recent study, teeth with caries extending to the pulp chamber presented a high incidence of periapical lesions [3]. Although caries and periodontal disease represent the foci of infection in dental tissues, the lack of a relation between periodontal disease and the periapical status, when compared with caries, could be explained by the protective effect of the immune system in inhibiting the entry of periodontal microorganisms and their toxins into the periapex. However, multivariate logistic regression analysis showed that the periapical status of the teeth studied did not relate with any of the investigated clinical and radiographic parameters.

## **CONCLUSION**

The teeth treated endodontically by postgraduate students had high-quality root canal fillings and periapical normality. The clinical and radiographic factors such as caries, coronal restorations, and periodontal condition showed slight or no relation with the periapical status of these teeth..

## **REFERENCES**

1. Gumru B, et al. Retrospective radiological assessment of root canal treatment in young permanent dentition in a Turkish subpopulation. *Int Endod J.* 2011;44:850-856.
2. Touré B, et al. Prevalence and technical quality of root fillings in Dakar, Senegal. *Int Endod J.* 2008;41:41-49.
3. Chen CY, et al. Prevalence and quality of endodontic treatment in the Northern Manhattan elderly. *J Endod.* 2007;33:230-234.
4. De Cleen MJ, et al. Periapical status and prevalence of endodontic treatment in an adult Dutch population. *Int Endod J.* 1993;26:112-119.
5. Dugas NN, et al. Periapical health and treatment quality assessment of root-filled teeth in two Canadian populations. *Int Endod J.* 2003;36:181-192.
6. Gündüz K, et al. Cross-sectional evaluation of the periapical status as related to quality of root canal fillings and coronal restorations in a rural adult male population of Turkey. *BMC Oral Health.* 2011;11:1-6.
7. Jansson L, et al. The influence of endodontic infection on progression of marginal bone loss in periodontitis. *J Clin Periodontol.* 1995;22:729-734.
8. Lopes NJ, et al. Periodontal therapy may reduce the risk of preterm low birth weight in women with periodontal disease: a randomized controlled trial. *J Periodontol.* 2002;3:911-924.
9. Santos SM, et al. Radiographic quality of root canal fillings performed in a postgraduate program in endodontics. *Braz Dent J.* 2010;21:315-321.
10. Sidaravicius B, et al. Endodontic treatment and prevalence of apical periodontitis in an adult population of Vilnius, Lithuania. *Endod Dent Traumatol.* 1999;15:210-215.
11. Santos SM, et al. Radiographic parameters of quality of root canal fillings and periapical status: a retrospective cohort study. *J Endod.* 2010;36:1932-1937.
12. Ray HA and Trope M. Periapical status of endodontically treated teeth in relation to the technical quality of the root filling and the coronal restoration. *Int Endod J.* 1995;28:12-8.
13. Saunders WP and Saunders EM. Coronal leakage as a cause of failure in root canal therapy: a review. *Endod Dent Traumatol.* 1994;10:105-108.
14. Siqueira JF, et al. Periradicular status related to the quality of coronal restorations and root canal fillings in a Brazilian population. *Oral Surg Oral Med Oral Pathol Oral Radiol and Endod.* 2005;100:369-374.
15. Hamp SE, et al. Periodontal treatment of multirrooted teeth. Results after 5 years. *J Clin Periodontol.* 1975;3:126-135.
16. Imura N, et al. The outcome of endodontic treatment: a retrospective study of 2000 cases performed by a specialist. *J Endod.* 2007;33:1278-1282.
17. Stassen IG, et al. The relation between apical periodontitis and root-filled teeth in patients with periodontal treatment need. *Int Endod J.* 2006;39:299-308.
18. Kerekes K and Tronstad L. Long-term results of endodontic treatment performed with a standardized technique. *J Endod.* 1979;5:83-90.
19. Ehnevid H, et al. Periodontal healing in teeth with periapical lesions – a clinical retrospective study. *J Clin Periodontol.* 1993;4:254-258.
20. Mavec JC, et al. Effects of an intracanal glass ionomer barrier on coronal microleakage in teeth with post space. *J Endod.* 2006;32:120-122.
21. Sjögren U, et al. Factors affecting the long-term results of endodontic treatment. *J Endod.* 1990;16:498-504.
22. Ainamo J and Bay I. Problems and proposals for recording gingivitis and plaque. *Int Dent J.* 1975;25:229-235.
23. Kirkevang LL, et al. Risk factors for developing apical periodontitis in a general population. *Int Endod J.* 2007;40:290-299.
24. Hoskinson SE, et al. A retrospective comparison of outcome of root canal treatment using two different protocols. *Oral Surg Oral Med Oral Pathol Oral Radiol Endod.* 2002;93:705-715.
25. Ørstavik D, et al. A multivariate analysis of the outcome of endodontic treatment. *Eur J Oral Sci.* 2004;112:224-230.

26. Ricucci D, et al. Periapical status of root-filled teeth exposed to the oral environment by loss of restoration or caries. *Oral Surg Oral Med Oral Pathol Oral Radiol Endod.* 2000;90:354-359.
27. López-López J, et al. Frequency and distribution of root-filled teeth and apical periodontitis in an adult population of Barcelona, Spain. *Int Dent J.* 2012;62:40-46.
28. Matsumoto T, et al. Factors affecting successful prognosis of root canal treatment. *J Endod.* 1987;13:239-242.
29. Heling I, et al. The outcome of teeth with periapical periodontitis treated with nonsurgical endodontic treatment: a computerized morphometric study. *Quint Int.* 2001;32:397-400.
30. Kamberi B, et al. Prevalence of apical periodontitis and endodontic treatment in a Kosovar adult population. *BMC Oral Health.* 2011;11:1-6.