

## Bioinformatics Analysis Reveals Genes Involved in the Pathogenesis of Ameloblastoma and Keratocystic Odontogenic Tumor

Eliane Macedo Sobrinho Santos<sup>1,2</sup>, Hércules Otacílio Santos<sup>3</sup>, Ivoneth dos Santos Dias<sup>4</sup>, Sérgio Henrique Santos<sup>5</sup>, Alfredo Maurício Batista de Paula<sup>1</sup>, John David Feltenberger<sup>6</sup>, André Luiz Sena Guimarães<sup>1</sup>, Lucyana Conceição Farias<sup>1\*</sup>

1. Department of Dentistry, Universidade Estadual de Montes Claros, Minas Gerais, Brazil.
2. Instituto Federal do Norte de Minas Gerais-Campus Araçuaí, Minas Gerais, Brazil.
3. Instituto Federal do Norte de Minas Gerais-Campus Salinas, Minas Gerais, Brazil.
4. Department of Biology, Universidade Estadual de Montes Claros, Minas Gerais, Brazil.
5. Department of Pharmacology, Universidade Federal de Minas Gerais, Brazil.
6. Texas Tech University Health Science Center, Lubbock, TX, USA.

Submitted 10 August 2016; Accepted 10 October 2016; Published 6 December 2016

Pathogenesis of odontogenic tumors is not well known. It is important to identify genetic deregulations and molecular alterations. This study aimed to investigate, through bioinformatic analysis, the possible genes involved in the pathogenesis of ameloblastoma (AM) and keratocystic odontogenic tumor (KCOT). Genes involved in the pathogenesis of AM and KCOT were identified in GeneCards. Gene list was expanded, and the gene interactions network was mapped using the STRING software. “Weighted number of links” (WNL) was calculated to identify “leader genes” (highest WNL). Genes were ranked by K-means method and Kruskal-Wallis test was used ( $P < 0.001$ ). Total interactions score (TIS) was also calculated using all interaction data generated by the STRING database, in order to achieve global connectivity for each gene. The topological and ontological analyses were performed using Cytoscape software and BinGO plugin. Literature review data was used to corroborate the bioinformatics data. *CDK1* was identified as leader gene for AM. In KCOT group, results show *PCNA* and *TP53*. Both tumors exhibit a power law behavior. Our topological analysis suggested leader genes possibly important in the pathogenesis of AM and KCOT, by clustering coefficient calculated for both odontogenic tumors (0.028 for AM, zero for KCOT). The results obtained in the scatter diagram suggest an important relationship of these genes with the molecular processes involved in AM and KCOT. Ontological analysis for both AM and KCOT demonstrated different mechanisms. Bioinformatics analyzes were confirmed through literature review. These results may suggest the involvement of promising genes for a better understanding of the pathogenesis of AM and KCOT.

**Key words:** Ameloblastoma, keratocystic odontogenic tumor, cell proliferation, apoptosis, leader gene

---

\*Corresponding author: Universidade Estadual de Montes Claros Hospital Universitário Clemente de Faria Laboratório de Pesquisa em Saúde Avenida Cula Mangabeira, 562 Montes Claros, Minas Gerais, Brasil. E-mail: lucyanacfarias@gmail.com

Odontogenic tumors consist of a heterogeneous group of lesions that originate from the tissue that forms the teeth (1). These tumors affect individuals in different age groups, involving mandibular and maxillary region, with central or peripheral location. Some lesions are asymptomatic and are discovered by chance through routine radiographs. Additionally, odontogenic tumors could promote the local expansion or facial swelling (2, 3). Pathogenesis of odontogenic tumors is not well known. Several studies were performed to identify genetic deregulations and molecular alterations in an attempt to explain the mechanisms of oncogenesis, cytodifferentiation, and tumor progression (3, 4).

Ameloblastoma (AM) is a benign tumor originating in the odontogenic epithelium without ectomesenchyme, affecting the maxillo-mandibular complex (5). It is an asymptomatic lesion, and it presents locally invasive behavior, and higher recurrence rates (6). The differential diagnosis includes a variety of odontogenic cysts and tumors, particularly keratocyst odontogenic tumor and myxoma, non-odontogenic tumors and cysts, as central giant cell lesions and fibro-osseous lesions (7, 8).

The keratocystic odontogenic tumor (KCOT), according to the most recent classification of tumors of the head and neck of the World Health Organization (WHO), has been categorized as benign neoplasm derived from odontogenic epithelium. The great clinical relevance of KCOT is related to aggressive clinical behavior, high recurrence and proliferation rate (9, 10). However, there are still disagreements, questioning whether this odontogenic lesion indeed is a neoplasm or a cyst of odontogenic nature (11). Some studies have sought to understand these aspects through molecular investigations (11, 12).

Despite efforts focused on understanding the pathogenesis of odontogenic tumors, little is known about the real influence of molecular pathways and

gene deregulations in these tumors. Silico approaches, such as bioinformatic analysis, have been performed to investigate signaling pathways, protein interactions, microRNA prediction models, and gene expression to obtain the best understanding of pathological mechanisms of diseases (13). The computational method is an important tool to understand molecular aspects of oral pathology and medicine (14-16).

This study aimed to investigate the differential involvement of protein-coding genes in the pathogenesis of AM and KCOT, through bioinformatics analysis.

## Materials and methods

### Bioinformatics and biological systems analysis

Initially, key genes involved in the pathogenesis of AM and KCOT were identified by searching the GeneCards database (17). The gene nomenclature adopted was defined by Human Genome Organization (HUGO). The keywords, chosen according to Medical Subject Headings (MeSH), were “ameloblastoma and gene expression” and “keratocystic odontogenic tumor and gene expression”.

After this step, a list of potential “candidate genes” related to AM and KCOT was generated to each tumor. Then, this gene list was expanded using the web-available software STRING (version 9.1) (14), mapping the interaction network between these protein-coding genes. Direct and indirect gene interactions were considered with a high degree of confidence (above 0.9, range 0-0.99) (14). With this process, new genes linked to AM and KCOT could be identified. For every gene interaction identified, we summed the interaction score of each gene, generating a combined association score. This score was adjusted, multiplying it by 1,000 (14), to obtain a single value called weighted number of links (WNL). The genes that showed the largest WNL values were named “leader genes” (14). Total interaction score (TIS) was also calculated using all

interaction data generated by the STRING database to achieve global connectivity for each gene involved in the process (14). The value of WNL/TIS ratio represents the most influential genes in the network (specificity score). Genes with no link (orphan genes) were excluded from this analysis.

Genes were ranked according to this parameter in clusters, by the clustering method K-means. The number of clusters was calculated using the following equation:  $Cluster\ number = TETO (LOG(CONT.NUM(N);2);1)$ . The number of clusters was obtained when mathematical convergence was achieved. To evaluate the differences among various classes based on WNL, Kruskal-Wallis test was used. Statistical significance was set at a p-value <0.001. Interacting genes were classified as up-regulated or down-regulated, as previously described (14), to each type of odontogenic tumor, AM or KCOT. Complementary analysis of biological systems was performed by topological and ontological analysis. The first was carried out with Cytoscape software (18), and ontological analysis was performed with BinGO plugin (14).

#### Literature review

A literature review was performed according to inclusion and exclusion criteria of the Preferred Reporting Items for Systematic Reviews and methodology Meta-Analyses (PRISMA). Literature review data were used to corroborate the bioinformatics data. The main question was "to verify genes that have been associated with AM or KCOT pathogenesis." The primary search was conducted in MEDLINE/PubMed database. The following keywords and their synonyms were used: "ameloblastoma and gene expression" and "keratocystic odontogenic tumor and gene expression." "Gene expression" corresponds to each of the genes obtained from GeneCard and leader genes.

The initial survey of the articles was conducted by three researchers (coauthors)

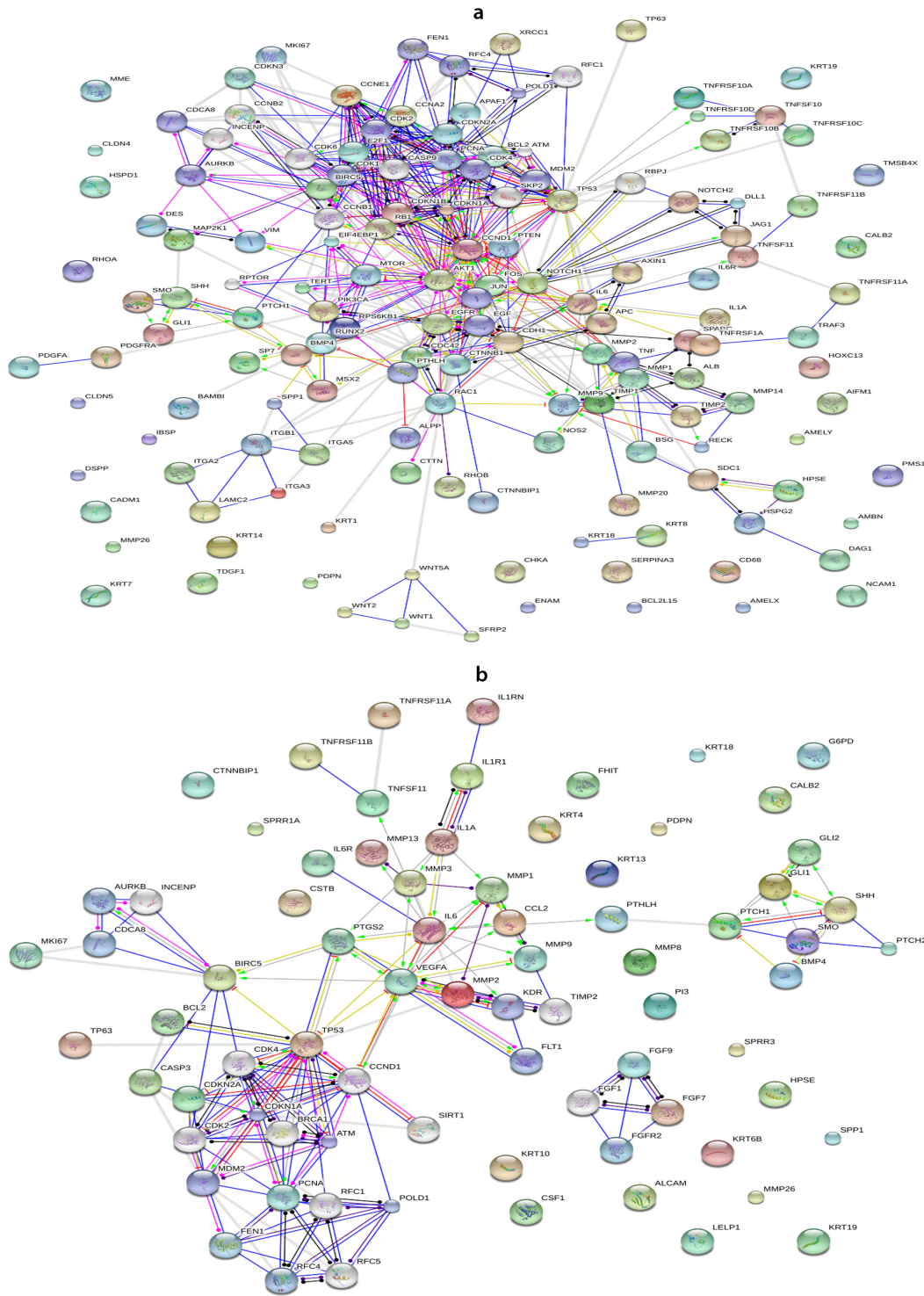
according to the following inclusion criteria: articles published in English, with availability in its full version, whose study has been conducted with laboratory experiments and that addressed the topic of interest. After the initial selection of material, items with incompatible content with the object of the study were excluded. The final research material was made up of 66 selected papers for AM and 25 for KCOT. The synthesis of the collected data and evidence analysis are based on information regarding the characteristics, methods and study endpoints (title, aim, methodological design, sample, results, conclusion and level of evidence).

## Results

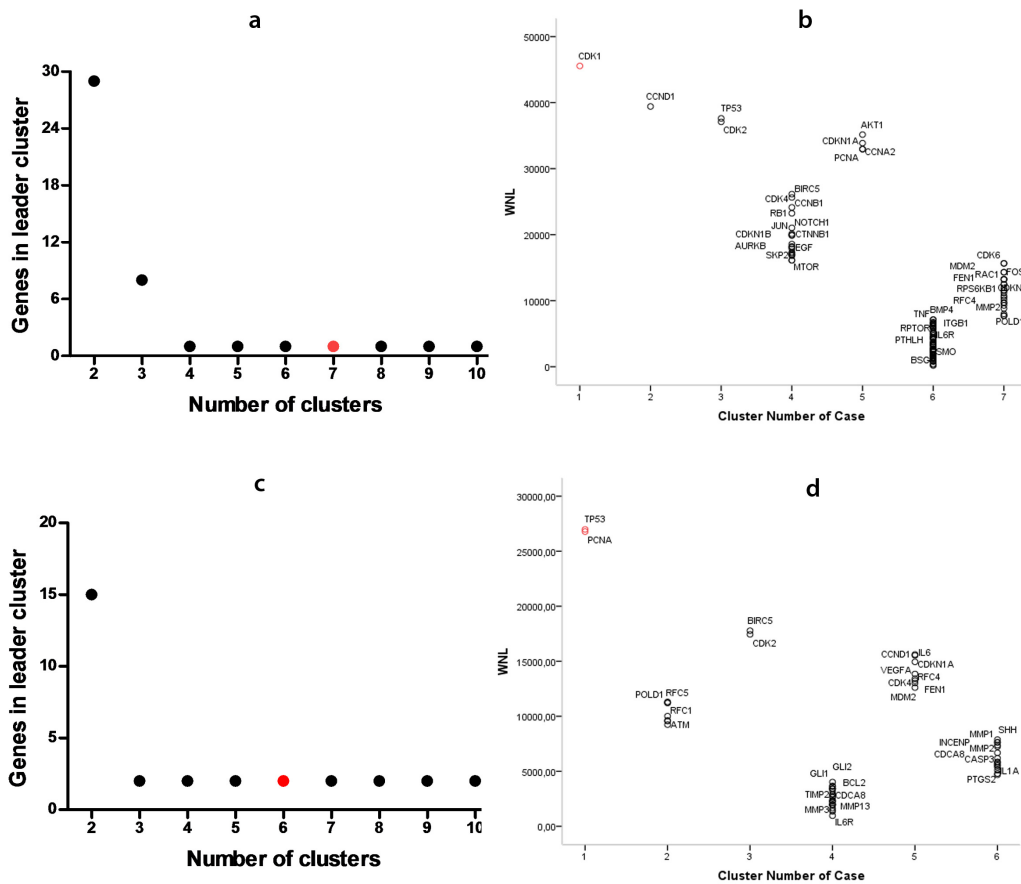
### Survey of genes associated with AM and KCOT pathogenesis and interaction network

The search through GeneCards and String database included 119 genes related to AM and 54 genes related to KCOT. Figures 1a and 1b show gene interaction maps and also increased and decreased gene expression in AM and KCOT, respectively. This figure also reveals the orphan genes. In the gene interaction network for AM, genes were the following: *AIFM1*, *AMBN*, *AMELX*, *AMELY*, *BCL2L15*, *CADMI*, *CALB2*, *CD68*, *CHKA*, *CLDN4*, *CLDN5*, *DSPP*, *ENAM*, *HOTAIR*, *HOXC13*, *HSPD1*, *IBSP*, *KRT14*, *KRT19*, *KRT7*, *MME*, *MMP26*, *NCAMI*, *PDPN*, *PMS1*, *RHOA*, *RUNX2*, *SERPINA3*, *TDGF1*, *TMSB4X*. furthermore, orphan genes in the network for KCOT were *ALCAM*, *CALB2*, *CSF1*, *CSTB*, *CTNNBIP1*, *FHIT*, *G6PD*, *HPSE*, *KRT10*, *KRT13*, *KRT18*, *KRT19*, *KRT4*, *KRT6B*, *LELP1*, *MIR15A*, *MIR16-1*, *MMP26*, *MMP8*, *PDPN*, *PECAMI*, *PI3*, *SPPI*, *SPRRIA*, *SPRR3*.

Data analysis related to clustering and distribution of genes by cluster for AM and KOT diseases are represented in Figure 2. Figures 2a and 2c show the number of genes in the class of leader genes versus the increasing number of clusters; a



**Fig. 1.** Gene interaction map and up- and down were regulated genes involved in ameloblastoma (a) and keratocyst odontogenic tumor (b). Data was derived from STRING (level of confidence > 0.9). Down-regulation is a red bar and up-regulation is a green arrow. Yellow circle represents that the directionality of the interaction is known, but it is not known whether it results from the interaction (e.g., if it is up- or down regulated). Black circle at both ends means some kind of interaction between the two proteins, but the directionality is not known. In deep blue: binding; in blue: phenotype; in indigo blue: catalysis; in violet: post-translation; in black: reaction; and in yellow: expression.



**Fig. 2.** Data analysis of clustering for ameloblastoma (a and b) and keratocyst odontogenic tumor (c and d). Genes belonging to the leader cluster in different k-means clustering experiments with an increasing number of clusters. In red: number of clusters used (a and c); Number of cases in clusters with WNL for genes involved in the phenomenon. In red: gene leader cluster (b and d).

preliminary k-means analysis revealed a cluster number equal to 7 for AM, and 6 for KCOT. Additionally, analysis points to the number of genes belonging to the leader cluster, being 1 for AM, and 2 for KCOT. Figures 2b and 2d show the number of genes in each class, and also demonstrate leader genes for each tumor. The WNL for each gene in the data sets are displayed in Figure 2. In AM, the highest WNL values were identified in genes *CDK1*, *CCND1*, *TP53*, *CDK2*, *AKT1*, *CCNA2*, *PCNA*, *CDKN1A*. Already, in KCOT, the most relevant WNL values were for *TP53*, *PCNA*, *BIRC5*, *CDK2*, *CCND1*, *CDKN1A*, *IL6*, *CDK4*, *VEGFA* genes. Clustering analysis of WNL identified only *CDK1* gene belonging to the largest

cluster for AM. In the KCOT group, results show *PCNA* and *TP53* genes in the largest cluster.

Results were validated using the Kruskal-Wallis test, which revealed a statistically significant difference in WNL. In particular, the statistic analysis showed that leader genes had a significantly greater WNL than other classes of genes ( $P < 0.001$ ). In this analysis, it was noted that both AM and KCOT tumors showed a power law behavior in agreement with the scale-free theory of network (In AM, correlation: 0.891;  $R^2$ : 0.855. In KCOT, correlation: 0.791;  $R^2$ : 0.644)(Figure 3a and 3b). Power law distributions tend to differentiate nodes into specific points, meaning that some nodes have a tendency to have a low value, and consequently few

number of connections, while other nodes, in turn, have a very high degree. In our case, we saw that few genes showed a large number of connections, whereas most of the genes showed few links. In this case, the high degree nodes are leader genes.

### Topological analysis

A clustering coefficient was used to measure the degree of cohesion between the groups of genes. This numeric variable indicates the extent to which a gene is integrated into a given group. Clustering coefficient was close to zero (0.028) for AM, and zero for KCOT, demonstrating the

importance of leader genes in connection between vertices and their neighbors (Table 1). When a gene appears above the regression line and very close to the Y axis, it means that it has a high specificity (WNL) and less global connectivity (TIS) suggesting that it is a leader gene. Figure 4a and 4b show the disease-related connectivities (WNL) versus the global connectivities (TIS). The WNL/TIS ratio indicated that the leader genes from AM (CDK) and KCOT (*PCNA* and *TP53*) were influential genes in the interaction networks.

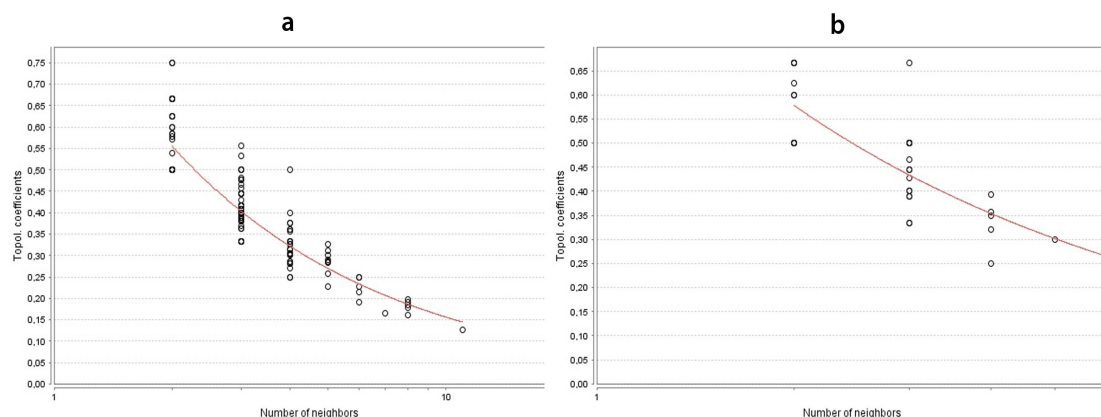
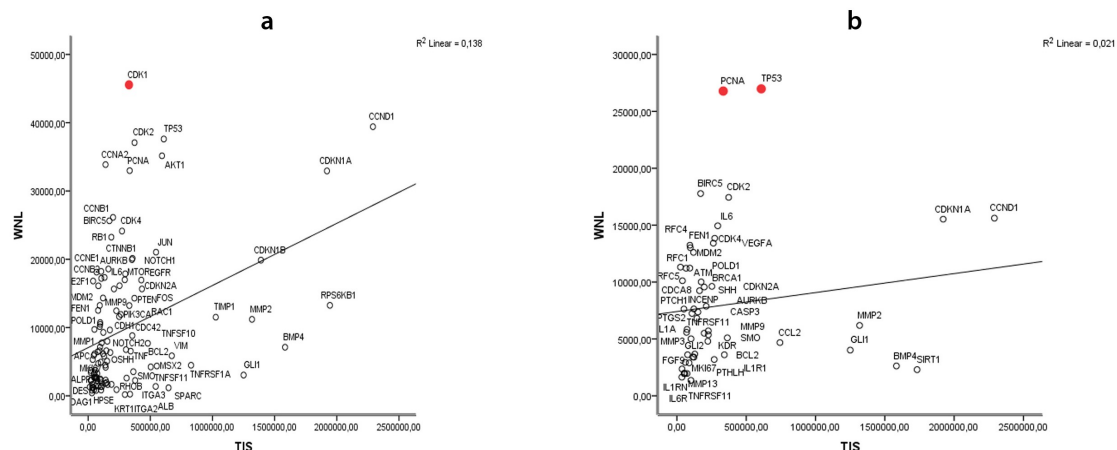


Fig. 3. Power law behavior. a: ameloblastoma; b: keratocystic odontogenic tumor

Table 1 Global topological analysis for Ameloblastoma and Keratocystic odontogenic tumor network.

Parameter	Value	Parameter	Value
<b>Ameloblastoma</b>			
Clustering coefficient	0.028	Number of nodes	150
Connected components	1	Network density	0.021
Network diameter	13	Network heterogeneity	0.510
Network radius	7	Isolated nodes	0
Network centralization	0.053	Number of self-loops	0
Shortest paths	13574 (100%)	Multi-edge node pairs	0
Characteristic path length	5.924	Analysis time (sec)	0.250
Avg. number of neighbors	3.187	-	-
<b>Keratocystic odontogenic tumor</b>			
Clustering coefficient	0.0	Number of nodes	34
Connected components	1	Network density	0.087
Network diameter	12	Network heterogeneity	0.355
Network radius	6	Isolated nodes	0
Network centralization	0.100	Number of self-loops	0
Shortest paths	1122 (100%)	Multi-edge node pairs	0
Characteristic path length	4.750	Analysis time (sec)	0.035
Avg. number of neighbors	2.882	-	-



**Fig. 4.** Scatter diagrams showing disease-related connectivities (WNL: weighted number of links) versus the global connectivities (TIS: total interactions score). a: ameloblastoma; b: keratocystic odontogenic tumor

**Ontological analysis**

The ontology for both AM and KCOT demonstrated different mechanisms associated to AM and KCOT (Figure 5a and 5b, respectively). In AM, aspects such as cell cycle process, regulation of cell cycle, regulation of mitotic cell cycle, interphase of mitotic cell cycle were relevant. In KCOT, regulation of DNA metabolic processes, mitotic cell cycle regulation, cell cycle regulation, as well as cellular response to a stimulus, cellular response to stress, and response to DNA damage were relevant. The mechanism of cell cycle regulation, for both AM and KCOT, was observed

to be an outcome measure along with proliferation and anti-apoptotic mechanisms.

**Literature review**

Studies have demonstrated several genes related to AM and KCOT, but in literature, many controversies exist over whether it is involved in disease progression or, conversely, in tumor inhibition. So, we performed a short overview of literature regarding potentially involved genes and their expression in the pathogenesis of AM and KCOT. Expression levels (increase or decrease) of different genes were identified in this study, for both AM and KCOT, as summarized in Table 2.

**Table 2.** Gene expression in Ameloblastoma and Keratocystic odontogenic tumor according to the literature review.

Gene symbol	Level	In comparison of	Methodology	Ref.
<b>AMELOBLASTOMA</b>				
CDK1	Expression of CDK1,-4, and - 6 was not changed, even with the induced overexpression of AMBN.	Primary dental epithelium bound to full-length AMBN	PCR and Western Blotting	(19)
CCND1	Increase	Keratocysts	Immunohistochemistry	(20)
TP53	Increase	Adenomatoid odontogenic tumor	Immunohistochemistry	(21)

CDK2	Overexpressed	Dentigerous cyst	Microarray analysis, RT-PCR, and immunohistochemistry	(22)
	No changed	No control group	Microarrays and immunohistochemistry	(23)
AKT1	Decrease	Under treatment of TNF $\alpha$	Western blot/ Apoptosis assay/ DAPI staining	(24)
	Increase	Ameloblastoma tissues	Immunohistochemistry/ Immunoblotting/Immunofluorescence/ELISA	(21)
PCNA	Increased	Odontogenic keratocyst	Immunohistochemistry	(25)
CDK4	Increase	Rodent dental epithelial cell lines	Immunofluorescence/ immunohistochemistry	(26)
RB1	Increase	Cystic odontogenic tumor (CCOT)	PCR	(27)
JUN	Increase	Normal oral mucosa	<i>In situ</i> hybridization	(28)
CTNNB1	Increase	Oral basal cell carcinoma	Immunohistochemistry	(29)
NOTCH1	Decrease	Tooth germ	Immunohistochemistry/ PCR Real Time	(30)
	High	No comparison	Immunohistochemistry	(31)
MTOR	Increase	Dentigerous cysts (DCs), odontogenic keratocysts (OKCs)	Immunohistochemistry	(32)
EGFR	No expression	Normal oral mucosa	Immunohistochemistry	(33)
	Increase	Inflammatory cyst	Immunohistochemistry	(34)
E2F1	High	None	Immunohistochemistry	(35)
	Increase	Tooth germs	Immunohistochemistry	(36)
FOS	Increased	Other genes	Real-time PCR	(12)
MDM2	Increased	Adenomatoid odontogenic tumor	Immunohistochemistry	(37)
RAC1	No expression	None	Immunohistochemistry	(38)
PTEN	Decrease	Tooth germs	Immunohistochemistry	(39)
MMP9	Strongly expressed in mural, moderately in intraluminal, and weakly to	None	Immunohistochemistry	(40)

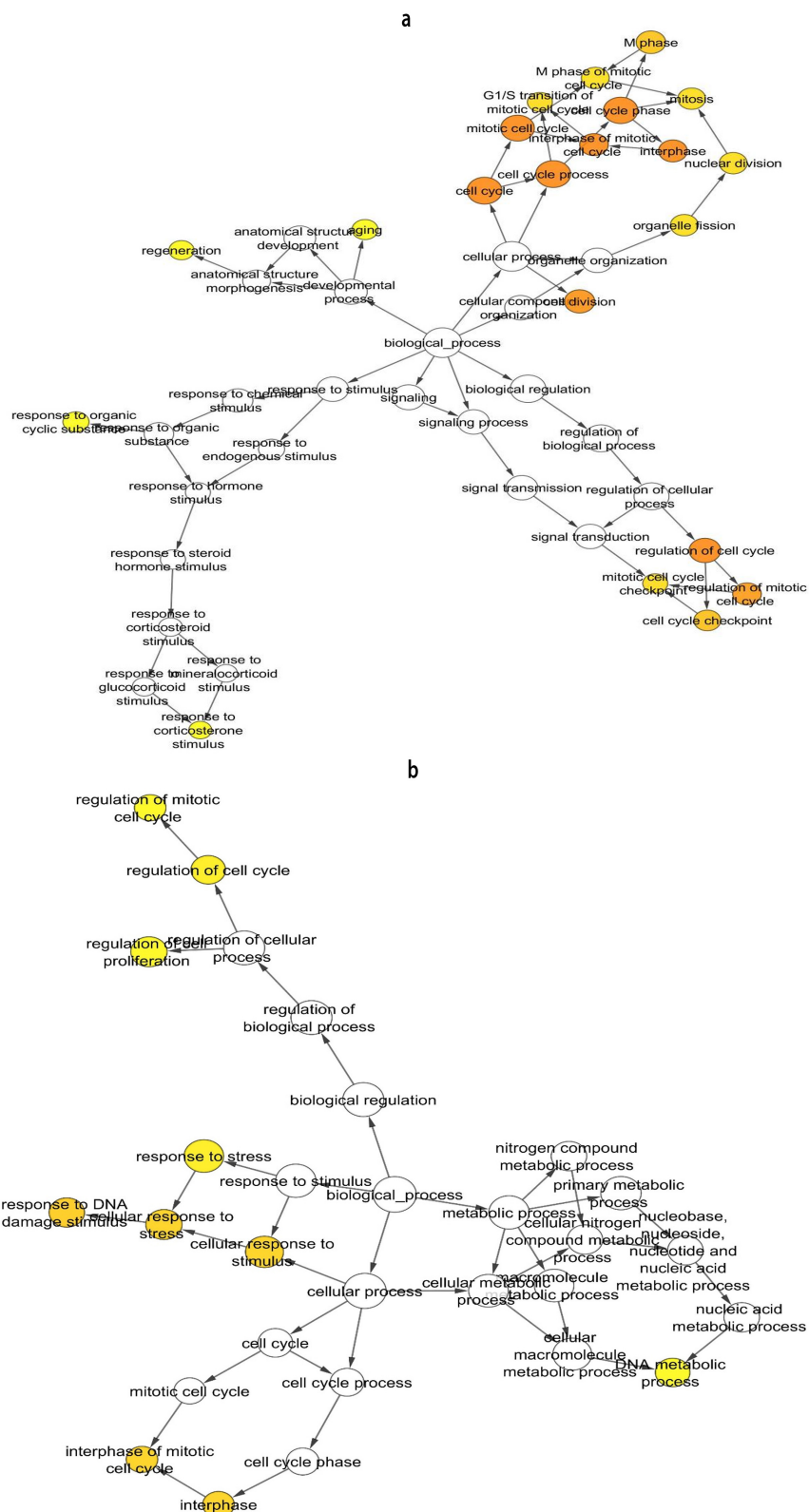


absent in luminal variant				
MMP2	Increased	Odontotheca tissues	Real-time PCR	(41)
MMP1	High	None	Immunohistochemistry	(42)
CDC42	No difference	Follicular and plexiform ameloblastomas	Immunohistochemistry	(38)
RUNX2	Low	None	PCR/ Western Blot/ Immunohistochemical	(43)
PTCH1	Same (High)	keratocystic odontogenic tumors	Immunohistochemistry.	(44)
BMP4	Expressed	None	Real- time PCR	(45)
MMP14	Higher in recurrent and solid/ multicystic ameloblastoma tissues than in primary and unicystic ameloblastoma tissues respectively	No control group	PCR	(41)
BCL2	High	P21	Immunohistochemistry	(46)
TIMP2	Low	Dentigerous cysts (DCs), radicular cysts (RCs), keratocystic odontogenic tumors (KOTs),	Immunohistochemistry	(47)
NOTCH2	No expression	Solid/multicystic (SA) and unicystic ameloblastomas (UA) recurrent ameloblastoma	Immunohistochemistry	(48)
TERT	Decreased	Oral mucosa	RT-PCR	(49)
CASP9	Same	Tooth germs	RT PCR	(50)
APC	Low	Tooth germs	Immunohistochemistry	(51)
VIM	Expressed	None	Immunohistochemistry	(52)
SHH	Low expression	Keratocystic Odontogenic tumor/ ameloblastoma	Immunohistochemistry	(44)
MKI67	Low	PCNA	Immunohistochemistry	(53)
TNFRSF1A	Increased	Tooth germ	RT PCR	(12)
MSX2	Decreased	P21 e p27	RT PCR Western blot	(53)
TNFSF11	Increased	Radicular cysts (RCs),	Immunohistochemistry	(54)

dentigerous cysts (DCs)				
APAF1	Same	Tooth germs	Immunohistochemical	(50)
SMO	Same (High)	keratocystic odontogenic tumors (KOT)	Immunohistochemistry	(44)
RECK	Low or no expression	keratocystic odontogenic tumor	Immunohistochemistry and RT-PCR	(55)
TNFRSF11B	Expressed	None	Immunohistochemistry, immunofluorescence and Western blot	(56)
	Lower	Tooth germs	RT-PCR and Immunohistochemistry	(57)
GLI1	High	Epithelial cells than in mesenchymal cells	RT-PCR and Immunohistochemistry	(58)
TRAF3	Low expression	Tooth germ	cDNA microarray and real-time RT-PCR	(12)
TNFRSF10B	Diffusely expressed	None	Immunohistochemistry	(59)
KRT18	Weakly and diffusely expressed	Tumor cells	Immunohistochemistry	(60)
KRT8	No expression.	None	Immunohistochemistry	(61)
TNFRSF10A	Diffusely expressed	None	Immunohistochemistry	(59)
TNFRSF11A	Expressed	Plexiform ameloblastomas than in follicular ameloblastomas	RT-PCR and Immunohistochemistry	(57)
NOS2	Increased	Tooth germs	Immunohistochemistry	(62)
WNT1	High	None	Immunohistochemistry	(63)
WNT5A	High	None	Immunohistochemistry	(64)
MAP2K1	Expressed	None	Immunohistochemistry	(65)
TNFRSF10C	Diffusely expressed	None	Immunohistochemistry and an in situ DNA nick-end labeling method	(59)
PDGFRA	Regularly expressed	None	Immunohistochemistry	(66)
SFRP2	Strongly	None	Immunohistochemistry and western blot	(67)
TP63	Higher	Plexiform ameloblastomas	Immunohistochemistry and	(68)

		than in follicular ameloblastomas	RT-PCR	
MMP20	No expression	None	Immunohistochemistry	(69)
PDGFA	High	Follicular ameloblastomas than in plexiform ameloblastomas	Immunohistochemistry	(70)
	Regularly expressed	None	Immunohistochemistry	(66)
SPARC	High	None	Immunohistochemistry	(71)
RHOB	High	Solid ameloblastoma.	Immunohistochemistry	(38)
WNT2	No expression or low	None	Immunohistochemistry	(63)
<b>KERATOCYSTIC ODONTOGENIC TUMOR</b>				
TP53	Low	Peripheral odontogenic keratocyst	Immunohistochemistry	(72)
PCNA	Highest level was in the suprabasal layer of KCOT	Radicular cysts, dentigerous cysts, and calcifying cystic odontogenic tumors	Immunohistochemistry	(73)
CCND1	Overexpression of downstream	Non-neoplastic oral mucosa	qPCR and immunohistochemistry	(44)
IL6	Higher expression rates were associated with tumor size in ameloblastomas and with cyst wall thickness in keratocystic odontogenic tumors	Cases of ameloblastomas and cases of orthokeratinized odontogenic keratocysts	Immunohistochemistry	(74)
VEGFA	High	Primary ameloblastoma, recurrent ameloblastoma, and malignant ameloblastoma	Immunohistochemical	(75)
ALCAM	Deletion	No control group	Immunohistochemistry, Array-comparative Genomic Hybridization Labeling, qRT-PCR	(76)
BCL2	Higher expression	KCOT and dental follicles	Immunohistochemistry, RNA isolation and quantitative reverse transcription (qRT-PCR), Western blotting	(77)
CALB2	Expression less	KCOT and ameloblastoma	Immunohistochemistry	(78)

CASP3	Express	KCOT, Ameloblastoma cisto radicular	immunohistochemical	(79)
FGFR2	Express	OKC, dentigerous cyst, glandular odontogenic cyst, gingival cyst of the adult and the radicular cyst exhibited and normal dental follicles	Western blot analysis and immunohistochemistry	(80)
FHIT	High	Dentigerous cysts (DC) and radicular cysts (RC)	Immunohistochemistry	(81)
GLI1	Overexpression	None	Immunohistochemistry	(82)
GLI2	Overexpression	None	Immunohistochemistry	(82)
KRT6B	Over-expressed in 12q13	Tooth germs	Immunohistochemistry	(76)
MKI67	Significantly higher	The cell proliferation and p53 protein expression (KCOT)	Immunohistochemistry	(83)
MMP13	Positive labelling	Non-nevoid basal cell	Immunohistochemistry	(84)
MMP9	Predominance	Follicular cyst	Immunohistochemistry	(85)
PTCH1	Frequently detected genetic and/or epigenetic mechanisms of inactivation of the PTCH1 in KCOT	Genetic and/or epigenetic mechanisms of inactivation of the PTCH1 in KCOT	PTCH1 mRNA expression and methylation	(86)
PTCH2	Germline mutations were detectable	Keratocystic odontogenic tumors	PCR-direct sequencing	(87)
SHH	Expressed	None	Immunohistochemical	(88)
SMO	No pathogenic mutation	NBCCS-associated KCOTs	Mutational analysis	(89)
SPP1	Expressed	None	Immunohistochemistry	(90)
TNFRSF11B	High	Solid ameloblastomas (SAs),	Immunohistochemistry using anti-RANKL and anti-OPG antibodies	(54)
TNFSF11	High	Dentigerous cysts (DCs), solid ameloblastomas (SAs)	Immunohistochemistry using anti-RANKL and anti-OPG antibodies	(54)
TP63	Higher	Epithelial lining of radicular cysts (RC), dentigerous cysts (DC)	Immunohistochemical	(75)



**Fig. 5.** Ontology analysis of ameloblastoma (a) and Keratocystic odontogenic tumor (b) network. The most important pathways over-represented in the graph versus whole set annotation, carried out with BinGO software ( $P < 0.01$ , Benjamini-Hochberg correction, hypergeometric clustering) are shown

## Discussion

AM and KCOT are odontogenic tumors strongly associated with cell proliferation and apoptosis inhibition (91,92). Literature reports have shown that an increase in the expression of caspase-3 and MMP-2 proteins are associated with growth and progression of KCOT and AM, indicating possible mechanisms involved in the recurrence KCOT and AM invasion. Moreover, epithelial lining of KCOTs showed a high turnover of cells suggesting that KCOT lesion can present neoplastic potential, as AM (79). Hence, studies have focused on molecular marker investigations for a better understanding of KCOT and AM pathogenesis.

In this sense, this study is the first to show, through bioinformatics analysis, interaction networks between protein-coding genes, leader genes and molecular pathways that can be related to the pathogenesis of AM and KCOT. Leader genes identified in the current study show distinct profiles between the odontogenic tumors; *CDK1* being the leader gene in AM, and *TP53* and *PCNA* as the leader genes in KCOT. All of these genes are somehow involved in apoptosis, cell cycle regulation, and cell proliferation.

The etiology and pathogenesis of AM are still not well understood. However, several factors such as *SHH*, *WNT*, *NOTCH*, *AKT* and *FGF* can be responsible for AM aggressiveness (93). In this context, it appears that both AM and KCOT are consequences of cell cycle deregulation, and/or apoptosis inhibition. The function of leader genes identified in this study coincides with the high proliferative activity of odontogenic epithelium in AM and KCOT. The literature reported a higher cell proliferation in KCOT than AM and similar apoptosis index between these tumors (94). These findings can support the classification of KCOT as an odontogenic tumor and can be related to its aggressive clinical behavior (94). Similarly, another study showed the aggressive nature of KCOT. KCOT and AM have been clearly demonstrated to

have both intrinsic growth potential and aggressive invasive behavior (95).

Interestingly, no study was found in the literature aiming to evaluate specifically the role of *CDK1* gene, identified by our bioinformatics analysis as a leader gene in AM. Our literature search revealed a single study where *CDK1* expression was reported in human ameloblastoma AM-1 cells (19). The expression of *CDK1*, *-4*, and *-6* was not changed in AM-1 cells, even with the induced overexpression of ameloblastin gene that may function as a tumor suppressor. Therefore, the *CDKs* remained expressed in the AM-1 cells (19). The CDK1-cyclin B complex is essential to initiate mitosis and can phosphorylate a wide range of proteins involved in regulatory and structural processes necessary for mitosis such as the nuclear envelope breakdown, condensation of chromatin, fragmentation of the golgi apparatus, and training of mitotic spindles (96).

Other studies have evaluated gene expression of other cyclin-dependent kinases and their receptors. Cyclin D1 was expressed in epithelial cells near the basement membrane in dental germs and AM. This fact seems to indicate that this protein is involved in cell proliferation in odontogenic epithelium and ameloblastic tumors (97, 98). The mRNA expression of cyclin E increased with AM recurrence and malignant transformation suggesting that genesis and invasion of AM are associated with the cell proliferation and differentiation, and are well-regulated by the increased expression of cyclin E and the lower expression of p21(*WAF1*) and p27(*KIP1*) (99).

Despite the scarcity of studies on *CDK1* in AM, this gene was appointed as a leader gene due to the increased number of interaction networks that it establishes with other genes, especially related to increased activity of cell proliferation, as demonstrated in the analysis of clustering and ontology. In addition to leader genes, the bioinformatic analysis shows several genes possibly

related to this tumor, such as *TP53*, *AKT1*, *PCNA*, *PTCH*, *mTOR*, *MMPs*, *BCL2* as well as others. By bioinformatics data, our literature review indicated that hedgehog signaling genes such as *HH*, *PTCH1*, *SMO*, and *GLI* are involved in AM pathogenesis. A high expression of SHH, SMO and GLI protein was reported in AM (4). Hedgehog (HH) signaling is a conserved pathway that guides embryonic patterning through the temporal and spatial regulation of cellular proliferation and differentiation (100). The HH pathway contributes to iASPP (inhibitor of the apoptosis-stimulating protein of p53) function, through the activation of Cyclin B1 and by the E2F1-dependent regulation of *CDK1*. These mechanisms are involved in iASPP induction. Results showed that activation of HH signaling enhances proliferation in the presence of E2F1 and contributes to apoptosis in its absence or upon CDK1 inhibition (101). In this bioinformatics study, the *CDK1* gene was considered as the leader of the molecular pathway of AM pathogenesis, demonstrating the importance of genes of the HH pathway in the pathogenesis of AM through the leader gene.

*TP53* and *PCNA* were identified as KCOT leader genes. Immunohistochemical studies have examined KCOT by using various markers of proliferation and apoptosis (102, 103). Proliferative activity of the epithelial lining of KCOT has been the subject of various investigations examining p53 expression (102), proliferating cell nuclear antigen (PCNA) (103) and Ki-67 (104). These studies concluded that KCOT displays a greater expression of p53, PCNA, and Ki-67 as compared to other types of odontogenic cysts (105).

The first leader gene in KCOT was the *TP53*, which is consistent with the available scientific information about its role in tumor development (106). *TP53* is a tumor suppressor gene with effective action at the G1 phase of the cell cycle, which participates in growth arrest, initiates repair, or induces apoptosis (107). Immunodetection of

this protein seems to influence the stabilization of the p53 product, an action which interferes with cell cycle regulation for proliferation (108), indicating an intrinsic growth potential of the KCOT epithelium (109). On the other hand, the literature review revealed weak expression of p53 in odontogenic lesions, such as KCOT and peripheral odontogenic keratocyst, in the same way as normal gingiva (9).

The second leader gene in KCOT was *PCNA*, encoding a nuclear protein linked to DNA replication and initiation of cell proliferation. Increased expression of PCNA may be stimulated with growth factors or as a result of DNA injury (110).

Molecular expression of p53 and PCNA in different odontogenic lesions revealed the highest level of both proteins in the suprabasal layer of KCOT compared with radicular cyst, dentigerous cyst, and Gorlin cyst, suggesting that proliferation and maturation patterns in KCOT differ from those found in the other lesions (9). Overexpression of *PCNA* in the suprabasal layer of the KCOT can clarify its neoplastic nature and a tendency toward tumor recurrence (73).

Similar to the AM, results revealed *PTCH* as a gene importantly involved in interaction network in KCOT. Previous studies showed evidence of mutations in the *PTCH* gene (89, 111), a tumor suppressor associated with nevoid basal cell carcinoma syndrome. Mutations in this gene could be responsible for migration and differentiation of abnormal cells, and also might interfere with apoptosis, which would lead to a deregulation of cell proliferation (112). Nonetheless, this gene was not designated as one of the leaders in our bioinformatics analysis, but it was highlighted by relevance described in the literature in both KCOT and AM (113, 114).

The analysis of interaction map allowed the identification of different groups of genes acting on

cell cycle regulation in AM and KCOT. This search confirmed that each gene identified as a leader gene could supposedly play an important role in AM and KCOT. Nevertheless, literature survey also revealed that other genes might be potentially involved in the pathogenesis of AM and KCOT, as shown in Table 2.

In our bioinformatics analysis, the interaction network of leader genes with a significant number of genes of the apoptosis pathway suggests that cell cycle deregulation is an important molecular event in both AM and KCOT. Moreover, functional enrichments in our network obtained from STRING database showed that orphan genes not linked to leader genes are ontologically related to the cell adhesion molecules and structural molecule activity.

Bioinformatics conducts a theoretical analysis using public databases, gene database, and scientific publishing databases, to generate relevant information and new knowledge. These theoretical results are well-supported by findings in the literature on the contribution of genes to the pathogenesis of AM and KCOT. Thus, based on the bioinformatics results and literature survey, further laboratory experiments should be conducted to better explain the real importance of interaction networks between genes in the pathogenesis of odontogenic tumors.

These data obtained through bioinformatics analysis can contribute to an improved body of knowledge about genes and molecular mechanisms involved in AM and KCOT pathogenesis. It is noteworthy that a detailed analysis of gene interaction networks and molecular pathways can be of great value in identifying new targets for an understanding of diseases and also to point to possible therapeutic targets. In addition, bioinformatics analysis can be an important tool for designing a hypothesis before conducting functional studies.

In this study, some genes with an important potential role in the pathogenesis of AM and KCOT were identified. Even with the limitations of any theoretical study, these preliminary results may suggest the involvement of promising genes for a better understanding of these odontogenic tumors.

#### **Acknowledgement**

This study was supported by grants from Conselho Nacional de Desenvolvimento Científico e Tecnológico (CNPq), Coordenação de Aperfeiçoamento de Pessoal de Nível Superior (CAPES), and Fundação de Amparo à Pesquisa do Estado de Minas Gerais (FAPEMIG), Brazil. Dr Guimarães and Dr De Paula are research fellows of the CNPq.

#### **Conflict of interests**

The authors declared no conflict of interest.

#### **References**

1. Philipsen HP, Reichart PA. Revision of the 1992-edition of the WHO histological typing of odontogenic tumours. A suggestion. *J Oral Pathol Med* 2002;31:253-8.
2. Adebayo ET, Ajike SO, Adekeye EO. Odontogenic tumours in children and adolescents: a study of 78 Nigerian cases. *J Craniomaxillofac Surg* 2002;30:267-72.
3. Mosqueda-Taylor A. New findings and controversies in odontogenic tumors. *Med Oral Patol Oral Cir Bucal* 2008;13:E555-8.
4. Gomes CC, Duarte AP, Diniz MG, et al. Review article: Current concepts of ameloblastoma pathogenesis. *J Oral Pathol Med* 2010;39:585-91.
5. Rastigi S, Nijhawan S, Modi M, et al. A Large Mixed Radiolucent-Radiopaque Lesion In The Mandible- A Nobel Diagnostic Approach. *J Clin Diagn Res* 2010;4:2300-7.
6. Fregnani ER, da Cruz Perez DE, de Almeida OP, et al. Clinicopathological study and treatment outcomes of 121 cases of ameloblastomas. *Int J Oral Maxillofac Surg* 2010;39:145-9.
7. Gunawardhana KS, Jayasooriya PR, Tilakaratne WM. Diagnostic dilemma of unicystic ameloblastoma: novel parameters to differentiate unicystic ameloblastoma from common odontogenic cysts. *J Investig Clin Dent* 2014;5:220-5.



8. Nagalaxmi V, Sangmesh M, Maloth KN, et al. Unicystic mural ameloblastoma: an unusual case report. *Case Rep Dent* 2013;2013:957418.
9. de Oliveira MG, Lauxen Ida S, Chaves AC, et al. Immunohistochemical analysis of the patterns of p53 and PCNA expression in odontogenic cystic lesions. *Med Oral Patol Oral Cir Bucal* 2008;13:E275-80.
10. Thosaporn W, Iamaroon A, Pongsirivet S, et al. A comparative study of epithelial cell proliferation between the odontogenic keratocyst, orthokeratinized odontogenic cyst, dentigerous cyst, and ameloblastoma. *Oral Dis* 2004;10:22-6.
11. Dodds AP, Cox SA, Suggs CA, et al. Characterization and mRNA expression in an unusual odontogenic lesion in a patient with tricho-dento-osseous syndrome. *Histol Histopathol* 2003;18:849-54.
12. Heikinheimo K, Jee KJ, Niini T, et al. Gene expression profiling of ameloblastoma and human tooth germ by means of a cDNA microarray. *J Dent Res* 2002;81:525-30.
13. Piro RM. Network medicine: linking disorders. *Hum Genet* 2012;131:1811-20.
14. Orlando B, Bragazzi N, Nicolini C. Bioinformatics and systems biology analysis of genes network involved in OLP (Oral Lichen Planus) pathogenesis. *Arch Oral Biol* 2013;58:664-73.
15. Poswar Fde O, Farias LC, Fraga CA, et al. Bioinformatics, interaction network analysis, and neural networks to characterize gene expression of radicular cyst and periapical granuloma. *J Endod* 2015;41:877-83.
16. Cui J, Li D, Zhang W, et al. Bioinformatics analyses combined microarray identify the deregulated microRNAs in oral cancer. *Oncol Lett* 2014;8:218-22.
17. Rebhan M, Chalifa-Caspi V, Prilusky J, et al. GeneCards: integrating information about genes, proteins and diseases. *Trends Genet* 1997;13:163.
18. Shannon P, Markiel A, Ozier O, et al. Cytoscape: a software environment for integrated models of biomolecular interaction networks. *Genome Res* 2003;13:2498-504.
19. Sonoda A, Iwamoto T, Nakamura T, et al. Critical role of heparin binding domains of ameloblastin for dental epithelium cell adhesion and ameloblastoma proliferation. *J Biol Chem* 2009;284:27176-84.
20. Razavi SM, Poursadeghi H, Aminzadeh A. Immunohistochemical comparison of cyclin D1 and P16 in odontogenic keratocyst and unicystic ameloblastoma. *Dent Res J (Isfahan)* 2013;10:180-3.
21. Salehinejad J, Zare-Mahmoodabadi R, Saghafi S, et al. Immunohistochemical detection of p53 and PCNA in ameloblastoma and adenomatoid odontogenic tumor. *J Oral Sci* 2011;53:213-7.
22. Lim J, Ahn H, Min S, et al. Oligonucleotide microarray analysis of ameloblastoma compared with dentigerous cyst. *J Oral Pathol Med* 2006;35:278-85.
23. DeVilliers P, Suggs C, Simmons D, et al. Microgenomics of ameloblastoma. *J Dent Res* 2011;90:463-9.
24. Sandra F, Hendarmin L, Nakao Y, et al. Inhibition of Akt and MAPK pathways elevated potential of TNF $\alpha$  in inducing apoptosis in ameloblastoma. *Oral Oncol* 2006;42:39-45.
25. Shahela T, Aesha S, Ranganathan K, et al. Immunohistochemical Expression of PCNA in Epithelial Linings of Selected Odontogenic Lesions. *J Clin Diagn Res* 2013;7:2615-8.
26. Hatakeyama S, Mizusawa N, Tsutsumi R, et al. Establishment of human dental epithelial cell lines expressing ameloblastin and enamelins by transfection of hTERT and cdk4 cDNAs. *J Oral Pathol Med* 2011;40:227-34.
27. Moreira PR, Guimaraes MM, Gomes CC, et al. Methylation frequencies of cell-cycle associated genes in epithelial odontogenic tumours. *Arch Oral Biol* 2009;54:893-7.
28. Zhong M, Liu J, Gong YB, et al. [Expression of p21WAF1, p27KIP1 and cyclin E in ameloblastoma]. *Zhonghua Kou Qiang Yi Xue Za Zhi* 2005;40:306-9.
29. Kim YS, Lee SK. Different Protein Expressions between Peripheral Ameloblastoma and Oral Basal Cell Carcinoma Occurred at the Same Mandibular Molar Area. *Korean J Pathol* 2014;48:151-8.
30. Kumamoto H, Ohki K. Detection of Notch signaling molecules in ameloblastomas. *J Oral Pathol Med* 2008;37:228-34.
31. Muraki E, Nakano K, Maeda H, et al. Immunohistochemical localization of Notch signaling molecules in ameloblastomas. *Eur J Med Res* 2011;16:253-7.
32. Chaisuparat R, Yodsanga S, Montaner S, et al. Activation of

- the Akt/mTOR pathway in dentigerous cysts, odontogenic keratocysts, and ameloblastomas. *Oral Surg Oral Med Oral Pathol Oral Radiol* 2013;116:336-42.
33. Shrestha P, Yamada K, Higashiyama H, et al. Epidermal growth factor receptor in odontogenic cysts and tumors. *J Oral Pathol Med* 1992;21:314-7.
  34. Li TJ, Browne RM, Matthews JB. Expression of epidermal growth factor receptors by odontogenic jaw cysts. *Virchows Arch A Pathol Anat Histopathol* 1993;423:137-44.
  35. Zhong M, Wang J, Zhang B, et al. [Expression of pRb and E2F-1 and telomerase activity in ameloblastoma]. *Zhonghua Kou Qiang Yi Xue Za Zhi* 2004;39:406-9.
  36. Kumamoto H, Ooya K. Immunohistochemical detection of retinoblastoma protein and E2 promoter-binding factor-1 in ameloblastomas. *J Oral Pathol Med* 2006;35:183-9.
  37. Krishna A, Kaveri H, Naveen Kumar RK, et al. Overexpression of MDM2 protein in ameloblastomas as compared to adenomatoid odontogenic tumor. *J Cancer Res Ther* 2012;8:232-7.
  38. Modolo F, Biz MT, de Sousa SM, et al. Immunohistochemical expression of Rho GTPases in ameloblastomas. *J Oral Pathol Med* 2012;41:400-7.
  39. Kumamoto H, Ooya K. Immunohistochemical detection of phosphorylated Akt, PI3K, and PTEN in ameloblastic tumors. *Oral Dis* 2007;13:461-7.
  40. Sah P, Menon A, Kamath A, et al. Role of immunomarkers in the clinicopathological analysis of unicystic ameloblastoma. *Dis Markers* 2013;35:481-8.
  41. Zhang B, Zhang J, Huang HZ, et al. Expression and role of metalloproteinase-2 and endogenous tissue regulator in ameloblastoma. *J Oral Pathol Med* 2010;39:219-22.
  42. Siqueira AS, Carvalho MR, Monteiro AC, et al. Matrix metalloproteinases, TIMPs and growth factors regulating ameloblastoma behaviour. *Histopathology* 2010;57:128-37.
  43. Sathi GA, Tsujigiwa H, Ito S, et al. Osteogenic genes related to the canonic WNT pathway are down-regulated in ameloblastoma. *Oral Surg Oral Med Oral Pathol Oral Radiol* 2012;114:771-7.
  44. Gurgel CA, Buim ME, Carvalho KC, et al. Transcriptional profiles of SHH pathway genes in keratocystic odontogenic tumor and ameloblastoma. *J Oral Pathol Med* 2014;43:619-26.
  45. Ruhin-Poncet B, Ghoul-Mazgar S, Hotton D, et al. Msx and dlx homegene expression in epithelial odontogenic tumors. *J Histochem Cytochem* 2009;57:69-78.
  46. Ahmed MM, El-Azab SM. Evaluation of cell cycle-related indicators in plexiform ameloblastoma. *J Egypt Natl Canc Inst* 2008;20:294-301.
  47. Henriques AC, Vasconcelos MG, Galvao HC, et al. Comparative analysis of the immunohistochemical expression of collagen IV, MMP-9, and TIMP-2 in odontogenic cysts and tumors. *Oral Surg Oral Med Oral Pathol Oral Radiol Endod* 2011;112:468-75.
  48. Siar CH, Nagatsuka H, Chuah KS, et al. Notch4 overexpression in ameloblastoma correlates with the solid/multicystic phenotype. *Oral Surg Oral Med Oral Pathol Oral Radiol Endod* 2010;110:224-33.
  49. Zhong M, Yan Y, Wang J, et al. [DNA methylation of human telomerase reverse transcriptase promoter region in human ameloblastoma]. *Zhonghua Kou Qiang Yi Xue Za Zhi* 2007;42:304-7.
  50. Kumamoto H, Ooya K. Detection of mitochondria-mediated apoptosis signaling molecules in ameloblastomas. *J Oral Pathol Med* 2005;34:565-72.
  51. Kumamoto H, Ooya K. Immunohistochemical detection of beta-catenin and adenomatous polyposis coli in ameloblastomas. *J Oral Pathol Med* 2005;34:401-6.
  52. Heikinheimo K, Sandberg M, Happonen RP, et al. Cytoskeletal gene expression in normal and neoplastic human odontogenic epithelia. *Lab Invest* 1991;65:688-701.
  53. Bologna-Molina R, Mosqueda-Taylor A, Molina-Frechero N, et al. Comparison of the value of PCNA and Ki-67 as markers of cell proliferation in ameloblastic tumors. *Med Oral Patol Oral Cir Bucal* 2013;18:e174-9.
  54. de Matos FR, de Moraes M, das Neves Silva EB, et al. Immunohistochemical detection of receptor activator nuclear kappaB ligand and osteoprotegerin in odontogenic cysts and tumors. *J Oral Maxillofac Surg* 2013;71:1886-92.
  55. Zhang B, Zhang J, Xu ZY, et al. Expression of RECK and matrix metalloproteinase-2 in ameloblastoma. *BMC Cancer* 2009;9:427.
  56. Sandra F, Hendarmin L, Nakamura S. Osteoprotegerin (OPG) binds with tumor necrosis factor-related apoptosis-inducing ligand (TRAIL): suppression of TRAIL- induced apoptosis in ameloblastomas. *Oral Oncol* 2006; 42:415-20.

57. Kumamoto H, Ooya K. Expression of parathyroid hormone-related protein (PTHrP), osteoclast differentiation factor (ODF)/receptor activator of nuclear factor-kappaB ligand (RANKL) and osteoclastogenesis inhibitory factor (OCIF)/osteoprotegerin (OPG) in ameloblastomas. *J Oral Pathol Med* 2004;33:46-52.
58. Kumamoto H, Ohki K, Ooya K. Expression of Sonic hedgehog (SHH) signaling molecules in ameloblastomas. *J Oral Pathol Med* 2004;33:185-90.
59. Rizzardi C, Leocata P, Ventura L, et al. Apoptosis-related factors (TRAIL, DR4, DR5, DcR1, DcR2, apoptotic cells) and proliferative activity in ameloblastomas. *Anticancer Res* 2009;29:1137-42.
60. Pal SK, Sakamoto K, Aragaki T, et al. The expression profiles of acidic epithelial keratins in ameloblastoma. *Oral Surg Oral Med Oral Pathol Oral Radiol* 2013;115:523-31.
61. Crivelini MM, de Araujo VC, de Sousa SO, et al. Cytokeratins in epithelia of odontogenic neoplasms. *Oral Dis* 2003;9:1-6.
62. Kumamoto H, Suzuki T, Ooya K. Immunohistochemical analysis of inducible nitric oxide synthase (iNOS) and heat shock proteins (HSPs) in ameloblastomas. *J Oral Pathol Med* 2002;31:605-11.
63. Siar CH, Nagatsuka H, Han PP, et al. Differential expression of canonical and non-canonical Wnt ligands in ameloblastoma. *J Oral Pathol Med* 2012;41:332-9.
64. Sukarawan W, Simmons D, Suggs C, et al. WNT5A expression in ameloblastoma and its roles in regulating enamel epithelium tumorigenic behaviors. *Am J Pathol* 2010;176:461-71.
65. Kumamoto H, Takahashi N, Ooya K. K-Ras gene status and expression of Ras/mitogen-activated protein kinase (MAPK) signaling molecules in ameloblastomas. *J Oral Pathol Med* 2004;33:360-7.
66. Sulzbacher I, Wick N, Pichlhofer B, et al. Expression of platelet-derived growth factor-AA and platelet-derived growth factor-alpha receptor in ameloblastomas. *J Oral Pathol Med* 2008;37:235-40.
67. Sathi GA, Inoue M, Harada H, et al. Secreted frizzled related protein (sFRP)-2 inhibits bone formation and promotes cell proliferation in ameloblastoma. *Oral Oncol* 2009;45:856-60.
68. Kumamoto H, Ohki K, Ooya K. Expression of p63 and p73 in ameloblastomas. *J Oral Pathol Med* 2005;34:220-6.
69. Takata T, Zhao M, Uchida T, et al. Immunohistochemical detection and distribution of enamelysin (MMP-20) in human odontogenic tumors. *J Dent Res* 2000;79:1608-13.
70. Kumamoto H, Ooya K. Immunohistochemical detection of insulin-like growth factors, platelet-derived growth factor, and their receptors in ameloblastic tumors. *J Oral Pathol Med* 2007;36:198-206.
71. Shen LC, Chen YK, Hsue SS, et al. Expression of osteonectin/secreted protein acidic and rich in cysteine and matrix metalloproteinases in ameloblastoma. *J Oral Pathol Med* 2010;39:242-9.
72. Sakamoto K, Morita K, Shimada Y, et al. Peripheral odontogenic keratocyst associated with nevoid basal cell carcinoma syndrome: a case report. *Oral Surg Oral Med Oral Pathol Oral Radiol* 2014;118:e19-23.
73. Seyedmajidi M, Nafarzadeh S, Siadati S, et al. p53 and PCNA Expression in Keratocystic Odontogenic Tumors Compared with Selected Odontogenic Cysts. *Int J Mol Cell Med* 2013;2:185-93.
74. Senguvan B, Oygur T. Investigation of interleukin-1 alpha and interleukin-6 expression and interleukin-1 alpha gene polymorphism in keratocystic odontogenic tumors and ameloblastomas. *Med Oral Patol Oral Cir Bucal* 2011;16:e467-72.
75. Chen WL, Ouyang KX, Li HG, et al. Expression of inducible nitric oxide synthase and vascular endothelial growth factor in ameloblastoma. *J Craniofac Surg* 2009;20:171-5; discussion 6-7.
76. Heikinheimo K, Jee KJ, Morgan PR, et al. Genetic changes in sporadic keratocystic odontogenic tumors (odontogenic keratocysts). *J Dent Res* 2007;86:544-9.
77. Diniz MG, Gomes CC, de Castro WH, et al. miR-15a/16-1 influences BCL2 expression in keratocystic odontogenic tumors. *Cell Oncol (Dordr)* 2012;35:285-91.
78. DeVilliers P, Liu H, Suggs C, et al. Calretinin expression in the differential diagnosis of human ameloblastoma and keratocystic odontogenic tumor. *Am J Surg Pathol* 2008;32:256-60.
79. Khalifa GA, Shokier HM, Abo-Hager EA. Evaluation of neoplastic nature of keratocystic odontogenic tumor versus

- ameloblastoma. *J Egypt Natl Canc Inst* 2010;22:61-72.
80. So F, Daley TD, Jackson L, et al. Immunohistochemical localization of fibroblast growth factors FGF-1 and FGF-2, and receptors FGFR2 and FGFR3 in the epithelium of human odontogenic cysts and tumors. *J Oral Pathol Med* 2001;30:428-33.
81. Malcic A, Jukic S, Anic I, et al. Alterations of FHIT and P53 genes in keratocystic odontogenic tumor, dentigerous and radicular cyst. *J Oral Pathol Med* 2008;37:294-301.
82. Zhang T, Chen M, Lu Y, et al. A novel mutation of the PTCH1 gene activates the Shh/Gli signaling pathway in a Chinese family with nevoid basal cell carcinoma syndrome. *Biochem Biophys Res Commun* 2011;409:166-70.
83. Gadbail AR, Patil R, Chaudhary M. Co-expression of Ki-67 and p53 protein in ameloblastoma and keratocystic odontogenic tumor. *Acta Odontol Scand* 2012;70:529-35.
84. Leonardi R, Matthews JB, Caltabiano R, et al. MMP-13 expression in keratocyst odontogenic tumour associated with NBCCS and sporadic keratocysts. *Oral Dis* 2010;16:795-800.
85. Bibichenko, II, Semkin VA, Katushkina AA. [Ki-67 and matrix metalloproteinase-9 expression in the follicular cyst, keratocystic odontogenic tumor, and ameloblastoma]. *Arkh Patol* 2013;75:10-4.
86. Pan S, Dong Q, Sun LS, et al. Mechanisms of inactivation of PTCH1 gene in nevoid basal cell carcinoma syndrome: modification of the two-hit hypothesis. *Clin Cancer Res* 2010;16:442-50.
87. Xu LL, Li TJ. [PTCH2 gene alterations in keratocystic odontogenic tumors associated with nevoid basal cell carcinoma syndrome]. *Beijing Da Xue Xue Bao* 2008;40:15-8.
88. Kaminagakura E, Almeida JD, Carvalho YR, et al. Keratocyst of the buccal mucosa: case report and immunohistochemical comparative study with sporadic intraosseous keratocystic odontogenic tumor. *Oral Surg Oral Med Oral Pathol Oral Radiol* 2013;116:e387-92.
89. Sun LS, Li XF, Li TJ. PTCH1 and SMO gene alterations in keratocystic odontogenic tumors. *J Dent Res* 2008;87:575-9.
90. Matsuzaka K, Inoue T, Nashimoto M, et al. A case of an ameloblastic fibro-odontoma arising from a calcifying odontogenic cyst. *Bull Tokyo Dent Coll* 2001;42:51-5.
91. Gonzalez-Gonzalez R, Molina-Frecherro N, Damian-Matsumura P, et al. Immunohistochemical expression of Survivin and its relationship with cell apoptosis and proliferation in ameloblastomas. *Dis Markers* 2015;2015:301781.
92. Alur J, Narayan TV, Mohanty L, et al. Ki-67 and p53 expression in solitary sporadic, syndrome associated and recurrent keratocystic odontogenic tumor. *J Oral Maxillofac Pathol* 2014;18:S21-5.
93. Jernvall J, Thesleff I. Reiterative signaling and patterning during mammalian tooth morphogenesis. *Mech Dev* 2000;92:19-29.
94. Metgud R, Gupta K. Expression of cell cycle and apoptosis-related proteins in ameloblastoma and keratocystic odontogenic tumor. *Ann Diagn Pathol* 2013;17:518-21.
95. Sindura C, Babu C, Mysorekar V, et al. Study of immunohistochemical demonstration of Bcl-2 protein in ameloblastoma and keratocystic odontogenic tumor. *J Oral Maxillofac Pathol* 2013;17:176-80.
96. Mahadevan D, Plummer R, Squires MS, et al. A phase I pharmacokinetic and pharmacodynamic study of AT7519, a cyclin-dependent kinase inhibitor in patients with refractory solid tumors. *Ann Oncol* 2011;22:2137-43.
97. Kumamoto H, Kimi K, Ooya K. Detection of cell cycle-related factors in ameloblastomas. *J Oral Pathol Med* 2001;30:309-15.
98. Kumar H, Vandana R, Kumar G. Immunohistochemical expression of cyclin D1 in ameloblastomas and adenomatoid odontogenic tumors. *J Oral Maxillofac Pathol* 2011;15:283-7.
99. Zhong M, Liu J, Gong YB, et al. [Expression of p21WAF1, p27KIP1 and cyclin E in ameloblastoma]. *Zhonghua Kou Qiang Yi Xue Za Zhi* 2005;40:306-9.
100. Ingham PW, McMahon AP. Hedgehog signaling in animal development: paradigms and principles. *Genes Dev* 2001;15:3059-87.
101. Pandolfi S, Montagnani V, Lapucci A, et al. HEDGEHOG/GLI-E2F1 axis modulates iASPP expression and function and regulates melanoma cell growth. *Cell Death Differ* 2015;22:2006-19.
102. Lombardi T, Odell EW, Morgan PR. p53 immunohistochemistry of odontogenic keratocysts in relation to recurrence, basal-cell budding and basal-cell naevus syndrome. *Arch Oral Biol* 1995;40:1081-4.
103. el Murtadi A, Grehan D, Toner M, et al. Proliferating cell nuclear antigen staining in syndrome and nonsyndrome

- odontogenic keratocysts. *Oral Surg Oral Med Oral Pathol Oral Radiol Endod* 1996;81:217-20.
104. Slootweg PJ. p53 protein and Ki-67 reactivity in epithelial odontogenic lesions. An immunohistochemical study. *J Oral Pathol Med* 1995;24:393-7.
105. Shear M. The aggressive nature of the odontogenic keratocyst: is it a benign cystic neoplasm? Part 1. Clinical and early experimental evidence of aggressive behaviour. *Oral Oncol* 2002;38:219-26.
106. Nylander K, Dabelsteen E, Hall PA. The p53 molecule and its prognostic role in squamous cell carcinomas of the head and neck. *J Oral Pathol Med* 2000;29:413-25.
107. Levine AJ, Momand J, Finlay CA. The p53 tumour suppressor gene. *Nature* 1991;351:453-6.
108. Piattelli A, Fioroni M, Santinelli A, et al. P53 protein expression in odontogenic cysts. *J Endod* 2001;27:459-61.
109. Mendes RA, Carvalho JF, van der Waal I. A comparative immunohistochemical analysis of COX-2, p53, and Ki-67 expression in keratocystic odontogenic tumors. *Oral Surg Oral Med Oral Pathol Oral Radiol Endod* 2011;111:333-9.
110. Li TJ, Browne RM, Matthews JB. Quantification of PCNA+ cells within odontogenic jaw cyst epithelium. *J Oral Pathol Med* 1994;23:184-9.
114. Pan S, Xu LL, Sun LS, et al. Identification of known and novel PTCH mutations in both syndromic and non-syndromic keratocystic odontogenic tumors. *Int J Oral Sci* 2009;1:34-8.
112. Gailani MR, Stahle-Backdahl M, Leffell DJ, et al. The role of the human homologue of *Drosophila patched* in sporadic basal cell carcinomas. *Nat Genet* 1996;14:78-81.
113. Barreto DC, Bale AE, De Marco L, et al. Immunolocalization of PTCH protein in odontogenic cysts and tumors. *J Dent Res* 2002;81:757-60.
114. Farias LC, Gomes CC, Brito JA, et al. Loss of heterozygosity of the PTCH gene in ameloblastoma. *Hum Pathol* 2012;43:1229-33.