



Association of oral mucosa hyperpigmentation with imatinib mesylate use: a cross-sectional study and a systematic literature review

Sicília Rezende Oliveira¹ · Luciana Gravito de Azevedo Branco¹ · Amanda Leal Rocha¹ · Denise Vieira Travassos² · Gustavo Henrique Romani Magalhães³ · Felipe Paiva Fonseca¹ · Ricardo Alves Mesquita¹ · Lucas Guimarães Abreu⁴ · Tarcília Aparecida da Silva¹

Received: 21 August 2018 / Accepted: 27 March 2019
© Springer-Verlag GmbH Germany, part of Springer Nature 2019

Abstract

Objectives To assess the association between oral mucosa hyperpigmentation in patients with leukemia and imatinib mesylate use. Additionally, we compared our data to those obtained from a systematic review.

Materials and methods A cross-sectional study was conducted with 74 patients undergoing treatment with imatinib mesylate. Sociodemographic characteristics, oral mucosa alterations, and medical history were evaluated. Oral hyperpigmentation was scored. The use of imatinib mesylate and hydroxyurea was evaluated. Association between oral hyperpigmentation and imatinib mesylate was assessed. A systematic review was also conducted to retrieve case reports or case series of patients with oral hyperpigmentation associated with imatinib mesylate.

Results Among the 74 participants, 41 were male (55.4%) and 33 were female (44.6%). Participants' mean age was 49.3 years. Sixty-six (89.2%) patients developed hyperpigmented lesions in the hard palate mucosa. In multivariate analysis, patients who had used imatinib mesylate for >72 months had a hyperpigmentation score 1.62 times higher than those who had used this medication during a shorter period. Patients who had used hydroxyurea for >30 days had a hyperpigmentation score 1.43 times higher than those who had used this medication during a shorter period. The systematic review retrieved 20 clinical cases of patients undergoing imatinib mesylate treatment and exhibiting oral hyperpigmentation.

Conclusions The development of oral hyperpigmentation is associated with imatinib mesylate use. Hydroxyurea seems to increment such an association.

Clinical relevance To assist providers in the differential diagnosis of hyperpigmented lesions associated with imatinib mesylate, as well as in the clinical management of such lesions.

Keywords Oral hyperpigmentation · Imatinib mesylate · Hydroxyurea · Antineoplastic agents

✉ Lucas Guimarães Abreu
lucasgabreu01@gmail.com

¹ Department of Oral Pathology and Surgery, School of Dentistry, Universidade Federal de Minas Gerais, Belo Horizonte, MG, Brazil

² Department of Community and Preventive Dentistry, School of Dentistry, Universidade Federal de Minas Gerais, Belo Horizonte, Minas Gerais, Brazil

³ Department of Hematology and Oncology, Chronic Myeloproliferative Diseases Outpatient Clinic, Universidade Federal de Minas Gerais, Belo Horizonte, Minas Gerais, Brazil

⁴ Department of Pediatric Dentistry and Orthodontics, School of Dentistry, Universidade Federal de Minas Gerais, Belo Horizonte, Minas Gerais, Brazil

Introduction

Leukemias are hematologic malignancies that can be subdivided into biologically distinct groups. The most common types are acute lymphoblastic leukemia (ALL), acute myeloid leukemia (AML), chronic lymphocytic leukemia (CLL), and chronic myeloid leukemia (CML) [1]. CML is a clonal myeloproliferative disease that accounts for 20% of all leukemias diagnosed among adults. In the USA, the annual incidence of CML is 1.6 cases per 100,000 inhabitants [2]. The neoplastic process is associated with t(9;22) (q34;q11) chromosomal translocation, the Philadelphia chromosome [3, 4]. This alteration leads to the formation of a fusion oncogene that is translated into the BCR-ABL1 oncoprotein [5].

Because of its deregulated tyrosine kinase activity, this oncoprotein triggers the uncontrolled growth and proliferation of myeloid cells [6]. ALL is characterized by the production of immature lymphocytes in the bone marrow and is the most common type of leukemia diagnosed among children and adolescents [7]. Approximately 3% to 5% of children and 20% to 30% of adults with ALL present a chromosomal alteration similar to that observed in patients with CML [8, 9].

The standard treatment for CML consisted of hematopoietic stem cell transplantation and the combination of interferon alpha and hydroxyurea [10]. Even though hydroxyurea results in symptomatic and hematological improvement and increases survival during the chronic phase of the disease, this drug does not induce significant cytogenetic remission and its use is associated with the development of mucocutaneous side effects, including hyperpigmentation [11, 12]. In contrast, though the achievement of complete cytogenetic remission, the side effects of interferon alpha limit its clinical application [11].

Imatinib mesylate (IM) is an anticancer agent that targets cancer-specific molecules, by means of the inhibition of tyrosine kinases. IM has been used as a first-line therapy for CML [13]. Patients with CML undergoing treatment with IM show satisfactory control of the disease and the survival rate is higher than that observed among those using classical therapies [14]. ALL patients, who carry the genetic mutation, were also found to respond positively to treatment with tyrosine kinase inhibitors [15, 16]. However, some patients may develop resistance to this class of drugs due to mutations in the BCR-ABL domain. Second-generation tyrosine kinase inhibitors, nilotinib, and dasatinib, have therefore been developed to treat these cases [16].

Adverse effects as nausea, muscle cramps, fluid retention, diarrhea, musculoskeletal pain, fatigue, and skin rashes have been observed after the long-term use of tyrosine kinase inhibitors [17, 18]. Oral manifestations including lichenoid reactions [19–21] and the development of hyperpigmented lesions that appear as blue-grayish melanotic maculae in the hard palate mucosa [22–27] have also been found in these patients.

However, the studies found in the literature are restricted to case reports describing a limited number of patients undergoing IM therapy. There is a scarcity of studies evaluating factors associated with oral mucosa alterations in a representative number of patients undergoing treatment with IM. Therefore, the aim of the present study was to assess the characteristics of patients undergoing treatment for CML and ALL with IM and the factors associated with oral hyperpigmentation in these individuals. Additionally, we compared our data with those obtained from a systematic literature review.

Materials and methods

This study comprised two phases. Phase 1 was a cross-sectional study, in which the characteristics of patients with

CML and ALL undergoing treatment with IM and the factors associated with oral hyperpigmentation in these individuals were evaluated. Phase 2 consisted of a systematic review of published case reports or case series of patients undergoing treatment with IM who developed oral hyperpigmentation.

Phase 1: study evaluating the association between oral hyperpigmentation and IM use

Study design, sampling, and setting

This was a cross-sectional study conducted in Belo Horizonte, Brazil, between January 2015 and July 2016. Seventy-four patients older than 18 years with a diagnosis of CML and ALL Ph+ undergoing chemotherapy with IM were included. Patients under surveillance at the Hematology Outpatient Clinic of the University Hospital of Universidade Federal de Minas Gerais (UFMG) were referred by the hematologist.

The study was approved by the Ethics Committee of UFMG (Protocol CAAE 48317515.6.0000.5149). Individuals who agreed to participate in the study signed a free informed consent form. The study was performed in accordance with the Declaration of Helsinki.

Data collection

Individuals eligible for the study were evaluated on a single occasion. During the appointment, sociodemographic and clinical data were collected. An oral examination was also carried out. Data about the underlying disease, gender, age, ethnicity, smoking habit, and side effects were recorded. In addition, cutaneous side effects associated with the use of the chemotherapeutic agent IM were recorded by means of the patients' report or checking patients' medical records. Participants were also asked about oral mucosa alterations, such as xerostomia, dysgeusia, and dry lips. Information on the treatment regimen for leukemia (imatinib mesylate and hydroxyurea), systemic alterations, and drugs used by the patients was obtained from the medical records.

Examination of the oral mucosa

The oral examination was performed under artificial light by two trained examiners (S.R.O. and L.G.A.B.). All areas of the mucosa were inspected to record the presence or absence of oral lesions with emphasis on the lichenoid lesions and oral hyperpigmentation.

After examination, the hard palate of all patients was photographed. The images obtained were analyzed by two oral pathologists (T.A.S. and R.A.M.) for confirmation of the diagnosis and evaluation of hyperpigmentation. For the latter, the extent and the intensity of the hard palate mucosa hyperpigmentation and the presence of hyperpigmentation on

the palatine raphe were assessed. Divergences between the two pathologists were resolved by discussion until consensus was achieved. These three criteria were evaluated using the following scores: (1) *extent*: 0 = no hyperpigmentation, 1 = up to 25% of the hard palate mucosa hyperpigmented, 2 = 25% to 50% of the hard palate mucosa hyperpigmented, 3 = 50% to 75% of the hard palate mucosa hyperpigmented, and 4 = 75% to 100% of the hard palate mucosa hyperpigmented; (2) *intensity*: 0 = no hyperpigmentation, 1 = mild hyperpigmentation, 2 = moderate hyperpigmentation, and 3 = marked hyperpigmentation; (3) *presence of hyperpigmentation in the palatine raphe*: 0 = no and 1 = yes.

The scores of each criterion were summed up to obtain the total hyperpigmentation score. The total score ranged from 0 to 8. The score 0 corresponded to the absence of hyperpigmentation in the oral mucosa and score 8 to the maximum hyperpigmentation and the presence of hyperpigmentation in the raphe palatine.

Incisional biopsy was performed in four patients to confirm the clinical diagnosis of hyperpigmented lesion.

Statistical analysis

The Statistical Package for the Social Sciences (SPSS for Windows, version 22.0, SPSS, Inc., Chicago, IL) was used for statistical analysis of the data. Descriptive analysis was carried out to evaluate the participants regarding underlying disease, sociodemographic characteristics, side effects, oral mucosa alterations, chemotherapy-related cutaneous side effects, and areas of hyperpigmentation in the oral mucosa. The Kolmogorov-Smirnov test showed a non-normal distribution of the dependent variable (total hyperpigmentation score). Therefore, nonparametric tests were used. Bivariate analysis (Mann–Whitney and Kruskal–Wallis tests) was performed to evaluate the association between the independent variables (gender, age, ethnicity, smoking, and use of hydroxyurea and IM) and the dependent variable (total hyperpigmentation score). Based on the median, the duration of hydroxyurea and IM use and patient age were dichotomized. Due to their epidemiological relevance, all independent variables were incorporated into the Poisson regression model. For this model, a level of significance of < 0.05 was adopted.

Phase 2: systematic review of case reports or case series of patients treated with IM who developed oral hyperpigmentation

Protocol

This systematic review was conducted according to the Preferred Reporting Items for Systematic Reviews and Meta-analyses (PRISMA) Statement.

Eligibility criteria

The systematic review included case reports or case series of patients with oral hyperpigmentation associated with the use of IM. There were no restrictions regarding articles' language or date of publication. Letters to the editor and editorials commenting about other published articles were excluded. So were meeting abstracts.

Sources of information

Electronic searches were conducted in December 2017 in the following databases: PubMed (National Library of Medicine), Scopus (Elsevier), Web of Science (Thomson Reuters), and Medline Ovid (Wolters Kluwer). In addition, the reference lists of the selected articles were searched manually.

Search strategy

The following search strategy was used for PubMed, Web of Science, and Medline Ovid: (imatinib mesylate OR dasatinib OR nilotinib OR bosutinib OR glivec OR gleevec OR STI571 OR sprycel OR tasigna OR bosulif OR tyrosine kinase inhibitor OR “hydreya” OR hydroxyurea) AND (pigmentation OR oral pigmentation OR oral mucosal pigmentation OR oral melanosis OR oral hyperpigmentation). For Scopus, the search strategy was tailored, taking into consideration the characteristics of the database.

Study selection

The selection of studies was conducted in two stages. In stage 1, the titles/abstracts of all articles retrieved during the search were read. References that did not meet the eligibility criteria were excluded. When the title/abstract was not available or did not provide sufficient information for a decision on inclusion or exclusion, the full text was retrieved. In stage 2, the full text of the articles was read and the same eligibility criteria as described above were applied. Articles that met those criteria were included.

Data extraction and data items

The following information was extracted from each included article: authors and year of publication, gender, age, ethnicity, presence or absence of smoking, underlying disease of the patient(s) whose clinical case had been described, type of lesion, oral site affected, dose, duration, and use of IM, and use or not of hydroxyurea and interferon.

Results

Phase 1

Sociodemographic data

Seventy-four patients participated in this study, including 72 (97.3%) with a diagnosis of CML and two (2.7%) with a diagnosis of ALL Ph+. There were 41 (55.4%) men and 33 (44.6%) women. Participants' age varied between 19 and 80 years. The mean age was 49.3 years (± 14.77). Most participants (85.1%) were Caucasians and had never smoked (64.9%) (Table 1).

Side effects

Among the 74 participants, seventy (94.59%) reported side effects associated with the use of IM. The main adverse effects were leg and arm cramps (72.85%), nausea (55.71%), periorbital edema (28.57%), muscle pain (22.85%), diarrhea (17.14%), headache (15.71%), dizziness (11.42%), fatigue (8.57%), leg edema (8.57%), joint pain (8.57%), bone pain (7.14%), loss of appetite (7.14%), facial swelling (5.71%), sleepiness (4.28%), jaw cramps (1.42%), weight loss (1.42%), weight gain (1.42%), joint swelling (1.42%), dry eyes (1.42%), and sweating (1.42%). Cutaneous side effects were also reported by 51 patients (68.9%) and included the development of dark spots on the skin (29.41%), erythema (29.41%), itching (25.49%), discoloration (19.6%), desquamation (13.72%), edema (1.96%), and dryness (1.96%). However, these effects did not result in discontinuation of the medication.

Oral mucosa alterations

Most participants had some alteration in the oral mucosa and mouth. These alterations mostly consisted of hyperpigmentation in the hard palate mucosa and were classified using the total hyperpigmentation score shown in Fig. 1. Sixty-six individuals (89.2%) presented a hyperpigmentation score equal to or higher than 2. Hyperpigmentation classified as score 6 was the most prevalent (21.6%), followed by score 7 (13.6%). Eight individuals (10.88%) exhibited score 0, i.e., they had no hyperpigmented areas in the oral mucosa. Score 1 was not possible. If an individual presented hyperpigmented lesion in the hard palate, the score for extension would be greater or equal to 1 and the score for intensity would be also greater or equal to 1. Therefore, among individuals without hyperpigmented lesion, the score would be 0 and among individuals with hyperpigmented lesion, the total score would range from 2 to 8. Oral lichenoid lesions in the buccal mucosa were detected in one individual (1.4%). Xerostomia was reported by

Table 1 Demographic characteristics and side effects associated with imatinib mesylate use

	Number (%)
Demographic characteristics	
Gender	
Male	41 (55.4)
Female	33 (44.6)
Age	
≤ 49	37 (50.0)
> 49	37 (50.0)
Ethnicity	
Caucasians	63 (85.1)
African descent	11 (14.9)
Smoking	
Never smoked	48 (64.9)
Still smoking	04 (5.4)
Stopped smoking	22 (29.7)
Mouth alterations	
Xerostomia	
Yes	05 (6.8)
No	69 (93.2)
Dysgeusia	
Yes	04 (5.4)
No	70 (94.6)
Lip dryness	
Yes	03 (4.1)
No	71 (95.9)
Oral lichenoid lesions	
Yes	01 (1.4)
No	73 (98.6)
Oral pigmentation (total score)	
0	08 (10.8)
1	00 (00.0)
2	07 (9.5)
3	09 (12.2)
4	09 (12.2)
5	09 (12.2)
6	16 (21.6)
7	10 (13.5)
8	06 (8.1)

five participants (6.8%), dysgeusia by four (5.4%), and dry lips by three (4.1%) (Table 1).

Microscopic examination of the samples obtained from pigmented palatal lesions (Fig. 2a) of four patients demonstrated the presence of melanin granules distributed throughout the lamina propria (Fig. 2b). The Fontana-Masson staining also confirmed the presence of melanin in the lamina propria (Fig. 2c). The staining was also positive for the Perls reaction,

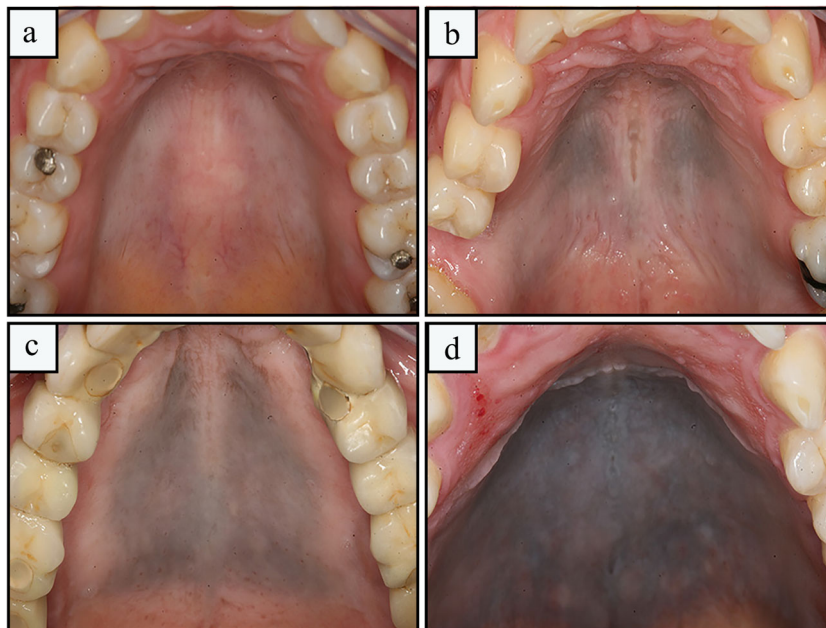


Fig. 1 Representative images of hyperpigmentation scores according to the extent, intensity, and involvement of the palatine raphe. **a** Absence of hyperpigmentation. Total pigmentation score of 0. **b** Hyperpigmentation of mild intensity, extending up to 25% of the hard palatal and no pigmentation of the palatine raphe. Total pigmentation score of 2. **c**

Pigmentation of moderate intensity involving from 50 to 75% of the hard palatal mucosa and with pigmentation of the palatine raphe. Total pigmentation score of 6. **d** Pigmentation of marked intensity, extending from 75 to 100% of the hard palatal mucosa with pigmentation of palatine raphe. Total pigmentation score of 8

thus demonstrating the presence of hemosiderin deposits along the lamina propria (Fig. 2d).

Treatment regimen

Patients’ treatment regimens and the mean duration of medication used are shown in Table 2. All 74 participants had used

IM as the main therapy for leukemia at some point. The mean duration of IM use was 74.16 months. As regards IM dose, at some point in the treatment, 69 patients used IM 400 mg, 14 patients used IM 600 mg, 15 patients used IM 300 mg, and one patient used IM 800 mg. Seventeen individuals used IM 400 mg during the entire course of the treatment. Forty-seven (63.0%) patients also used hydroxyurea prior to IM therapy

Fig. 2 Clinical and histopathological findings of oral hyperpigmentation. **a** Intraoral view showing a diffuse, blue-grayish maculae in the hard palate mucosa. Total pigmentation score of 6. **b** Fragment of palatal mucosa with the presence of melanin granules distributed exclusively within the lamina propria (H&E stain, × 400 (large box), × 200 (right above box)). **c** Pigmented particles showing positive reaction with the Fontana-Masson stain (Fontana-Masson stain, × 400 (large box), × 200 (right above box)). **d** Pigmented particles containing iron, identified by means of the positive Perls reaction. (Prussian blue stain, × 400 (large box), × 200 (right above the box))

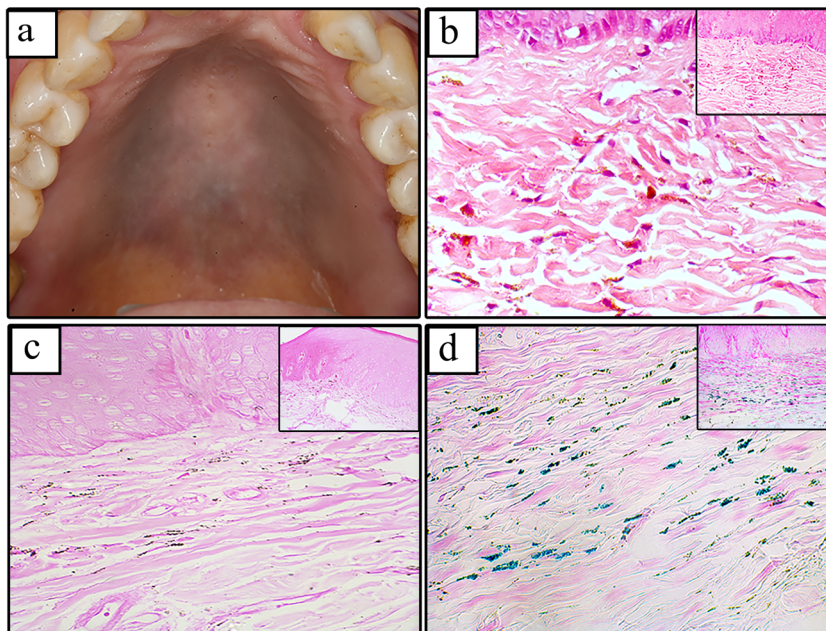


Table 2 Medications used during the treatment regimen

	Number (%)	Period of medication mean (min–max) months
Imatinib mesylate		
Yes	74 (100.0)	74.16 (5–153)
No	00 (0.0)	
Hydroxyurea		
Yes	47 (63.5)	3.91 (0.4–44)
No	27 (36.5)	
Interferon alpha		
Yes	19 (25.6)	11.63 (1–54)
No	55 (74.4)	
Dasatinib		
Yes	01 (1.3)	32.00 (32–32)
No	73 (98.7)	
Nilotinib		
Yes	03 (4.1)	21.67 (12–35)
No	71 (95.9)	

onset and the mean duration of use of this medication was 3.91 months. Interferon alpha (25.6%), dasatinib (1.3%), and nilotinib (4.1%) were less frequently used by participants.

Systemic alterations and medication use

Forty-five (60.81%) of the 74 participants had no comorbidities. The most frequent comorbidities in the remaining 29 participants (39.19%) were as follows: arterial hypertension (68.9%), diabetes mellitus (27.58%), depression (24.13%), and hypothyroidism (20.68%). Hypercholesterolemia (17.24%), seizures (10.34%), rheumatoid arthritis (3.44%), hepatitis (3.44%), chronic renal failure (3.44%), and hyperthyroidism (3.44%) were less common. Thirty-one (41.89%) participants reported the long-term use of some medication: antihypertensives (64.51%), diuretics (29.03%), antidiabetics (25.8%), antidepressants (22.58%), hormonal therapy agents (19.35%), antiplatelet agents (19.35%), statins (9.67%), anti-convulsants (9.67%), corticosteroids (3.22%), drugs for the treatment of hepatitis (3.22%), drugs for the treatment of chronic renal failure (3.22%), and drugs for the treatment of hyperthyroidism (3.22%).

Association analysis

Table 3 shows the results of bivariate analysis of the association between total oral hyperpigmentation score (dependent variable) and the independent variables (gender, age, ethnicity, smoking, and use of hydroxyurea and IM). Male patients, patients aged ≤ 49 years, African descent patients, patients who were still smoking, those who had used hydroxyurea > 1 month, and those who had used IM > 72 months had a higher oral hyperpigmentation mean score than female

Table 3 Bivariate analysis evaluating the total score of oral hyperpigmentation with independent variables

	N (%)	Total score mean/median (min–max)	p value
Gender			
Male	41 (55.4)	4.88 / 6.00 (0–8)	0.197*
Female	33 (44.6)	4.12 / 4.00 (0–8)	
Age			
≤ 49	37 (50.0)	4.92 / 6.00 (0–8)	0.188*
> 49	37 (50.0)	4.16 / 4.00 (0–8)	
Ethnicity			
Caucasians	63 (85.1)	4.41 / 5.00 (0–8)	0.226*
African descent	11 (14.9)	5.27 / 6.00 (0–8)	
Smoking			
Never smoked	48 (64.9)	4.56 / 5.00 (0–8)	0.485**
Still smoking	04 (5.4)	5.75 / 6.00 (3–8)	
Stopped smoking	22 (29.7)	4.27 / 4.00 (0–8)	
Hydroxyurea			
≤ 01 month	22 (46.8)	3.45 / 3.50 (0–8)	0.002*
> 01 month	25 (53.2)	5.52 / 6.00 (0–8)	
Imatinib mesylate			
≤ 72 months	37 (50.0)	3.00 / 3.00 (0–7)	0.280*
> 72 months	37 (50.0)	5.35 / 6.00 (0–8)	

*Mann–Whitney test

**Kruskal–Wallis test

patients, patients aged > 49 years, Caucasian patients, patients who had stopped smoking or never smoked, those who had used hydroxyurea ≤ 1 month, and those who had used IM ≤ 72 months.

The results of Poisson regression are shown in Table 4. Patients who had used IM > 72 months had a 1.62-fold higher total oral hyperpigmentation score than those who had used IM ≤ 72 months (confidence interval, 1.12–2.33, $p = 0.010$). Patients who had used hydroxyurea > 1 month had a 1.43-fold higher total oral hyperpigmentation score than those who had used hydroxyurea ≤ 1 month (confidence interval, 1.02–2.01, $p = 0.034$).

Phase 2

Study selection

A total of 275 references were identified in the four electronic databases. Four references were identified through other sources. After removal of 113 duplicates, 166 titles/abstracts were read in stage 1. Of these, 15 articles met the eligibility criteria and were included. The title/abstracts of nine articles contained insufficient information for a decision. Thus, the full texts were retrieved for analysis in stage 2. In this stage, one of the nine articles, whose full text had been read, was

Table 4 Multivariate analysis evaluating the association between the total score of oral hyperpigmentation with independent variables

	PR non adjusted (95% CI)	<i>p</i> value	PR adjusted (95% CI)	<i>p</i> value
Gender				
Male	1.18 (0.95–1.47)	0.129	1.10 (0.82–1.47)	0.506
Female	1		1	
Age				
≤ 49	1.18 (0.95–1.46)	0.127	1.25 (0.58–1.10)	0.174
> 49	1		1	
Ethnicity				
Caucasians	1	0.217	1	0.121
African descent	1.19 (0.90–1.58)		1.34 (1.03–1.74)	
Smoking				
Never smoked	1.06 (0.83–1.36)	0.595	0.87 (0.79–1.64)	0.466
Still smoking	1.34 (0.85–2.12)	0.202	1.08 (0.48–1.74)	0.803
Stopped smoking	1		1	
Hydroxyurea				
≤ 01 month	1	0.001	1	0.034
> 01 month	1.59 (1.20–2.11)		1.43 (1.02–2.01)	
Imatinib mesylate				
≤ 72 months	1	0.230	1	0.010
> 72 months	1.14 (0.91–1.41)		1.62 (1.12–2.33)	

included. Thus, 16 articles were included in this systematic review [22–37]. Figure 3 depicts the flow chart of the study.

Characteristics of the studies

Fourteen of the 16 included articles were case reports and two were case series. Fifteen articles were published in English and one in Spanish. The articles were published between 2007 and 2018. Most patients with hyperpigmentation were female and had CML. The mean age was 54 years ranging from 29 to 72 years. The hard palate mucosa was the site most affected by oral hyperpigmentation. Most patients were non-smokers and used an IM dose of 400 mg per day. The duration of IM use ranged from 3 to 192 months. Two cases used hydroxyurea before IM treatment onset. Interferon use was not reported in any of the cases. The entire information on the characteristics of the included studies is presented in Table 5.

Discussion

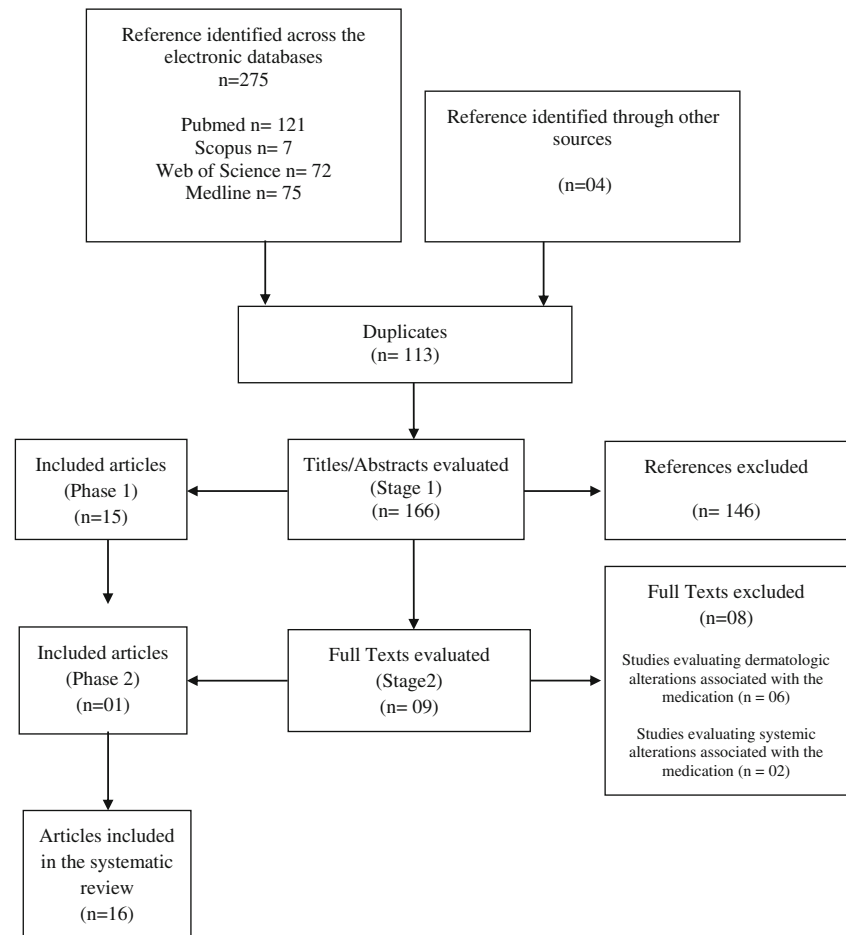
Among the 74 patients included in this study, 89.2% developed hyperpigmented lesions. All hyperpigmented lesions were in the hard palate mucosa. The duration of IM use is associated with the intensity and extent of the hyperpigmented lesions observed. Patients who had used the chemotherapeutic agent for > 72 months had a higher total hyperpigmentation score than those who had used the agent ≤ 72 months. Furthermore, patients who had used hydroxyurea > 30 days

also had a higher total hyperpigmentation score than those who had used the drug for ≤ 30 days.

The systematic literature review identified 20 cases of oral hyperpigmentation related to the use of IM reported by 16 articles. Most cases exhibited hyperpigmentation in the hard palate mucosa and none of the authors reported the likely cause associated with the development of hyperpigmented lesions at this site. The mean duration of IM use in the cases reported in the literature was 86 months (range between 3 and 192 months). In the present study, the mean duration of the use of the medication was 72 months. We obtained that higher pigmentation scores were associated with the individuals who had used IM for more than 72 months. No previous studies described the association between the duration of IM use and the development of hyperpigmented lesions.

Most studies [22, 23, 26, 28–34, 37] of the literature do not report the entire history of medications used by the patients prior to IM therapy onset, which precludes the indication of this drug as the single agent causing oral hyperpigmentation. This question had been addressed previously and hydroxyurea was indicated as a possible causative agent of mucocutaneous pigmentation in the skin, nails, and oral mucosa. One study [12] suggested that hydroxyurea may be associated with hyperpigmentation in the oral mucosa.

CML has a predilection for adults and older individuals [39]. In the present study, participants' age ranged from 19 to 80 years and the mean age was 49.3 years. A predominance of Caucasian men was observed. CML has been reported to be more common among men than women, but a racial

Fig. 3 Flowchart of the systematic review

predilection has not been established [40]. In a retrospective study, the authors concluded that the percentage of men with CML is higher than that of women and defined that the mean age of affected patients was between 40 and 50 years, which is in agreement with the results of the present study [14].

With respect to the chemotherapy regimen used by patients with leukemia, two classes of tyrosine kinase inhibitors are currently available: first-generation inhibitors (IM) and second-generation inhibitors (for example, nilotinib and dasatinib) [41]. IM is an oral chemotherapeutic agent that specifically targets tyrosine kinase, selectively inhibiting the proliferation and inducing apoptosis of BCR-ABL-positive cell lines, with no effect on non-neoplastic cells [13, 42]. More than 85% of patients treated with tyrosine kinase inhibitors achieve a complete cytogenetic response and nearly 40% achieve complete molecular remission [43]. In addition, IM is much less toxic than classical drugs, such as hydroxyurea and interferon alpha [44]. However, as some patients fail to respond adequately to IM, second-generation drugs, such as dasatinib, have been developed [45]. In the present study, the small number of patients using dasatinib or nilotinib made the individual evaluation of the possible association of these drugs with oral pigmentation unfeasible. It is possible that the

hyperpigmented lesions observed among individuals undergoing dasatinib or nilotinib therapy may be associated with the previous medication with IM.

In addition to inhibiting tyrosine kinase, IM also acts on c-Kit [46]. The latter is a type III receptor tyrosine kinase that plays a regulatory role in melanogenesis, controlling the migration, proliferation, and differentiation of melanocytes [47, 48]. IM acts by means of the blockage of the binding between c-Kit receptors and stem cell factor in melanocytes, ultimately, reducing the activity of these cells [49, 50]. In this regard, an important side effect attributed to this chemotherapeutic agent is the development of hypopigmentation in the skin [51]. However, the hyperpigmentation observed in the participants of this study and in the case reports identified in the literature contrasts with the expected inhibitory effect of IM on the c-Kit receptors of melanocytes. The different effects of IM on the skin and mucosal pigmentation might be explained by the presence or absence of a mutated c-Kit gene or of a kinase variant that is activated rather than inhibited by the chemotherapeutic agent [52, 53]. Microscopic examination demonstrated the presence of melanin granules distributed throughout the lamina propria as reported elsewhere [22–24, 31, 35]. The Fontana-Masson staining also confirmed the presence of

Table 5 Review of previously reported cases associating oral pigmentation and Imatinib mesylate use

Case	Gender	Age (year)	Ethnicity	Smoking	Diagnosis	Type of lesion	Site	IM (dose/mg)	IM (time/month)	Hydroxyurea	Interferon	Reference
1	F	13	NRR	NR	LMC	Hyperpigmentation	Gums	300	48	NR	NR	28
2	F	59	C	NR	LMC	Hyperpigmentation	Upper gums	NR	72	NR	NR	29
3	F	43	C	No	LMC	Diffuse slate-gray pigmentation	Hard palate	NR	3	NR	NR	23
4	F	66	C	No	Leiomyoblastoma	Bluish-brown U-shaped pigmentation	Hard palate	400	60	NR	NR	22
5	F	66	NR	No	LMC	Hyperpigmentation	Hard palate	400	60	NR	NR	22
6	F	64	NR	No	LMC	Bluish-brown pigmented lesion	Hard palate	400	60	NR	NR	22
7	M	64	C	No	LMC	Gray-blue pigmentation	Hard palate	400	48	No	NR	24
8	M	53	C	No	LMC	Gray-blue pigmentation	Hard palate	400	120	Yes	NR	24
9	F	29	C	No	Pelvic fibromatosis	Diffuse blue-black pigmentation	Hard palate	400	48	No	NR	24
10	M	38	C	NR	LLA/neurofibromatosis	Diffuse blue pigmentation	Hard palate	600	60	NR	NR	30
11	M	48	C	No	LMC	Gray pigmentation	Hard palate	400	108	NR	NR	31
12	F	56	C	No	LMC	Grayish macule	Hard palate	400	96	NR	NR	32
13	M	58	C	No	LMC	Hyperpigmentation (slate-gray/purplish)	Hard palate	NR	60	Yes	NR	25
14	F	65	C	NR	LMC	Discoloration	Hard palate	NR	72	NR	NR	26
15	M	58	C	NR	LMC	Slate-gray pigmentation	Hard palate	NR	NR	NR	NR	33
16	F	58	C	No	LMC	Bluish macular	Hard palate	400/600	156	NR	NR	34
17	F	72	NR	No	LMC	Diffuse, blue-gray pigmented lesion	Hard palate	400	132	No	NR	35
18	M	63	C	No	LMC	Gray-blue hyperpigmentation	Hard palate	400	108	No	NR	36
19	M	61	NR	No	LMC	Gray black hyperpigmentation	Hard palate	400	132	No	NR	27
20	M	47	C	No	LMC	Blue-gray macular pigmentation	Hard palate	400/800	192	NR	NR	37

NR, not reported; Y, yes; CML, chronic myeloid leukemia; IM, imatinib mesylate; M, male; F, female; C, Caucasian

melanin in the lamina propria as described in other studies [23, 24, 31, 33]. Noteworthy, previous studies did observe hemosiderin (iron)-positive deposits in hyperpigmented lesions associated with IM use [24, 27, 34, 36, 37]. In this study, iron particles in the lamina propria have been observed by means of the positive Perls reaction. This deposition may occur due to the chelation of iron with the drug or its metabolites [54]. This finding was also described in patients under chloroquine therapy who developed hyperpigmented lesions [55]. In contrast, others did not observe hemosiderin deposits in samples of IM-associated pigmented lesions [22, 23, 31].

Since drug-related hyperpigmented oral lesions are benign and indolent, they do not require treatment. However, hyperpigmented oral lesions are of diverse nature and range from physiological pigmentation to malignant neoplasms [56], and differential diagnosis to exclude pathological conditions of the oral mucosa is necessary. In the present study, incisional biopsy was performed in four patients to confirm the clinical diagnosis of hyperpigmented lesion.

Racial or physiological pigmentation is commonly observed in African descent individuals, especially on the attached gingiva [57, 58]. Most patients evaluated in this study were Caucasians and the clinical characteristics of the lesions did not correspond to physiological pigmentation. In addition, in multivariate analysis, ethnicity had no influence on the oral hyperpigmentation of the patients.

Smoker's melanosis is a diffuse melanin pigmentation of the oral mucosa that occurs in 21.5% of smokers, mainly affecting the anterior labial gingiva and buccal mucosa [59, 60]. In this study, 64.9% of the patients reported that they had never smoked. However, no association was observed between the total hyperpigmentation score and smoking. In the case reports retrieved from the literature, most individuals were also non-smokers.

The long-term use of some drugs, as tetracyclines, antimalarial drugs, and nonsteroidal anti-inflammatory drugs, has been associated with the development of oral hyperpigmentation [27, 61, 62]. However, the patients evaluated in our study had no history of use of any of these drugs. In the systematic review, the authors did not describe whether the patients had previously used other drugs associated with hyperpigmentation.

Disease-associated melanosis is related to many systemic diseases and is usually seen as a diffuse pigmentation affecting multiple sites. Among several systemic conditions, Addison's disease is an uncommon endocrine illness, resulted from defective production of adrenocortical hormone [63]. The subsequent increase in adrenocorticotrophic hormone production may stimulate melanocytes, leading to the typical hyperpigmentation of the skin and mucous membranes. Involvement of the oral mucosa is characterized by a diffuse brown pigmentation of the gingiva, tongue, buccal mucosa, hard palate mucosa, and lips [57, 59]. In the present study, diagnosis of

Addison's disease was excluded by medical examination in all patients.

In addition to the development of hyperpigmented oral lesions, oral lichenoid lesions may also be observed among individuals undergoing IM therapy [19–21]. In our study, only one individual submitted to treatment with IM presented oral lichenoid lesions. Remission of the lesions was not observed during clinical follow-up, but the patient refused to undergo biopsy.

Other oral adverse effects associated with IM therapy, such as xerostomia, dysgeusia, and dry lips, were reported less frequently by the patients of this study. Dysgeusia and xerostomia are predictable effects and are described in the medication package insert. However, none of these effects were reported in the cases identified in the systematic review.

Adverse effects commonly associated with IM use are nausea, skin rash, diarrhea, and edema [16, 18]. Muscle cramps, musculoskeletal pain, and fatigue have also been described [18]. In the present study, muscle cramps were the most frequently observed effects, followed by nausea, periorbital edema, muscle pain, diarrhea, headache, and dizziness. As regards dermatological effects, 68.9% of the participants reported some types of nonspecific adverse reaction, especially the development of dark spots on the skin, erythema, itching, discoloration, desquamation, and cutaneous edema. These cutaneous adverse events mainly manifested as mild to moderate atypical skin rashes. In contrast, severe dermatological reactions are rarely observed [64]. A prevalence of cutaneous reactions of 13.6%, including maculopapular erythematous skin rashes, cutaneous and periorbital edema, and discolored areas on the face, has been observed [65]. In another study [51], 40.9% of the participants developed skin hypopigmentation related to the use of IM.

Taking into account that this was a cross-sectional study, in which participants were evaluated once and considering that oral hyperpigmentation is asymptomatic and of difficult visualization by the affected individual, it was not possible to determine the duration of use and exact dosage of hydroxyurea and IM that might have triggered hyperpigmented lesions. Longitudinal studies with long-term follow-up of the patients are, therefore, encouraged to unfold these aspects.

The data analysis and the review of the literature allow us to conclude that the development or the extent and intensity of hyperpigmentation in the oral mucosa are related to the duration of IM use. In addition, the duration of hydroxyurea treatment might increase the extent and intensity of oral hyperpigmentation. However, the question unveiling the entire mechanism by which these drugs may lead to oral hyperpigmentation is yet to be answered. In vitro and in vivo studies may contribute to clarify the mechanism of action of these drugs on the oral mucosa.

Funding information This work was supported by the Conselho Nacional de Desenvolvimento Científico e Tecnológico (CNPq) and the Coordenação de Aperfeiçoamento de Pessoal de Nível Superior (CAPES-Finance code 001). RAM and TAS are research fellows of CNPq.

Compliance with ethical standards

Conflict of interest The authors declare that they have no conflict of interest.

Ethical approval All procedures performed in this study involving human participants were in accordance with the ethical standards of the institutional and/or national research committee and with the 1964 Helsinki declaration and its later amendments or comparable ethical standards.

Informed consent Informed consent was obtained from all individual participants included in the study.

References

- Xie Y, Davies SM, Xiang Y, Robison LL, Ross JA (2003) Trends in leukemia incidence and survival in the United States (1973–1998). *Cancer* 97:2229–2235
- Jemal A, Tiwari RC, Murray T, Ghafoor A, Samuels A, Ward E, Feuer EJ, Thun MJ (2004) American Cancer Society, Cancer statistics. *CA Cancer J Clin* 54:8–29
- Nowell PC, Hungerford DA (1960) Chromosome studies on normal and leukemic human leukocytes. *J Natl Cancer Inst* 25:85–109
- Rowley JD (1973) A new consistent chromosomal abnormality in chronic myelogenous leukaemia identified by quinacrine fluorescence and Giemsa staining. *Nature* 243:290–293
- Shtivelman E, Lifshitz B, Gale RP, Canaani E (1985) Fused transcript of abl and bcr genes in chronic myelogenous leukaemia. *Nature* 315:550–554
- Abramson S, Miller RG, Phillips RA (1977) The identification in adult bone marrow of pluripotent and restricted stem cells of the myeloid and lymphoid systems. *J Exp Med* 145:1567–1579
- Miller KD, Siegel RL, Lin CC, Mariotto AB, Kramer JL, Rowland JH, Stein KD, Alteri R, Jemal A (2016) Cancer treatment and survivorship statistics, 2016. *CA Cancer J Clin* 66:271–289
- Faderl S, Kantarjian HM, Talpaz M, Estrov Z (1998) Clinical significance of cytogenetic abnormalities in adult acute lymphoblastic leukemia. *Blood* 91:3995–4019
- Schlieben S, Borkhardt A, Reinisch I, Ritterbach J, Janssen JW, Ratei R, Schrappe M, Repp R, Zimmermann M, Kabisch H, Janka-Schaub G, Bartram CR, Ludwig WD, Riehm H, Lampert F, Harbott J (1996) Incidence and clinical outcome of children with BCR/ABL-positive acute lymphoblastic leukemia (ALL). A prospective RT-PCR study based on 673 patients enrolled in the German pediatric multicenter therapy trials ALL-BFM-90 and CoALL-05-92. *Leukemia* 10:957–963
- Hehlmann R, Berger U, Pfirrmann M et al (2003) Randomized comparison of interferon α and hydroxyurea with hydroxyurea monotherapy in chronic myeloid leukemia (CML-study II): prolongation of survival by the combination of interferon α and hydroxyurea. *Leukemia* 17:1529–1537
- Henkes M, van der Kuip H, Aulitzky WE (2008) Therapeutic options for chronic myeloid leukemia: focus on imatinib (Gleevec®). *Ther Clin Risk Manag* 4:163
- Kumar B, Saraswat A, Kaur I (2002) Mucocutaneous adverse effects of hydroxyurea: a prospective study of 30 psoriasis patients. *Clin Exp Dermatol* 27:8–13
- Savage DG, Antman KH (2002) Imatinib mesylate—a new oral targeted therapy. *New Engl J Med* 346:683–693
- Payandeh M, Sadeghi M, Sadeghi E (2015) Treatment and survival in patients with chronic myeloid leukemia in a chronic phase in West Iran. *Asian Pac J Cancer Prev* 16:7555–7559
- Thomas DA, Faderl S, Cortes J (2004) Treatment of Philadelphia chromosome-positive acute lymphocytic leukemia with hyper-CVAD and imatinib mesylate. *Blood* 103:4396–4407
- Piccaluga PP, Paolini S, Martinelli G (2007) Tyrosine kinase inhibitors for the treatment of Philadelphia chromosome-positive adult acute lymphoblastic leukemia. *Cancer* 110:1178–1186
- Cohen MH, Williams G, Johnson JR, Duan J, Gobburu J, Rahman A, Benson K, Leighton J, Kim SK, Wood R, Rothmann M, Chen G, U K, Staten AM, Pazdur R (2002) Approval summary for imatinib mesylate capsules in the treatment of chronic myelogenous leukemia. *Clin Cancer Res* 8:935–942
- Deininger MW, O'Brien SG, Ford JM, Druker BJ (2003) Practical management of patients with chronic myeloid leukemia receiving imatinib. *J Clin Oncol* 21:1637–1647
- Lim DS, Muir J (2002) Oral lichenoid reaction to imatinib (STI 571, Gleevec). *Dermatology* 205:169–171
- Ena P, Chiarolini F, Siddi GM, Cossu A (2004) Oral lichenoid eruption secondary to imatinib (Glivec®). *J Dermatol Treat* 15:253–255
- Pascual JC, Matarredona J, Miralles J, Conesa V, Borrás-Blasco J (2006) Oral and cutaneous lichenoid reaction secondary to imatinib: report of two cases. *Int J Dermatol* 45:1471–1473
- Mattsson U, Halbritter S, Serikoff EM, Christerson L, Warfvinge G (2011) Oral pigmentation in the hard palate associated with imatinib mesylate therapy: a report of three cases. *Oral Surg Oral Med Oral Pathol Oral Radiol Endod* 111:12–16
- Wong M, Sade S, Gilbert M, Klieb HB (2011) Oral melanosis after tyrosine kinase inhibition with imatinib for chronic myelogenous leukemia: report of a case and review of the literature. *Dermatol Online J* 17:4
- Li CC, Malik SM, Blaeser BF, Dehni WJ, Kabani SP, Boyle N, Toner M, Woo SB (2012) Mucosal pigmentation caused by imatinib: report of three cases. *Head Neck Pathol* 6:290–295
- Khoo TL, Catalano A, Supple S, Chong L, Yeoh SC, Yeung S, Iland H (2013) Hyperpigmentation of the hard palate associated with imatinib therapy for chronic myeloid leukemia with a genetic variation in the proto-oncogene c-KIT. *Leuk Lymphoma* 54:186–188
- Roeker LE, Wolanskyj AP (2014) Imatinib-associated melanosis of the palate. *Am J Hematol* 89:564–564
- Tosios KI, Kalogirou EM, Sklavounou A (2018) Drug-associated hyperpigmentation of the oral mucosa: report of 4 cases. *Oral Surg Oral Med Oral Pathol Oral Radiol* 125:54–66
- Singh N, Bakhshi S (2007) Imatinib-induced dental hyperpigmentation in childhood chronic myeloid leukemia. *J Pediatr Hematol Oncol* 29:208–209
- Mcpherson T, Sherman V, Turner R (2009) Imatinib-associated hyperpigmentation, a side effect that should be recognized. *J Eur Acad Dermatol Venereol* 23:82–83
- Resende RG, Teixeira RGL, de Oliveira Vasconcelos F, de Souza Silva ME, Abreu MHG, Gomez RS (2012) Imatinib-associated hyperpigmentation of the palate in post-HSCT patient. *J Cranio-Maxillofac Surg* 40:140–143
- Steele JC, Triantafyllou A, Rajlawat BP, Field EA (2012) Oral mucosal hyperpigmentation and horizontal melanonychia caused by imatinib. *Clin Exp Dermatol* 37:432–433

32. López-Labady J, Villarroel-Dorrego M, Bascones Martínez A (2013) Pigmentación inusual del paladar asociada a imatinib: reporte de caso clínico. *Av Odontostomatol* 29:309–314
33. Song HS, Kang HY (2014) Imatinib mesylate-induced hyperpigmentation of the nose and palate. *Ann Dermatol* 26:532–533
34. Lyne A, Creedon A, Bailey BM (2015) Mucosal pigmentation of the hard palate in a patient taking imatinib. *BMJ Case Rep pii: bcr2015209335*
35. Romeo U, Palaia G, Fantozzi PJ, Tenore G, Bosco D (2015) A rare case of melanosis of the hard palate mucosa in a patient with chronic myeloid leukemia. *Case Rep Dent* 817094
36. Bombeccari GP, Garagiola U, Pallotti F, Rossi M, Porrini M, Gianni AB, Spadari F (2017) Hyperpigmentation of the hard palate mucosa in a patient with chronic myeloid leukaemia taking imatinib. *Maxillofac Plast Reconstr Surg* 39:37
37. Di Tullio F, Mandel VD, Scotti R, Padalino C, Pellacani G (2018) Imatinib-induced diffuse hyperpigmentation of the oral mucosa, the skin, and the nails in a patient affected by chronic myeloid leukemia: report of a case and review of the literature. *Int J Dermatol* 57: 784–790
38. Torres-Pereira CC (2011) Are we ready to blame imatinib for palatal pigmentation? *Oral Surg Oral Med Oral Pathol Oral Radiol Endod* 112:287
39. American Cancer Society (2016) Cancer treatment and survivorship facts & figures 2016–2017. American Cancer Society, Atlanta
40. Redaelli A, Bell C, Casagrande J, Stephens J, Botteman M, Laskin B, Pashos C (2004) Clinical and epidemiologic burden of chronic myelogenous leukemia. *Expert Rev Anticancer Ther* 4:85–96
41. Rix U, Hantschel O, Dürnberger G et al (2007) Chemical proteomic profiles of the BCR-ABL inhibitors imatinib, nilotinib, and dasatinib reveal novel kinase and nonkinase targets. *Blood* 110: 4055–4063
42. Goldman JM, Melo JV (2001) Targeting the BCR-ABL tyrosine kinase in chronic myeloid leukemia. *New Engl J Med* 344:1084–1086
43. Gambacorti-Passerini C, Antolini L, Mahon FX, Guillhot F, Deininger M, Fava C, Nagler A, Della Casa CM, Morra E, Abruzzese E, D'Emilio A, Stagno F, le Coutre P, Hurtado-Monroy R, Santini V, Martino B, Pane F, Piccin A, Giraldo P, Assouline S, Durosini MA, Leeksma O, Pogliani EM, Puttini M, Jang E, Reiffers J, Piazza R, Valsecchi MG, Kim DW (2011) Multicenter independent assessment of outcomes in chronic myeloid leukemia patients treated with imatinib. *J Natl Cancer Inst* 103: 553–561
44. Jain P, Das VNR, Ranjan A, Chaudhary R, Pandey K (2013) Comparative study for the efficacy, safety and quality of life in patients of chronic myeloid leukemia treated with Imatinib or hydroxyurea. *J Res Pharm Pract* 2:156–161
45. Airiau K, Turcq B, Mahon FX, Belloc F (2017) A new mechanism of resistance to ABL1 tyrosine kinase inhibitors in a BCR-ABL1-positive cell line. *Leuk Res* 61:44–52
46. Miettinen M, Lasota J (2005) KIT (CD117): a review on expression in normal and neoplastic tissues, and mutations and their clinicopathologic correlation. *Appl Immunohistochem Mol Morphol* 13: 205–220
47. Jeon S, Kim NH, Kim JY, Lee AY (2009) Stem cell factor induces ERM proteins phosphorylation through PI3K activation to mediate melanocyte proliferation and migration. *Pigment Cell Melanoma Res* 22:77–85
48. Wehrle-Haller B (2003) The role of Kit-ligand in melanocyte development and epidermal homeostasis. *Pigment Cell Melanoma Res* 16:287–296
49. Cario-André M, Ardilouze L, Pain C, Gauthier Y, Mahon FX, Taieb A (2006) Imatinib mesilate inhibits melanogenesis in vitro. *Br J Dermatol* 155:493–494
50. Buchdunger E, Cioffi CL, Law N, Stover D, Ohno-Jones S, Druker BJ, Lydon NB (2000) Abl protein-tyrosine kinase inhibitor STI571 inhibits in vitro signal transduction mediated by c-kit and platelet-derived growth factor receptors. *J Pharmacol Exp Ther* 295:139–145
51. Arora B, Kumar L, Sharma A, Wadhwa J, Kochupillai V (2004) Pigmentary changes in chronic myeloid leukemia patients treated with imatinib mesylate. *Ann Oncol* 15:358–359
52. Robson ME, Glogowski E, Sommer G, Antonescu CR, Nafa K, Maki RG, Ellis N, Besmer P, Brennan M, Offit K (2004) Pleomorphic characteristics of a germ-line KIT mutation in a large kindred with gastrointestinal stromal tumors, hyperpigmentation, and dysphagia. *Clin Cancer Res* 10:1250–1254
53. Alexandrescu DT, Dasanu CA, Farzanmehr H, Kauffman CL (2008) Persistent cutaneous hyperpigmentation after tyrosine kinase inhibition with imatinib for GIST. *Dermatol Online J* 14:7
54. Lerman MA, Karimbux N, Guze KA, Woo SB (2009) Pigmentation of the hard palate. *Oral Surg Oral Med Oral Pathol Oral Radiol Endod* 107:8–12
55. de Andrade BAB, Fonseca FP, Pires FR, Mesquita ATM, Falci SGM, dos Santos Silva AR, Vargas PA, Jorge J, de Almeida OP (2013) Hard palate hyperpigmentation secondary to chronic chloroquine therapy: report of five cases. *J Cutan Pathol* 40: 833–838
56. Meleti M, Vescovi P, Mooi WJ, van der Waal I (2008) Pigmented lesions of the oral mucosa and perioral tissues: a flow-chart for the diagnosis and some recommendations for the management. *Oral Surg Oral Med Oral Pathol Oral Radiol Endod* 105:606–616
57. Gondak RO, da Silva-Jorge R, Jorge J, Lopes MA, Vargas PA (2012) Oral pigmented lesions: clinicopathologic features and review of the literature. *Med Oral Patol Oral Cir Bucal* 17:919
58. Eisen D (2000) Disorders of pigmentation in the oral cavity. *Clin Dermatol* 18:579–587
59. Kauzman ABDS, Pavone M, Blanas N, Bradley G (2004) Pigmented lesions of the oral cavity: review, differential diagnosis, and case presentations. *J Can Dent Assoc* 70:682–683
60. Axeix T, HEDIN CA (1982) Epidemiologic study of excessive oral melanin pigmentation with special reference to the influence of tobacco habits. *Eur J Oral Sci* 90:434–442
61. Lenane P, Powell FC (2000) Oral pigmentation. *J Eur Acad Dermatol Venereol* 14:448–465
62. Kleinegger CL, Hammond HL, Finkelstein MW (2000) Oral mucosal hyperpigmentation secondary to antimalarial drug therapy. *Oral Surg Oral Med Oral Pathol Oral Radiol Endod* 90:189–194
63. Kim HW (1988) Generalized oral and cutaneous hyperpigmentation in Addison's disease. *Odontostomatol Trop= Trop Dent J* 11: 87–90
64. Machaczka M, Gossart M (2013) Multiple skin lesions caused by imatinib mesylate treatment of chronic myeloid leukemia. *Pol Arch Med Wewn* 123:251–252
65. Dervis E, Ayer M, Belli AA, Barut SG (2016) Cutaneous adverse reactions of imatinib therapy in patients with chronic myeloid leukemia: a six-year follow up. *Eur J Dermatol* 26:133–137

Publisher's note Springer Nature remains neutral with regard to jurisdictional claims in published maps and institutional affiliations.