

# Piriformis Pyomyositis in a Patient with Kikuchi-Fujimoto Disease – A Case Report and Literature Review\*

## *Piomiosite do piriforme em um paciente com doença de Kikuchi-Fujimoto – relato de caso e revisão da literatura*

Antônio Augusto Guimarães Barros<sup>1</sup> Cláudio Beling Gonçalves Soares<sup>1</sup> Eduardo Frois Temponi<sup>1</sup>  
Victor Atsushi Kasuya Barbosa<sup>1</sup> Luiz Eduardo Moreira Teixeira<sup>1</sup> George Grammatopoulos<sup>2</sup>

<sup>1</sup>Hospital Madre Teresa, Belo Horizonte, MG, Brazil

<sup>2</sup>The Ottawa Hospital, Ottawa, Canada

Address for correspondence Antônio Augusto Guimarães Barros,  
Hospital Madre Teresa, Belo Horizonte, MG, Brazil  
(e-mail: antonioagbarros@gmail.com).

Rev Bras Ortop 2019;54:214–218.

### Abstract

#### Keywords

- ▶ pyomyositis
- ▶ staphylococcus aureus
- ▶ histiocytic necrotizing lymphadenitis

Primary pyomyositis is a deep bacterial infection of the skeletal muscle. If left undiagnosed and untreated, the infection spreads, leading to sepsis, septic shock, and even death. The authors report a 23-year-old female presenting with piriformis pyomyositis during a treatment for Kikuchi–Fujimoto disease. Pyomyositis is a rare but potentially severe infection, which can lead to septic shock. The present case shows the need for a high degree of clinical suspicion for patients with compromised immune systems to begin treatment at an early stage. The literature demonstrates that outcomes of the treatment of piriformis pyomyositis are good.

### Resumo

#### Palavras-chave

- ▶ piomiosite
- ▶ staphylococcus aureus
- ▶ linfadenite necrotizante histiocítica

A piomiosite primária é uma infecção bacteriana profunda do músculo esquelético. Quando não diagnosticada ou tratada, a infecção pode evoluir para sepse, choque séptico e até morte. Os autores relatam o caso de uma paciente do sexo feminino, 23 anos, apresentando piomiosite do músculo piriforme durante o tratamento da doença de Kikuchi–Fujimoto. A piomiosite é uma infecção rara, mas potencialmente grave, que pode levar ao choque séptico. O presente caso mostra a necessidade em se elevar o grau de suspeição clínica em pacientes com comprometimento do sistema imunológico, para que o tratamento seja iniciado em estágio precoce. A literatura mostra que os resultados do tratamento da piomiosite do piriforme são bons.

### Introduction

Primary pyomyositis is a deep bacterial infection of the skeletal muscle, and it commonly manifests as a local abscess. It can affect people of any age, but is most common in the first and second decades of life, with a higher incidence

among males. Any muscle can be affected, but the disease is more frequent in large muscle groups located around the pelvic girdle and lower limbs.<sup>1,2</sup> The diagnosis is often delayed because of its rarity, nonspecific clinical presentation, and involvement of muscles located in deep compartments. It is typically subacute, and the patient seeks treatment within an average of 5 to 6 days following the onset of symptoms.<sup>2</sup> In most cases, the patient presents with fever, pain in the affected region, and leukocytosis. The

\* Work performed in the Hospital Madre Teresa, Belo Horizonte, MG, Brazil in association with The Ottawa Hospital, Ottawa, Canada.

received  
August 13, 2017  
accepted  
September 13, 2017  
published online  
April 15, 2019

DOI <https://doi.org/10.1016/j.rboe.2017.09.005>  
ISSN 0102-3616.

Copyright © 2019 by Sociedade Brasileira de Ortopedia e Traumatologia. Published by Thieme Revinter Publicações Ltda, Rio de Janeiro, Brazil

License terms



diagnosis is usually established using magnetic resonance imaging (MRI) and confirmed using histopathological examination. The treatment occurs according to the stage in which the infection is diagnosed.<sup>2</sup>

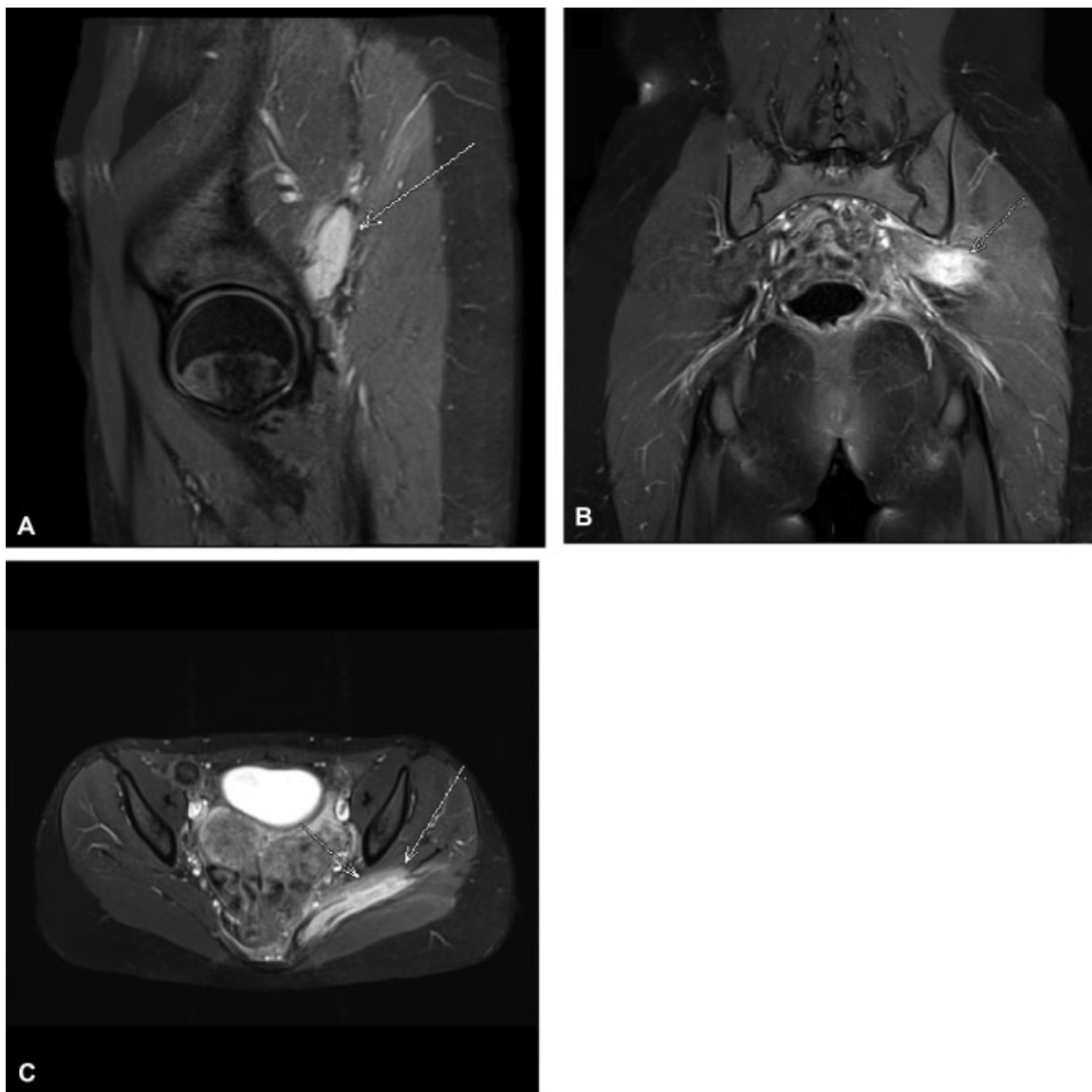
The present study presents a case of piriformis muscle pyomyositis in a patient diagnosed with necrotizing lymphadenitis, also known as Kikuchi–Fujimoto disease (KFD). The Ethics Committee at Hospital Madre Teresa, Belo Horizonte, MG, Brazil approved this study, and written informed consent was obtained from the family of the patient prior to her inclusion in the present study.

## Case Presentation

A 23-year-old female presented to the emergency department with septic shock secondary to a respiratory tract infection and was admitted to the intensive care unit (ICU). She had a history of fever, a poor overall condition,

and weight loss over a preceding period of 2 months. Clinically, in addition to the respiratory distress, there was evidence of cervical lymphadenopathy and hepatosplenomegaly. She had no significant past medical history apart from hypothyroidism. The patient reported an absence of other comorbidities or travel to other countries. She was treated for a lung infection and discharged with a diagnosis of Kikuchi–Fujimoto disease (KFD) after a lymph node biopsy. After 30 days, the patient presented with complaints of a deep left gluteal pain. The patient was then referred to the orthopedic department.

In the orthopedic consultation, the patient reported mild pain in the deep gluteal region. Upon examination, the patient was afebrile, with an atypical gait, pain upon palpation of the deep left gluteal region, and no neurological deficits. The left hip exhibited a mild limitation of motion: 110° flexion, 20° extension, 40° abduction, 20° adduction, 30° internal rotation, and 30° external rotation, as well as pain at the extremes of



**Fig. 1** Magnetic resonance imaging showing increased signaling in the left piriformis muscle associated with the presence of fluid collection. (A) Sagittal plane weighted proton density with fat suppression signal. (B) Coronal T1-weighted fat-suppressed signal after gadolinium contrast. (C) Axial T1-weighted fat-suppressed signal after contrast with gadolinium.

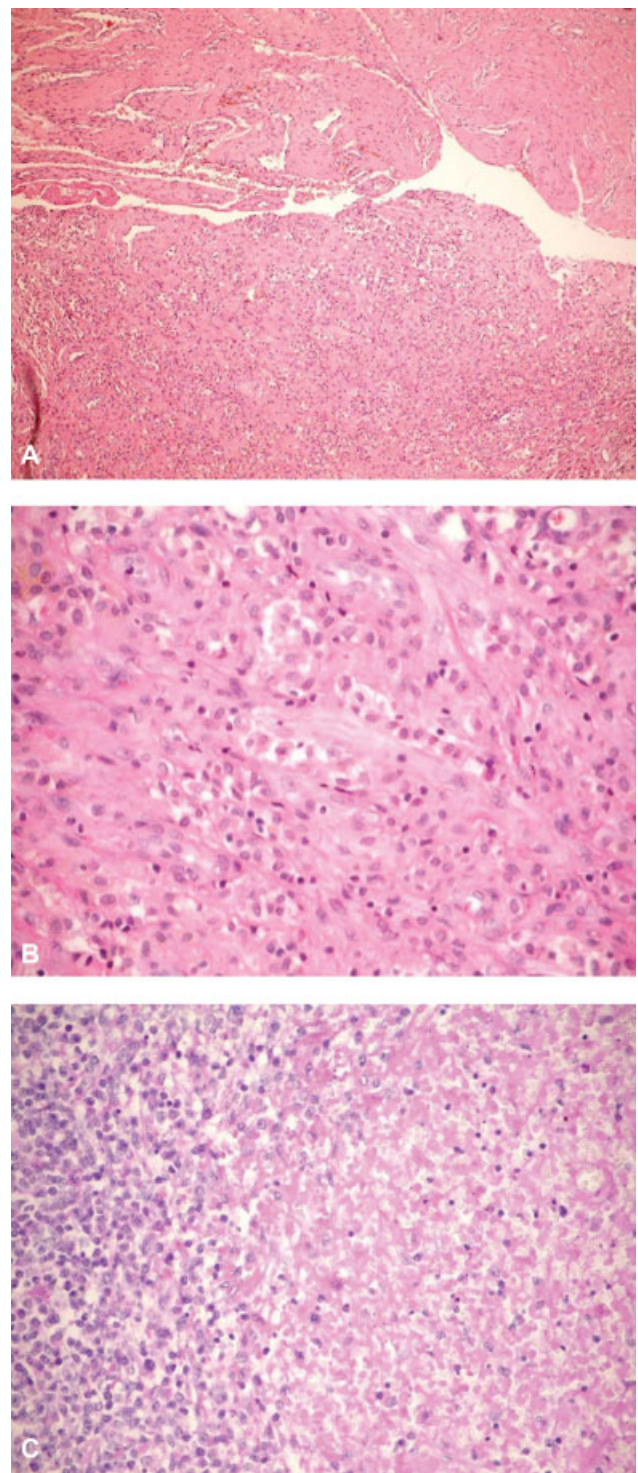
movement. Blood results showed raised inflammatory markers. White blood cells,  $11.7 \times 10^9/L$ ; C-reactive protein (CRP), 65 mg/L; and erythrocyte sedimentation rate (ESR), 51 mm/h. Radiographs of both hips were unremarkable. Magnetic resonance imaging (MRI) was performed and showed increased signaling in the left piriformis muscle associated with the presence of fluid collection (► Fig. 1).

The patient was admitted for open surgical drainage of the piriformis muscle. The results of the samples taken during the procedure showed a culture with the growth of methicillin-resistant *Staphylococcus aureus* (MRSA) and histopathological examination with inflammatory infiltrate (► Fig. 2). Antimicrobial susceptibility test showed vancomycin and trimethoprim-sulfamethoxazole with minimum inhibitory concentrations (MIC) of  $\leq 2 \mu\text{g/mL}$  and of  $\leq 2/38 \mu\text{g/mL}$ , respectively. The patient was treated with an intravenous antibiotic therapy (vancomycin 15 mg/kg every 12 hours) during the first 10 days, followed by oral therapy (160 mg trimethoprim/800 mg sulfamethoxazole every 12 hours) for up to 6 weeks. The patient made an uncomplicated postoperative recovery and was discharged home on day 10. During a return visit 30 days after the surgery, the patient was asymptomatic. Six months after the surgery, the patient did not present with pain or with any functional limitation.

## Discussion

As far as we can determine, the present case report presents the first case reported in the English language of piriformis muscle pyomyositis in a patient diagnosed with KFD. The first detailed description of pyomyositis is attributed to Scriba in 1885.<sup>1</sup> It is more common in tropical countries, but its incidence has increased worldwide. This increase seems to be related to an increase in individuals with compromised immune systems (e.g., individuals with HIV, diabetes, organ transplantation, chemotherapy, malignancies, rheumatic diseases). The exact incidence and prevalence rates are not well-known.<sup>2</sup> The literature contains few reports of pyomyositis affecting the piriformis muscle.<sup>3–13</sup> Unlike the present case, many of these reports discussed patients who had sciatica with severe symptoms and sought medical care in the emergency room, experiencing large changes in laboratory markers of infection (► Table 1).

In a study evaluating 676 cases of pyomyositis, the average age was 28.1 years; in 26.3% of the cases, the quadriceps represented the most commonly affected muscle group, and involvement in more than one muscle group was found to occur in 16.6% of the cases. In many instances, the infecting bacteria were not identified; however, among the identified cases, *S. aureus* was responsible for 77% of the cases.<sup>2</sup> The pathogenesis of pyomyositis is still not completely understood. It is believed that it occurs as a complication of transient bacteremia associated with a local muscle tissue abnormality.<sup>14</sup> The evolution of pyomyositis can be clinically divided into three stages.<sup>2,14</sup> The invasive stage is subacute and occurs in between 1 and 3 weeks. The patient presents with local pain, edema, fever, and leukocytosis. There is no pus. This stage may regress or progress to the next stage. The



**Fig. 2** (A) Photomicrograph of piriformis pyomyositis. Fibromuscular tissue with a moderate lymphohistiocytic inflammatory infiltrate (hematoxylin and eosin  $\times 100$ ). (B) Photomicrograph of piriformis pyomyositis, higher magnification of inflammatory tissue (hematoxylin and eosin  $\times 400$ ). (C) Photomicrographs of lymph node biopsy showing focal necrosis surrounded by karyorrhectic debris, histiocytes and plasmacytoid lymphocytes (hematoxylin and eosin,  $\times 400$ ).

suppurative stage is when the diagnosis is usually made and is characterized by a worsening of symptoms, fever, and abscess formation. However, because of its deep location, classic signs of inflammation may be absent. If the

**Table 1** Features of pyomyositis affecting the piriformis muscle previously reported in the english literature at the MEDLINE/ PubMed database

Authors	Number of cases	Age (years)	Management	Outcome
Burkhart et al <sup>3</sup>	1	69	CT-guided aspiration	Full resolution of symptoms and return to sporting activities.
Chusid et al <sup>4</sup>	1	17	Intravenous antibiotics	By day 10 of treatment, the inflammatory markers of the patient returned to normal.
Wong et al <sup>5</sup>	3	45	Intravenous antibiotics	The pain gradually subsided and inflammatory markers returned to normal.
		58	CT-guided aspiration	Fever and pain subsided after drainage and 2 weeks of intravenous antibiotics.
		71	Intravenous antibiotics	The pain and fever subsided and the myositis resolved after 2 weeks of intravenous antibiotics.
Wong et al <sup>6</sup>	1	31	Intravenous antibiotics	Blood parameters and clinical symptoms improved throughout the course of the treatment. No residual symptoms.
Chong et al <sup>7</sup>	1	30	Intravenous antibiotics	A follow-up visit in the clinic showed full recovery with normalized ESR and CRP.
Toda et al <sup>8</sup>	1	06	Oral antibiotics	Final follow-up at 6 months revealed full range of motion of the hip joint with no pain.
Koda et al <sup>9</sup>	1	42	Open surgical drainage followed by antibiotic treatment	Dramatic relief of pain after the surgery. Patient returned to work after 2 months.
Giebalý et al <sup>10</sup>	1	18	Intravenous antibiotics	Full resolution of symptoms and return to sporting activities after 6 months.
Colmegna et al <sup>11</sup>	1	18	CT-guided aspiration	After 4 weeks, the patient was fully recovered.
Kinahan et al <sup>12</sup>	1	22	Intravenous antibiotics	Full recovery after 6 weeks of intravenous antibiotic therapy.
Gaughan et al <sup>13</sup>	1	34	Intravenous antibiotics	After 8 weeks, the patient was still using crutches to mobilize and was still reliant on analgesics.
(current case)	1	23	Open surgical drainage followed by antibiotic treatment	Asymptomatic after 6 months.

Abbreviations: CT, computed tomography; CRP, C-reactive protein; ESR, erythrocyte sedimentation rate.

suppurative stage remains undiagnosed and untreated, the infection spreads, leading to the late stage, which is characterized by sepsis, septic shock, and even death.<sup>2,14</sup>

Laboratory tests are able to detect variable leukocytosis, particularly in the invasive stage, but the shift to the left occurs during the suppurative stage. The ESR and CRP inflammatory markers are elevated but are not specific. Blood cultures are sterile in between 70 and 80% of the cases.<sup>14</sup> Nuclear MRI is the most useful imaging methodology for the diagnosis of pyomyositis; it reveals diffuse muscle inflammation and subsequent abscess formation. The administration of a contrast helps in detecting an abscess. A muscle biopsy associated with tissue culture remains the gold standard for the diagnosis.<sup>14</sup> In the present case, the patient was asymptomatic, without systemic effects of infection, and with little change in laboratory tests, probably because of the use of trimethoprim/sulfamethoxazole to prevent opportunistic infections during the treatment of lymphoma.

Pyomyositis is treated according to the stage in which it is diagnosed. During the early stage, diffuse inflammatory

disorders can be treated with antibiotics alone.<sup>7</sup> However, after the formation of an abscess, a drain should be performed, followed by antibiotic therapy.<sup>9</sup> This treatment allows for a full recovery without sequelae in most cases. Drainage can be accomplished via percutaneous puncture guided by ultrasound (US) or CT, and open surgery is performed in cases of incomplete drainage, with extensive muscle damages requiring extensive debridement. Intravenous antibiotic therapy should be applied during the first 7 to 10 days, followed by oral therapy for up to 6 weeks.<sup>2</sup>

Our report presents an association between piriformis pyomyositis and the rare KFD. Kikuchi–Fujimoto disease is a benign and usually self-limiting disease that mainly affects women < 30 years old. Most cases are resolved within 6 months. Its etiology is unknown, but a correlation with viral infections and autoimmune disorders has been reported. The patient presents with fever, fatigue, swollen lymph nodes, and upper respiratory tract symptoms. Often, the diagnosis is confused with other diseases such as lymphoma, and it is confirmed using lymph node biopsy.<sup>15</sup>

## Conclusion

Pyomyositis is a rare and potentially severe infection that can lead to septic shock. The present case shows the need for a high level of suspicion in patients with compromised immune systems so that treatment can be carried out at an early stage. The reviewed medical literature shows that, despite the potentially severe infection occurs, the treatment outcome is most commonly very good.

### Conflicts of Interests

The authors have no conflicts of interests to declare.

## References

- 1 Scriba J, Beirang Z. Aetiologie der myositis acuta. *Deutsche Zeit Chir.* 1885;22:497–502
- 2 Bickels J, Ben-Sira L, Kessler A, Wientroub S. Primary pyomyositis. *J Bone Joint Surg Am* 2002;84-A(12):2277–2286
- 3 Burkhart BG, Hamson KR. Pyomyositis in a 69-year-old tennis player. *Am J Orthop* 2003;32(11):562–563
- 4 Chusid MJ, Hill WC, Bevan JA, Sty JR. Proteus pyomyositis of the piriformis muscle in a swimmer. *Clin Infect Dis* 1998;26(01):194–195
- 5 Wong CH, Choi SH, Wong KY. Piriformis pyomyositis: a report of three cases. *J Orthop Surg (Hong Kong)* 2008;16(03):389–391
- 6 Wong LF, Mullers S, McGuinness E, Meaney J, O'Connell MP, Fitzpatrick C. Piriformis pyomyositis, an unusual presentation of leg pain post partum—case report and review of literature. *J Matern Fetal Neonatal Med* 2012;25(08):1505–1507
- 7 Chong KW, Tay BK. Piriformis pyomyositis: a rare cause of sciatica. *Singapore Med J* 2004;45(05):229–231
- 8 Toda T, Koda M, Rokkaku T, Watanabe H, Nakajima A, Yamada T, et al. Sciatica caused by pyomyositis of the piriformis muscle in a pediatric patient. *Orthopedics* 2013;36(02):e257–e259
- 9 Koda M, Mannoji C, Watanabe H, Nakajima A, Yamada T, Rokkaku T, et al. Sciatica caused by pyomyositis of the piriformis muscle. *Neurol India* 2013;61(06):668–669
- 10 Giebaly DE, Horriat S, Sinha A, Mangaleshkar S. Pyomyositis of the piriformis muscle presenting with sciatica in a teenage rugby player. *BMJ Case Rep* 2012;2012:bcr1220115392. Doi: 10.1136/bcr.12.2011.5392
- 11 Colmegna I, Justiniano M, Espinoza LR, Gimenez CR. Piriformis pyomyositis with sciatica: an unrecognized complication of “unsafe” abortions. *J Clin Rheumatol* 2007;13(02):87–88
- 12 Kinahan AM, Douglas MJ. Piriformis pyomyositis mimicking epidural abscess in a parturient. *Can J Anaesth* 1995;42(03):240–245
- 13 Gaughan E, Eogan M, Holohan M. Pyomyositis after vaginal delivery. *BMJ Case Rep* 2011;2011:bcr0420114109. Doi: 10.1136/bcr.04.2011.4109
- 14 Agarwal V, Chauhan S, Gupta RK. Pyomyositis. *Neuroimaging Clin N Am* 2011;21(04):975–983, x
- 15 Marunaka H, Orita Y, Tachibana T, Miki K, Makino T, Gion Y, et al. Kikuchi-Fujimoto disease: evaluation of prognostic factors and analysis of pathologic findings. *Acta Otolaryngol* 2016;136(09):944–947