

Preoperative progressive pneumoperitoneum for a giant incisional hernia: report of a case with a rare complication

Correção de hérnia incisional gigante com uso do pneumoperitônio progressivo pré-operatório: relato de caso com uma complicação rara

Vinicius Rodrigues Taranto Nunes¹, Rafael Calvão Barbuto², José Renan Cunha-Melo², Mario Pastore Neto³, Carla Jorge Machado², Galileu Chagas Lourenço², Guilherme Nogueira Pena¹, Marcello Fonseca Marino¹, David Silveira Farias¹, Ingrid Bremer Toledo²

ABSTRACT

In patients with giant incisional hernias, many anatomical and physiological changes turn hernia repair into quite a challenge. The possibility of developing complications as abdominal compartment syndrome after hernioplasty has prompted surgeons to seek for technical options. A tempting alternative is to induce progressive preoperative pneumoperitoneum (PPP) aiming to adapt the organism to an increase in the abdominal content. We describe the case of a patient with giant incisional hernia submitted to PPP complicated by symptomatic pneumomediastinum. Despite being frequently well tolerated, it is important to make a point that the induction of PPP may result in severe complications.

Keywords: pneumoperitoneum, artificial; mediastinal emphysema; incisional hernia; preoperative care; herniorrhaphy.

RESUMO

Em pacientes com hérnias incisionais gigantes, a correção da hérnia se torna um desafio devido às diversas alterações anatômicas e fisiológicas. O risco de desenvolvimento de complicações como a síndrome de compartimento abdominal após a hernioplastia levou à busca por opções técnicas. Uma alternativa viável para evitar essas complicações é induzir pneumoperitônio progressivo pré-operatório (PPP) visando adaptar o organismo ao aumento do conteúdo abdominal. É relatado caso de um paciente com hérnia incisional gigante submetido à PPP que complicou com pneumomediastino sintomático. Apesar de ser frequentemente bem tolerada pelos pacientes, deve-se ter em mente que a indução de PPP pode resultar em complicações graves.

Palavras-chave: pneumoperitônio artificial; enfisema mediastínico; hérnia incisional; cuidados pré-operatórios; herniorrafia.

INTRODUCTION

The surgical repair of giant hernias remains a challenge for surgeons and may lead to anatomic distortions, intra-abdominal hypertension, abdominal compartment syndrome and increased intrathoracic pressure. Many alternatives were created to facilitate the treatment of hernias with loss of domain.¹ Progressive preoperative pneumoperitoneum (PPP) is a technique recommended for patients with giant hernias, when forced reduction of the content might result in abdominal compartment syndrome.² We present a case of a patient with giant incisional right subcostal hernia who underwent PPP and had a rare complication.

CASE REPORT

A seventy-eight-year-old man presented with a giant incisional hernia, with loss of domain, in the right hipocondrium (Figure 1). It was a result of an urgent open cholecystectomy done one year earlier due to cholecystitis and cholecystopleural fistula.

At the time of admission, he complained of abdominal pain and discomfort, which interfered with his daily activities. His medical history was significant for arterial hypertension and tabagism. On physical examination, a giant unreducible hernia was found in the right hipocondrium, without other abnormalities.

¹Universidade Federal de Minas Gerais, Hospital das Clínicas – Belo Horizonte (MG), Brazil.

²Universidade Federal de Minas Gerais, Faculdade de Medicina – Belo Horizonte (MG), Brazil.

³Hospital Risoleta Tolentino Neves – Belo Horizonte (MG), Brazil.

Corresponding author: Carla Jorge Machado – Universidade Federal de Minas Gerais, Faculdade de Medicina, Departamento de Medicina Preventiva e Social – Avenida Professor Alfredo Balena, 190, 8º andar – Santa Efigênia – CEP: 30130-100 – Belo Horizonte (MG), Brasil – E-mail: carlajmachado@gmail.com

Received on 04/29/2016. Accepted for publication on 12/07/2016.

The patient underwent the PPP. Firstly, 1,000 mL of ambient air was injected into peritoneal cavity and pneumoperitoneum was confirmed by chest x-ray. Then, approximately 2,000 mL of air was injected daily according to patient's tolerance. The patient was advised to wear an abdominal support belt in order to distribute the gas equally in the abdominal cavity. On the 6th day, the catheter implantation site revealed signs of infection, thus it was removed. From this day on, a pneumoperitoneum was carried out through daily abdominal puncture under local anesthesia.

On the 12th day of pneumoperitoneum, during a Val-salva's maneuver, the patient complained of severe thoracic

and facial pain. On physical examination, there was important subcutaneous emphysema in the neck and face. His vital signs were stable and the electrocardiogram showed no abnormalities. A chest X-ray revealed significant pneumomediastinum (Figure 2). We opted for a conservative treatment, with withdrawal of some air through abdominal puncture until symptoms alleviation, and the patient was kept under close observation.

Three days later, he underwent surgery for hernia repair, the pneumoperitoneum was removed and the hernia was reduced, resulting in a good outcome (Figure 3).

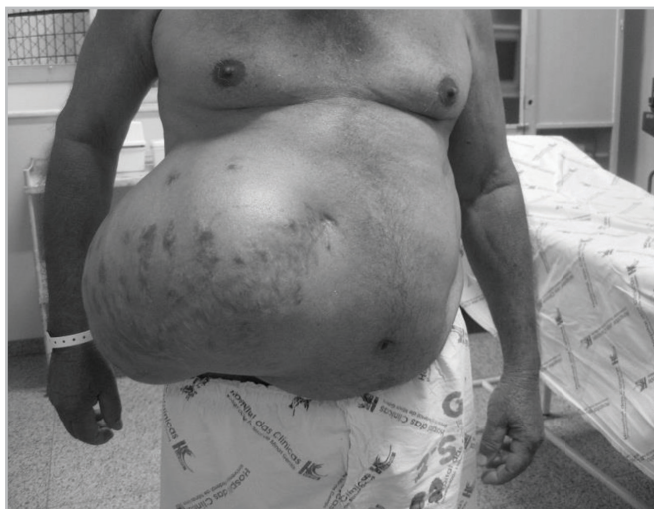

Figure 1. Patient presented with a giant right subcostal incisional hernia at admission.

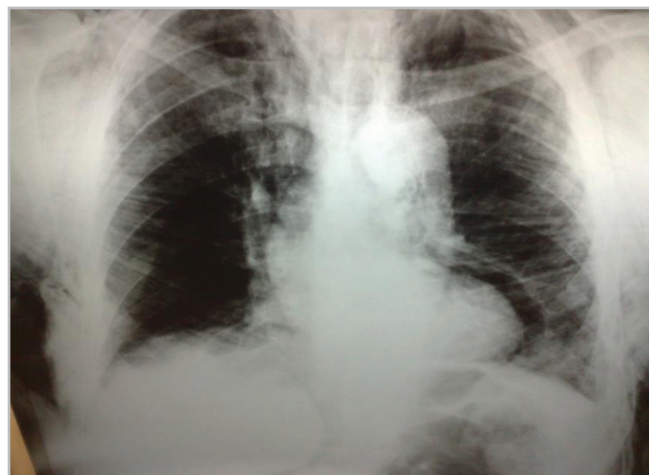

Figure 2. Chest x-ray revealed pneumomediastinum and subcutaneous emphysema which also dissected thoracic musculature. No signs of pneumothorax were seen.

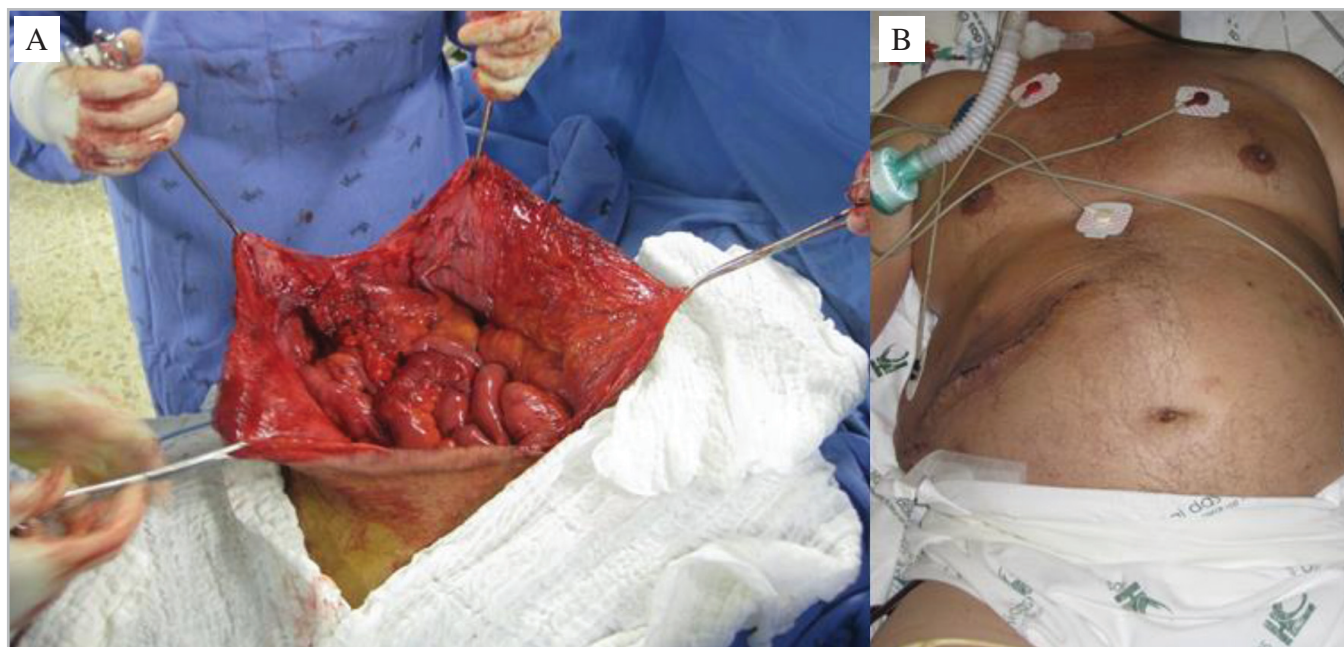


Figure 3. (A) the hernia sac was dissected until the hernia ring was found. The sac was opened and fine adhesions were lysed. (B) the final aspect of the abdominal wall right after hernia repair.

DISCUSSION

Diagnosis of incisional hernia requires the study of patients' history and clinical examination. It may present itself as asymptomatic or associated with pain (20 to 50%), and a prominence is noted in the region of previous surgery suture.

Although incisional hernia is a common surgical complication, its definition has yet to be internationally standardized, which will improve the analysis of the exact prevalence and aspects of this comorbidity. A great difficulty that differs incisional hernias from abdominal wall hernias is the repair process of a laparotomy, which involves several layers of different tissue wall that need to be sutured, positive abdominal pressure and decreased tissue perfusion, thus favoring the incidence of this complication.³

Other surgical and nonsurgical risk factors are involved in the etiology of incisional hernias such as obesity, advanced age (>65 years), multiple laparotomies, type of incision and suture (including the material used), Chronic Obstructive Pulmonary Disease and Diabetes.⁴

A higher incidence is observed in the first 5 years after the surgical procedure, and the late onset usually presents itself in a smaller hernia size. The recurrence is common and seems to be related with the surgical procedure chosen.⁵

In patients with loss of abdominal domain, anatomical and physiological changes tend to complicate hernia repair. The immediate reintroduction of the hernia content into the abdominal cavity increases abdominal pressure and may lead to many complications, such as compartment syndrome.^{6,7}

Many techniques are used to attenuate these physiological alterations. For more than 60 years,⁸ PPP was applied to progressively increase the capacity of the abdominal cavity, improve diaphragmatic function,⁷ perform pneumatic lysis of intestinal adhesion, locate other hernias and reduce turgidity and volume of hollow organs.^{1,2,9-13} In the reported case, the pneumoperitoneum facilitated adhesiolysis, reduction of the hernia content and closure of the defect.

PPP is indicated when hernioplasty cannot be performed due to loss of domain or when the forced reduction might cause abdominal compartment syndrome.^{6,12} Most complications related to PPP are self-limited and not life-threatening. The most frequent complications described are catheter dislodgment,^{1,9,13} port-site infection or bleeding,^{1,13} hemo-peritoneum^{13,14} and accidental insufflation of air in a hollow viscera.¹⁴ Many complications can be prevented with simple measures such as inducing the PPP in the surgical ward, using a needle with a protection device, administering prophylactic heparin, and monitoring the patient's vital signs and intra-abdominal pressure closely.^{1,11,14}

Other possible complication is the pneumomediastinum, in which air can dissipate through the diaphragm. Hamer and Duthie¹⁵ described a series of ten patients treated with PPP, among which one of them developed pneumomediastinum, being this the only report of such outcome. Despite the rarity of this complication due to PPP, it is well-described in pneumoperitoneum induced for laparoscopy.^{16,17} In the pa-

tient reported, the abdominal support belt used by the patient favored the extreme increase in abdominal pressure and the Valsalva's maneuver triggered the pneumomediastinum.

CONCLUSION

PPP is highly recommended for giant hernia repairs for their physiological effects in the whole body, but it is not harmless as first described⁸ in 1947 and its complications must be taken into consideration during the procedure as well as measures should be taken to prevent them.

CONFLICT OF INTERESTS

The authors declare that they have no conflict of interest.

ACKNOWLEDGEMENTS

We would like to thank Bernardo Milani M.D., for the suggestions made for the improvement of this article.

REFERENCES

1. Mcadory RS, Cobb WS, Carbonell AM. Progressive preoperative pneumoperitoneum for hernias with loss of domain. *Am Surg.* 2009; 75(6):504-9.
2. Mayagoitia JC, Suárez D, Arenas JC, León VD. Preoperative progressive pneumoperitoneum in patients with abdominal-wall hernias. *Hernia.* 2006; 10:213-7. DOI: 10.1007/s10029-005-0040-8
3. Sanders DL, Kingsnorth AN. The modern management of incisional hernias. *BMJ.* 2012;344:e2843. DOI: 10.1136/bmj.e2843
4. Hesselink VJ, Luijendijk RW, de Wilt JH, Heide R, Jeekel. An evaluation of risk factors in incisional hernia recurrence. *Surg Gynecol Obstet.* 1993; 176(3):228-34.
5. Mudge M, Hughes LE. Incisional hernia: a 10 year prospective study of incidence, attitudes. *Br J Surg.* 1985;72:70-1.
6. Astudillo R, Merrell R, Sanchez J, Olmedo S. Ventral herniorrhaphy aided by pneumoperitoneum. *Arch Surg.* 1986;121(8):935-6. DOI:10.1001/archsurg.1986.01400080081014
7. Swelstad J, Caprini JA. Use of progressive pneumoperitoneum in the treatment of giant abdominal hernias. *Am Surg.* 1978;44(6):337-41.
8. Goñi-Moreno I. Chronic eventration and large hernias: preoperative treatment by progressive pneumoperitoneum: original procedure. *Surgery.* 1947;22(6):945-53.
9. Caldironi MW, Romano M, Bozza F, Pluchinotta AM, Pelizzo MR, Toniato A, et al. Progressive pneumoperitoneum in the management of giant incisional hernias: a study of 41 patients. *Br J Surg.* 1990;77(3):306-7. DOI: 10.1002/bjs.1800770322
10. Johnson WC. Preoperative progressive pneumoperitoneum in the preparation for repair of large hernias of the abdominal wall. *Am J Surg.* 1972;124(1):63-8. DOI: 10.1016/0002-9610(72)90169-9

11. Minossi JG, Oliveira WK, Llanos JC, Ielo SM, Hasimoto CN, Pereira RSC. O uso do pneumoperitônio progressivo no pré-operatório das hérnias volumosas da parede abdominal. *Arq Gastroenterol.* 2009;46(2):121-6. DOI: 10.1590/S0004-28032009000200009
12. Piskin T, Aydin C, Barut B, Dirican A, Kayaalp C. Preoperative progressive pneumoperitoneum for giant inguinal hernias. *Ann Saudi Med.* 2010;30(4):317-20. DOI: 10.4103/0256-4947.65268
13. Toniato A, Pagetta C, Bernante P, Piotto A, Pelizzo MR. Incisional hernia treatment with progressive pneumoperitoneum and retromuscular prosthetic hernioplasty. *Langenbecks Arch Surg.* 2002;387:246-8. DOI: 10.1007/s00423-002-0316-8
14. Raynor RW, Del Guercio LR. The place of pneumoperitoneum in the repair of massive hernia. *World J Surg.* 1989;13(5):581-5.
15. Hamer DB, Duthie HL. Pneumoperitoneum in the management of abdominal incisional hernia. *Br J Surg.* 1972;59(5):372-5. DOI: 10.1002/bjs.1800590510
16. Murdock CM, Wolff AJ, Van Geem T. Risk factors for hypercarbia, subcutaneous emphysema, pneumothorax, and pneumomediastinum during laparoscopy. *Obstet Gynecol.* 2000;95(5):704-9.
17. Richard HM 3rd, Stancato-Pasik A, Salky BA, Mendelson DS. Pneumothorax and pneumomediastinum after laparoscopic surgery. *Clin Imaging.* 1997;21(5):337-9.

How to cite this article:

Nunes VRT, Barbuto RC, Cunha-Melo JR, Pastore Neto M, Machado CJ, Lourenço GC, et al. Preoperative progressive pneumoperitoneum for a giant incisional hernia: report of a case with a rare complication. *Rev Fac Ciênc Méd Sorocaba.* 2018;20(1):55-8. DOI: 10.23925/1984-4840.2018v20i1a13