



Preliminary Report

# Complications and Management of Polymethylmethacrylate (PMMA) Injections to the Midface

Aesthetic Surgery Journal  
2016, Vol 36(2) 132–135  
© 2015 The American Society for  
Aesthetic Plastic Surgery, Inc.  
Reprints and permission:  
journals.permissions@oup.com  
DOI: 10.1093/asj/sjv195  
www.aestheticsurgeryjournal.com  
**OXFORD**  
UNIVERSITY PRESS

Roberto Murillo Limongi, MD; Jeremiah Tao, MD; André Borba, MD; Filipe Pereira, MD; Ana Rosa Pimentel, MD; Patrícia Akaishi, MD; and Antônio Augusto Velasco e Cruz, MD, PhD

## Abstract

**Background:** Polymethylmethacrylate (PMMA) has been used as an injectable filler to treat hollows and reduce rhytids. PMMA injections have been associated with several side effects, however, the literature is scarce on periorbital complications and their treatments.

**Objectives:** The purpose of this study is to report a series of complications after periorbital PMMA injections to the midface and to describe their management.

**Methods:** Retrospective chart review, including photography and histopathology when available.

**Results:** The authors identified 11 cases of complications of PMMA injections to the midface. Patient ages ranged from 36 to 62 years (mean, 47 years; median, 44 years). Two (18%) were males and 9 (82%) were females. Adverse effects began between 2 to 24 months after injection (mean, 7.2 months; median, 6 months). All patients had edema, erythema, and contour irregularity. Seven (64%) patients had nodules, 4 (36%) had yellow, xanthomatous skin changes, and 2 (18%) had eyelid malposition. Histopathology demonstrated a giant cell inflammation in 5 of 6 cases. Corticosteroid injection was tried in 6 cases but was associated with minimal clinical improvement. Surgical debulking of the implanted material was performed in 9 (82%) cases and was effective in improving edema, erythema, and nodularity.

**Conclusions:** PMMA injection to the midface may be associated with chronic inflammation, fibrotic nodules, yellowing of the skin, and eyelid malposition. Intralesional corticosteroid injections yielded minimal or no improvement; surgical debulking achieved favorable results.

## Level of Evidence: 4



Accepted for publication September 1, 2015; online publish-ahead-of-print October 7, 2015.

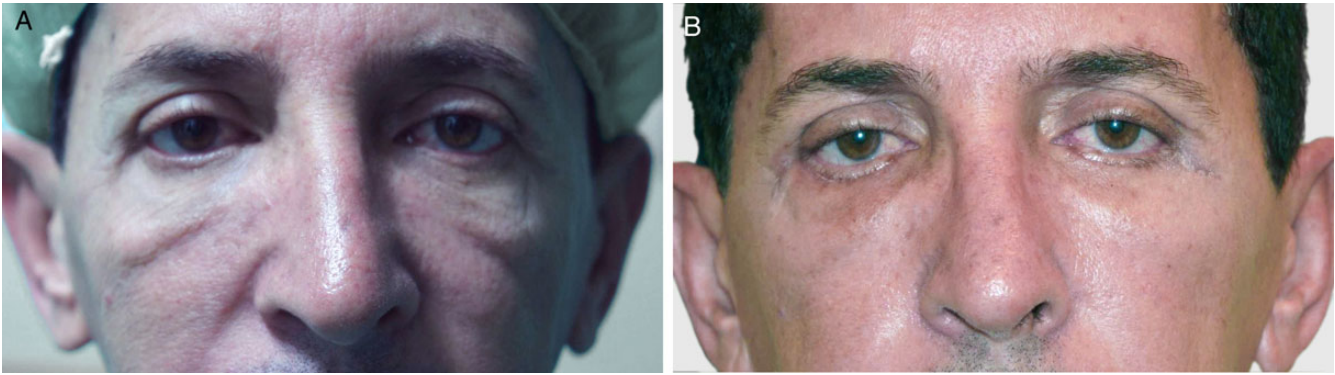
Injectable fillers are increasingly popular alternatives to incisional aesthetic surgery to reduce facial rhytids. Alloplastic fillers may be classified as temporary or permanent. Hyaluronic acid (HA) is commonly administered as a temporary filler that slowly disappears through enzymatic degradation. Permanent fillers include hydroxy-apatite (Radiesse, Merz, Raleigh, NC) and polymethyl-methacrylate (PMMA), among others.<sup>1-3</sup>

PMMA is a rigid, transparent and colorless, thermoplastic material. Polymerized PMMA microspheres are purified with diameter greater than 20 µm and may be favored as injectable facial fillers for the low cost, accessibility, and potential to achieve lasting results.

Dr Limongi is an Affiliate Professor, Ophthalmology Referral Center at the Hospital das Clínicas, Federal University of Goiás, Goiânia, Goiás, Brazil. Dr Tao is an Affiliate Professor, Gavin Herbert Eye Institute, University of California, Irvine, CA, USA. Dr Borba is an Affiliate Professor, Department of Ophthalmology, University of São Paulo, São Paulo, Brazil. Drs Pereira and Akaishi are Affiliate Professors, and Dr Cruz is Chairman and Professor, Department of Ophthalmology, University of São Paulo - Ribeirão Preto, São Paulo, Brazil. Dr Pimentel is an Affiliate Professor, Department of Ophthalmology, University of Minas Gerais, Belo Horizonte, Minas Gerais, Brazil.

### Corresponding Author:

Dr Roberto Murillo Limongi, Alameda das Rosas n501, Ed. La Vie em Rose, Apt. 2203, Setor Oeste, Goiânia, Goiás 74110-060, Brazil  
E-mail: rmurillousp@hotmail.com



**Figure 1.** (A) A 56-year-old man presented with malar bags and persistent edema 18 months after PMMA injection to the nasojugal and palpebromalar grooves. (B) Postoperative appearance 3 months after debulking of the material and a midface lift.

Complications of fillers may be seen early after injection or late. Weeks to months after injection, massage may be effective for contour irregularity. Inflammation may respond to corticosteroids or other anti-inflammatory treatment. HA can be reversed with enzymatic agents (eg, hyaluronidase) or managed expectantly. Treatment options may be fewer and more complex for the adverse effects of permanent fillers.<sup>4,5</sup>

Contour irregularities, color changes, and nodularity after injection may be more evident in the periocular region due to thin skin and intricate orbitofacial contours.<sup>6</sup> Additionally, mechanical and cicatricial vectors after fillers may induce eyelid malposition. Inflammation and edema are other sequelae that may be difficult to manage in this highly visible zone.<sup>2,7-12</sup>

PMMA injections have been associated with several side effects, however the literature is scarce on periorbital complications and their treatment.<sup>4,5,7-11</sup> The purpose of this paper is to report complications of PMMA injection to the midface and to describe the treatment.

## METHODS

Retrospective chart review, including photographs and histopathology when available, of consecutive patients with PMMA injection complications presenting between January 2012 and October 2014. This study was Institutional Review Board approved at the Federal University of Goiás, Goiânia-Goiás, Brazil. Subjective and objective findings on presentation, and after treatment, were extracted from the charts. The patient and treating surgeon in each case reported the subjective measures.

## RESULTS

The authors identified 11 cases of complications of PMMA injections to the midface. Patient ages ranged from 36 to 62 years (mean, 47 years; median, 44 years). Two (18%) were males and 9 (82%) were females. Adverse effects began

between 2 to 24 months after injection (mean, 7.2 months; median, 6 months). All patients had edema, erythema, and contour irregularity. Seven (64%) patients had nodules, 4 (36%) had yellow, xanthomatous skin changes, and 2 (18%) had eyelid malposition. Histopathology demonstrated a giant cell inflammation in 5 of 6 cases. Corticosteroid injection was tried in 6 cases but was associated with minimal clinical improvement. Surgical debulking of the implanted material was performed in 9 (82%) cases and was effective in improving edema, erythema, and nodularity. Detailed information about each of the 11 cases is available online as Supplementary Material (Figure 1 and Supplementary Figures 1-4). An intraoperative video of one case may also be viewed as Supplementary Material at [www.aestheticsurgeryjournal.com](http://www.aestheticsurgeryjournal.com).

## DISCUSSION

Dermal fillers are increasingly popular and many synthetic polymers have emerged.<sup>2</sup> The midface zone—namely the palpebromalar and nasojugal grooves—offers aesthetic rejuvenation targets for these injectable devices. However, there exist serious risks with injection to the periocular region. Vascular occlusions after facial fillers have been well described and even blindness is a risk. This series demonstrates other sequelae including edema, erythema, fibrosis, eyelid malposition, nodular irregularity, skin discoloration, and granulomatous inflammation. Many of these adverse effects have been previously described and may relate to the type of injectable.

Hyaluronic acid (HA) has been used extensively in the midface. Given in small amounts to the supraperiosteal space, HA has been associated with high patient satisfaction and a low incidence of serious complications.<sup>13-15</sup> Goldberg et al report a 2% incidence of malar edema after injection of HA in the periorbital region; in 244 patients.<sup>15</sup> One major benefit of HA is that it can be easily dissolved with hyaluronidase if there is an undesired or adverse effect. The duration of action averages 6 months with a

residual effect lasting up to 2 to 3 years therefore the primary limitation of HA is short longevity.<sup>15</sup>

For the potentially longer lasting results, many have tried non-biodegradable alloplastic fillers. PMMA has been described as a permanent, biocompatible, non-toxic, non-sensitizing, and non-migratory material.<sup>16</sup> As an injectable dermal filler, PMMA is formulated into micro-spheres and has been given pure or suspended in a collagen solution.

This case series demonstrates that pure PMMA microsphere injection in the periorbital tissues may be associated with various complications and side effects. Chiefly, a granulomatous inflammatory, giant cell reaction with phagocytosis of PMMA particles may occur. Grossly, there was commonly a hardening of the local tissues, edema, erythema, and formation of nodules. The authors describe for the first time, to their knowledge, yellow, xanthomatous discoloration of the skin as an additional side effect of PMMA injection in 4 cases (Supplementary Figures 1-4).

The other side effects of PMMA injection have been previously described. Park et al reported 13 cases of complications following facial filling with PMMA.<sup>10</sup> Complications were classified as nodular masses, inflammation, allergies and skin hypopigmentation. The most affected sides were the lips (46%), followed by periorcular, nasolabial folds, forehead, and cheeks.<sup>4,5,7-11,17-23</sup>

The incidence is uncertain, although the German Injectable Filler Safety Study (IFS) associated PMMA fillers with a high complication rate.<sup>2</sup> Among the 56 patients studied, six (10.7%) had problems after filling with PMMA suspended in collagen (Artecol, Artes Medical Inc., San Diego, CA) including nodules (66.7%) and inflammation (33.3% erythema and swelling 19%). Further research is necessary to clarify the frequency of adverse effects and overall safety and efficacy of PMMA as a facial filler, especially compared to other materials.<sup>1,17-21</sup>

The histopathology data herein may provide some insights to the behavior of PMMA injected to the midface. Five of six specimens revealed a foreign body type chronic granulomatous reaction with giant cells encasing the injected PMMA (Supplementary Figure 1C). These findings corroborate Carpaneda et al, who describe 58 of 63 patients developing a late type inflammatory reaction, 6 months after injection of PMMA throughout the body.<sup>7</sup>

PMMA microsphere size may be an important variable in the pathophysiology. First-generation PMMA fillers produced foreign body granulomas, possibly due to the small particle size (less than 20  $\mu\text{m}$ ). Lamperle et al postulate that larger PMMA microspheres (30 to 50  $\mu\text{m}$ ) may resist phagocytosis.<sup>5</sup> However, Wiest et al demonstrated that a giant cell reaction still occurs with larger PMMA microspheres. However, a confounding variable in the latter study is the actual microsphere size correlated poorly to the manufacturer-specified size.<sup>24</sup> Further investigation may clarify the influence of microsphere size on adverse effects.

The behavior of PMMA injected to the face and the factors that lead to complications may be incompletely understood. However, the above cases and literature suggest PMMA may have some undesirable effects in the eyelids and periocular region.

The study has several limitations. First, it is retrospective in nature and includes a small number of heterogeneous patients and no control. In addition, the data was incomplete in several cases, including one lost to follow-up, and the aesthetic outcome measures were largely subjective.

## CONCLUSION

PMMA injection to the periocular region may be associated with giant cell inflammation, fibrotic nodules, yellowing of the skin, and eyelid malposition. The best treatment for these PMMA injection complications remains uncertain. Corticosteroid injection may have limited efficacy while surgical debulking may be beneficial. Further investigation may clarify the best treatment protocols for side effects of PMMA injections to the midface.

## Supplementary Material

This article contains supplementary material located online at [www.aestheticsurgeryjournal.com](http://www.aestheticsurgeryjournal.com).

## Disclosures

The authors declared no potential conflicts of interest with respect to the research, authorship, and publication of this article.

## Funding

The authors received no financial support for the research, authorship, and publication of this article.

## REFERENCES

1. Broder KW, Cohen SR. An overview of permanent and semipermanent fillers. *Plast Reconstr Surg*. 2006;118 (3 Suppl):7S-14S.
2. Zielke H, Wolber L, Rzany B. Risk profiles of different injectable fillers: results from the Injectable Filler Safety Study (IFS Study). *Dermatol Surg*. 2008;34 (3):326-335; discussion 35.
3. Smith KC. Reversible vs. nonreversible fillers in facial aesthetics: concerns and considerations. *Dermatol Online J*. 2008;14(8):3.
4. Duffy DM. Complications of fillers: overview. *Dermatol Surg*. 2005;31(11 Pt 2):1626-1633.
5. Lemperle G, Rullan PP, Gauthier-Hazan N. Avoiding and treating dermal filler complications. *Plast Reconstr Surg*. 2006;118(3 Suppl):92S-107S.
6. Goldberg RA. The three periorbital hollows: a paradigm for periorbital rejuvenation. *Plast Reconstr Surg*. 2005;116 (6):1796-1804.
7. de Melo Carpaneda E, Carpaneda CA. Adverse results with PMMA fillers. *Aesthetic Plast Surg*. 2012;36(4):955-963.

8. Gelfer A, Carruthers A, Carruthers J, et al. The natural history of polymethylmethacrylate microspheres granulomas. *Dermatol Surg.* 2007;33(5):614-620.
9. Medeiros CC, Cherubini K, Salum FG, de Figueiredo MA. Complications after polymethylmethacrylate (PMMA) injections in the face: a literature review. *Gerodontology.* 2014;31(4):245-250.
10. Park TH, Seo SW, Kim JK, Chang CH. Clinical experience with polymethylmethacrylate microsphere filler complications. *Aesthetic Plast Surg.* 2012;36(2):421-426.
11. Salles AG, Lotierzo PH, Gemperli R, et al. Complications after polymethylmethacrylate injections: report of 32 cases. *Plast Reconstr Surg.* 2008;121(5):1811-1820.
12. Ersek RA, Gregory SR, Salisbury AV. Bioplastique at 6 years: clinical outcome studies. *Plast Reconstr Surg.* 1997;100(6):1570-1574.
13. Rzany B, Cartier H, Kestermont P, et al. Correction of tear troughs and periorbital lines with a range of customized hyaluronic acid fillers. *J Drugs Dermatol.* 2012;11(1 Suppl):s27-s34.
14. Viana GA, Osaki MH, Cariello AJ, Damasceno RW. Treatment of tear trough deformity with hyaluronic acid gel filler [Article in Portuguese]. *Arq Bras Oftalmol.* 2011;74(1):44-47.
15. Goldberg RA, Fiaschetti D. Filling the periorbital hollows with hyaluronic acid gel: initial experience with 244 injections. *Ophthal Plast Reconstr Surg.* 2006;22(5):335-341; discussion 41-43.
16. Carvalho Costa IM, Salaro CP, Costa MC. Polymethylmethacrylate facial implant: a successful personal experience in Brazil for more than 9 years. *Dermatol Surg.* 2009;35(8):1221-1227.
17. Lemperle G, Romano JJ, Busso M. Soft tissue augmentation with artecoll: 10-year history, indications, techniques, and complications. *Dermatol Surg.* 2003;29(6):573-587; discussion 87.
18. Haneke E. Polymethyl methacrylate microspheres in collagen. *Semin Cutan Med Surg.* 2004;23(4):227-232.
19. Bagal A, Dahiya R, Tsai V, Adamson PA. Clinical experience with polymethylmethacrylate microspheres (Artecoll) for soft-tissue augmentation: a retrospective review. *Arch Facial Plast Surg.* 2007;9(4):275-280.
20. Santana KP, Pereira LH, Sabatovich O, Sterodimas A. Foreign-body granulomas caused by polymethylmethacrylate (PMMA) microspheres: successful correction by autologous fat transplantation. *J Plast Reconstr Aesthet Surg.* 2010;63(2):e139-e141.
21. Thaler MP, Ubogy ZI. Artecoll: the Arizona experience and lessons learned. *Dermatol Surg.* 2005;31(11 Pt 2):1566-1574; discussion 75-76.
22. Castro AC, Collares MV, Portinho CP, Dias PC, Pinto Rd. Extensive facial necrosis after infiltration of polymethylmethacrylate. *Braz J Otorhinolaryngol.* 2007;73(6):850.
23. Dadzie OE, Mahalingam M, Parada M, et al. Adverse cutaneous reactions to soft tissue fillers--a review of the histological features. *J Cutan Pathol.* 2008;35(6):536-548.
24. Wiest LG, Stolz W, Schroeder JA. Electron microscopic documentation of late changes in permanent fillers and clinical management of granulomas in affected patients. *Dermatol Surg.* 2009;35(Suppl 2):1681-1688.



The Help You Need  
Is Finally  
Here.

**SMART  
BEAUTY  
GUIDE**  
BROUGHT TO YOU BY  
THE AMERICAN SOCIETY FOR  
AESTHETIC PLASTIC SURGERY

Prospects for Your Practice  
Products Patients Want  
Content You Trust

[www.smartbeautyguide.com](http://www.smartbeautyguide.com)

American Society for Aesthetic Plastic Surgery  
11262 Monarch St., Garden Grove, CA 92841-1441  
800.364.2147 • 562.799.2356