

*Full Length Research Paper*

# Couvelaire uterus: literature review and description of technique for conservative management

Marina Bartolomeu de Carvalho<sup>1</sup>, Rachel Freitas Lopes Nunes<sup>1</sup>, Felipe José de Paiva Rocha<sup>2</sup>, Raiza de Almeida Aguiar<sup>3</sup>, Daniela Guimarães Discacciati<sup>4</sup>, Álvaro Luiz Lage Alves<sup>5</sup> and Mário Dias Correa Junior<sup>6</sup>

<sup>1</sup>Resident in Gynecology and Obstetrics, Clinical Hospital, Federal University of Minas Gerais.

<sup>2</sup>Resident of Gynecology and Obstetrics, Sofia Feldman Hospital.

<sup>3</sup>Gynecology and Obstetrics at the Sofia Feldman Hospital.

<sup>4</sup>Gynecology and Obstetrics, Clinical Hospital, Federal University of Minas Gerais.

<sup>5</sup>Adjunct Professor of Gynecology and Obstetrics, Medical Sciences School of Minas Gerais. Obstetrician at Sofia Feldman Hospital and Clinical Hospital of the Federal University of Minas Gerais. PhD in Gynecology and Obstetrics, Federal University of Minas Gerais.

<sup>6</sup>Associate Professor of Gynecology and Obstetrics, Federal University of Minas Gerais. PhD in Gynecology and Obstetrics, Federal University of Minas Gerais.

## Abstract

Accepted 11 November, 2019

Couvelaire uterus is a severe complication of placental abruption. For decades, the standard treatment for Couvelaire's uterus was hysterectomy. However, the traditional concept that myometrial bleeding interferes with uterine contractility resulting in atony is no longer justified and hysterectomy may not always be necessary. The objective of the present work is to describe a technique used for uterine conservation in two cases of uteroplacental apoplexy.

**Keywords:** Postpartum haemorrhage; uterine artery; maternal mortality; fertility preservation.

## INTRODUCTION

Couvelaire uterus is a severe complication of placental abruption, occurring mainly in those cases where a retroplacental hematoma penetrates the myometrium, separating the muscle bundles and reaching visceral peritoneum (Sherr; Statland, 1985). For decades, standard treatment for Couvelaire's uterus was hysterectomy. However, the traditional concept that myometrial bleeding interferes with uterine contractility resulting in atony is no longer justified and hysterectomy may not always be necessary.

Literature review was carried out and relevant papers were identified through a search in PubMed including the

key words "Couvelaire uterus" and "uteroplacental apoplexy" from 2000 to 2019. Seven papers were identified, with uterine preservation in 2 cases and hysterectomy in 4 cases (Table 1).

The objective of the present work is to describe the technique used for conservation in both presented cases of uteroplacental apoplexy.

### Case 1

A 38 years old patient, with previous cesarean delivery, was admitted on November 19, 2018, with 32 + 1 weeks due to high blood pressure. During hospitalization she received a diagnosis of pre-eclampsia with severe features. She was managed medically with nifedipine

**Table 1.** Literature review of the management of Couvelaire uterus.

Title	Author	Year	Country	Management
Placental abruption leading to hysterectomy.	Sylvester HC & Stringer M	2017	Australia	Hysterectomy – 01 case reported
A 30-Year-Old Female Found to Have a Couvelaire Uterus with Placenta Accreta During Planned Cesarean Delivery.	Uwagbaj ON & Wittlich AC	2017	USA	Hysterectomy – placenta accreta
Couvelaire uterus: bad aspect but normal uterine function	Kehila M& Hmid RB	2016	Tunisia	Conservative Management - 01 case
Couvelaire uterus	Rathi Met al.	2014	India	Conservative Management – 01 case
The homeostatic suture (technique of B-Lynch) may be an alternative to control uterine hemorrhage associated with hypertensive disorders	Korkes et al.	2012	Brazil	Conservative Management - 01 case
<b>Couvelaire uterus</b> in puerperium. A case report	Serrano-Berrones MA et al.	2014	Mexico	Hysterectomy (12 hours after cesarean section)
Uteroplacental apoplexy (Couvelaire syndrome)	Habek D et al.	2008	Austria	Hysterectomy

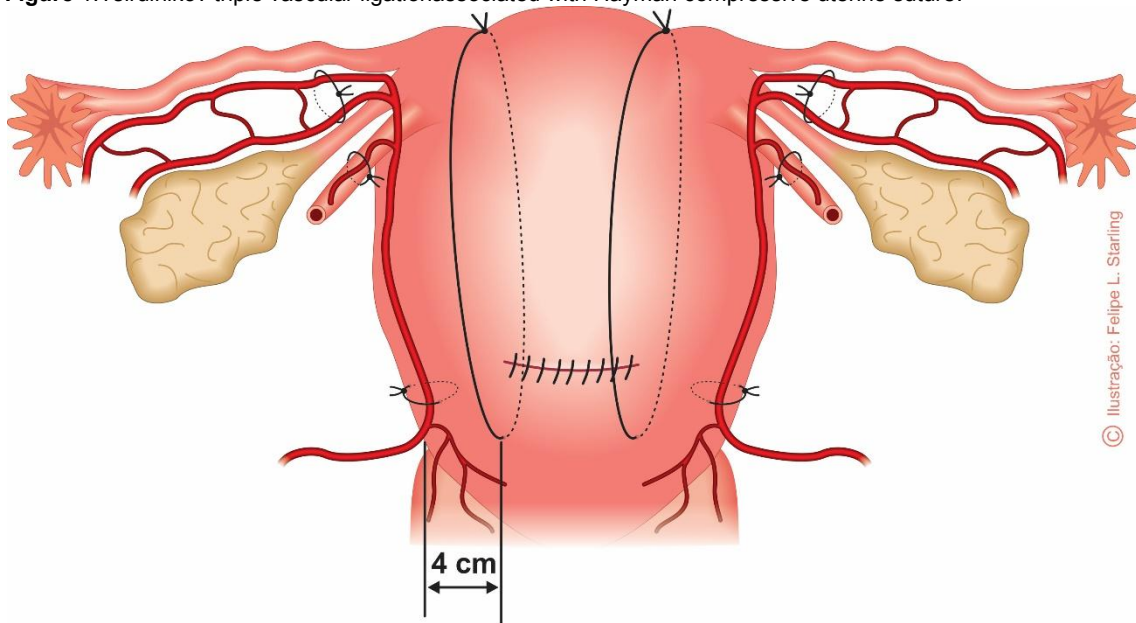
(60mg/day) and methyldopa (1g/day), corticosteroid therapy with betamethasone (24mg) and daily monitoring of fetal vitality with cardiotocography. Ultrasonography showed a fetus in the 65th percentile, normal Doppler, oligohydramnios and fetal biophysical profile of 6. On November 24, she evolved with hypertensive crisis (172X108 mmHg) receiving nifedipine and magnesium sulfate. Subsequently, she presented with placental abruption, evidenced by vaginal bleeding, abdominal pain, uterine hypertonia and fetal bradycardia. She was submitted to emergency cesarean section under spinal anesthesia. Couvelaire uterus and severe uterine atony were diagnosed. There was persistent bleeding despite administration of oxytocin (20IU), misoprostol (1000µg) and tranexamic acid (2g). She was then submitted to Tsurulnikov triple ligation technique. Besides that, two longitudinal loops of uterine compression sutures were applied and double tied to the uterine fundus. The patient was referred to the high-risk gestation unit, hemodynamically stable. In the first 24 hours, she presented with drainage of 1650 ml of blood, hypertensive crisis and laboratory abnormalities compatible with HELLP syndrome (lactate dehydrogenase: 29,790U/L; hemoglobin: 9.5 g/dl; AST: 92 U/L; platelets:39.000/mL<sup>3</sup>). Intravenous hydralazine and transfusion of seven units of platelets were administered. Subsequently, she maintained hemodynamic stability and blood pressure control was obtained with nifedipine, hydralazine and furosemide. On the fourth postoperative day, she was discharged with laboratory improvement (lactate dehydrogenase: 833 U/L; hemoglobin: 7.1g/dl; AST: 36 U/L; platelets: 108.000/mL<sup>3</sup> and creatinine: 0.8mg/dL), prescription of

enalapril, enoxaparin and counseled about outpatient blood pressure control.

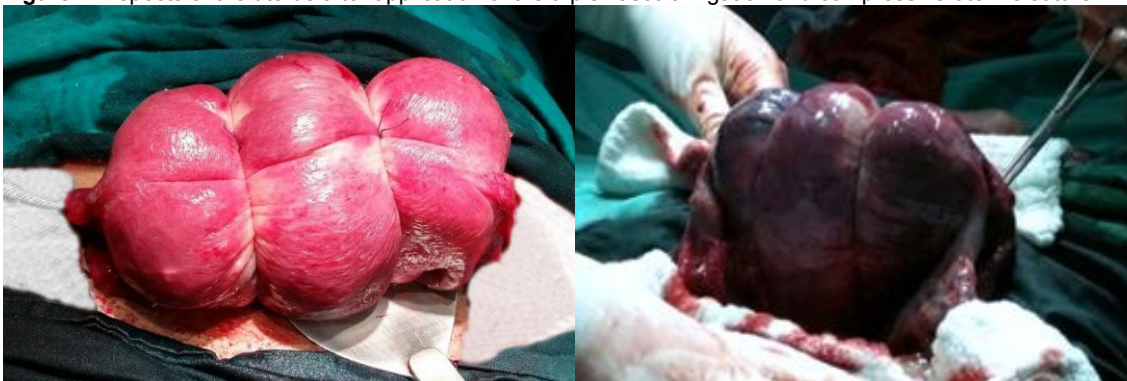## Case 2

A 24 year old primiparous, was admitted on November 23, 2018 with 33 weeks and 5 days gestational age due to placental abruption. She has been previously hospitalized with pre-eclampsia without severe features. She presented severe abdominal pain, uterine hypertonia and the fetal heart rate was not detected. The cervix was closed. Ultrasound examination performed at admission confirmed the absence of fetal heart rate. Emergency cesarean section under spinal anesthesia was performed. The newborn was delivered at cardiorespiratory arrest and there was no success in neonatal resuscitation. After delivery, a placental separation that exceeds 50 percent of maternal surface was identified, accompanied by a large number of clots. Couvelaire uterus associated with important atony was diagnosed. The pharmacological therapy with oxytocin (20IU), tranexamic acid (1g) and misoprostol (800µg) failed to control the bleeding. The patient expressed the desire of fertility preservation. After lower bladder resection, uterine devascularization by Tsurulnikov triple ligation technique was performed. Subsequently, two longitudinal uterine compressive suture loops were applied and doubly tied in the uterine fundus. Intraoperative volume resuscitation with 1500 ml of crystalloids and blood transfusion of 600 ml of concentrated red blood cells were necessary. After the surgery, the patient was referred hemodynamically stable to the intensive care unit, with intravenous use of magnesium sulfate

**Figure 1.** Tsirulnikov triple vascular ligation associated with Hayman compressive uterine suture.



**Figure 2.** Aspects of the uterus after application of the triple vascular ligation and compressive uterine suture.



(2g/h) and oxytocin (4IU/h). She developed hemolysis, and a small subaponeurotic hematoma identified by ultrasonography that was clinically managed. She received new blood transfusion (600 ml of red blood cells), remained four days in the intensive care unit and six more days in ward having evolved with good pressure control and hospital discharge without antihypertensives.

## METHODOLOGY

The technique applied in the two cases described was uterine exteriorization, followed by uterine devascularization and subsequent application of the compressive uterine suture loops. In both compressive

uterine suture and vascular ligation, the suture used were polyglactin and/or polyglecaprone. After performing a bladder flap, the uterine arteries were identified and a simple suture was applied. Subsequently, a single stitch on each of the round ligaments near the uterine horn was placed. After the bilateral ligation, suture was applied to the uterine-ovarian connections in the mesosalpinx, very close to each lateral border of the uterine body. Double surgical suture was performed. In the superior one, the needle was inserted between the uterine tube and its artery, in the anteroposterior direction. The lower passage was done running in the opposite direction near the lower limit of the mesosalpinx, and the knot was tied to the anterior surface. Two compressive

uterine suture loops, according to the Hayman technique, were applied after uterine devascularization. The needle was introduced above the bladder reflex, immediately below the vascular ligation of the ascending branches of the uterine arteries, about 3 cm below the hysterotomy, and 4 cm medially of the border of the uterine segment. The knots were doubly tied to the uterine fundus, with bimanual compression of the uterine body simultaneously performed by one of the assistants.

(Figure 1)

(Figure 2)

## CONCLUSION

In 1966, O'Leary J.L and O'Leary J.A. described the technique of bilateral ligation of the ascending branches of uterine arteries (O'Leary J.L; O'Leary J.A, 1966). Since then, other techniques have been developed, including interruption of vascular supply from other arteries that irrigate the uterus (cervix-uterine, ovarian, ligaments and internal iliac arteries), expanding vascular ligation surgical strategies.

In order to occlude the blood supply from the utero-ovarian connections, bilateral stiches in the mesosalpinx, applied in level of insertions of the uterine tubes and utero-ovarian ligaments, can be performed after ligation of the uterine arteries (Moise JR.; Belfort, 1997; Morel et al., 2011).

Tsirulnikov's technique of triple ligation includes bilateral ligatures of the ascending branches of the uterine arteries, uterine-ovarian connections, and arteries in the round ligament (Tsirulnikov, 1979).

The effect of vascular ligation is readily visible. The uterus becomes pale and bleeding reduces simultaneously. Myometrial contractions may be visible. The uterus may not become firm, but only less flaccid than before, or do not exhibit significant changes at all. The interruption of blood supply leads to eventual uterine contraction, but not myometrial anoxia. Recanalization of vessels will occur, and the blood flow will become normal. The collateral circulation is enough to prevent tissue necrosis. In summary, the techniques have the same effect of the subtotal hysterectomy. Even in a Couvelaire uterus with coagulopathy, the myometrium will contract and the bleeding will cease (O'Leary J.L; O'Leary J.A., 1966, 1974) From the end of the 1990s, several uterine compression sutures have been idealized and applied in the control of postpartum hemorrhage in its various etiologies (Chandrahara and Arulkumaran, 2008). In 2002, Hayman, Arulkumaran and Steer described a uterine suture that promotes uterine compression by the placement of two to four vertical compression sutures from the anterior to posterior uterine wall. (Hayman et al., 2002).

Since then, this technique has been widely disseminated (Penotti et al., 2012; Nanda and Singhal, 2011). Immediate treatment seems to be the most important factor in predicting the efficacy of surgical management of postpartum hemorrhage by vascular ligation and uterine compression sutures. The choice of technique is related to the experience of the obstetrician and the suture used should be always absorbable, preferably poliglecaprone (Morel et al., 2011).

The present case reports demonstrated the efficacy of Tsirulnikov triple vascular ligation associated with Hayman uterine compression sutures in the control of postpartum hemorrhage associated with intense blood infiltrated myometrium. The two cases of Couvelaire uterus occurred in patients presenting with findings compatible with HELLP syndrome, possible candidates for hysterectomy. Despite the scarce number of cases, the results emphasize the need to value surgical procedures that preserve the uterus in the treatment of postpartum hemorrhage and reflect the knowledge and applicability of vascular ligation combined with the uterine compression sutures as an efficient strategy. Apparently, Tsirulnikov's vascular ligation combined with the uterine compression sutures of Hayman are an efficient strategy for hemorrhagic control in Couvelaire uterus associated with coagulopathy, integrating the set of techniques that preserve the uterus in the treatment of postpartum hemorrhage.

## REFERENCES

- Chandrahara E, Arulkumaran S (2008). Surgical aspects of postpartum haemorrhage. *Best. Pract. Res. Clin. Obstet. Gynaecol.*, v. 22, n. 6, p. 1089-102.
- Habek D, Selthofer R, Kulaš T (2008). Uteroplacental apoplexy (Couvelaire syndrome). *Wiener Klinische Wochenschrift*, v. 120, n.3-4, p. 88.
- Hayman RG, Arulkumaran S, Steer R. (2002). Uterine compression sutures: surgical management of postpartum hemorrhage. *Obstet. Gynecol.*v. 99, n. 3, p. 502-6,
- Kehila M, Hmid RB (2016). Couvelaire uterus: bad aspect but normal uterine function. *PAMJ* 2016.doi:10.11604/pamj.25.11.10606.
- Korkes H, Oliveira LG, Watanabe E (2012). The hemostatic suture (technique of B-Lynch) may be an alternative to control uterine hemorrhage associated with hypertensive disorders. *Pregnancy Hypertension J.* 2., 3, p. 252-253,
- Moise JR, Belfort KJ (1997) Damage Control for the Obstetric Patient. In *Surgical Clinics of North America*. v. 77, n. 4, p. 835-52.
- Morel O (2011). Pelvic arterial ligations for severe postpartum hemorrhage. Indications and techniques. *Journal of Visceral Surgery*, v. 148, p. 95-102.
- Nanda S, Singhal SR (2011). Hayman uterine compression stitch for arresting atonic postpartum

- hemorrhage: five years experience. *Tai. J. Obstet. Gynecol.*, v.50, p.179-181.
- O'Leary JL, O'Leary JA (1966). Uterine artery ligation in the control of intractable postpartum hemorrhage. *Am. J. Obstet. Gynecol.*, v. 94, n. 7, p. 920-4.
- O'Leary JL, O'Leary JA (1974). Uterine artery ligation for control of post cesarean section hemorrhage. *Obstet. Gynecol.*, v. 43, n. 6, p. 849-53.
- Penotti M (2012). Compressive suture of the lower uterine segment for the treatment of postpartum hemorrhage due to complete placenta previa: a preliminar study. *Gynecol. Obstet. Invest.*, v.73, p.314-320.
- Rathi M, Rathi SK, Purohit M (2014). Couvelaire uterus. *BMJ Case Rep* doi:10.1136/bcr-2014-204211.
- Serrano-Berrones MÁ, Serrano-Berrones JR, Centeno-Durán G (2014). Útero de Couvelaire en el puerperio. *Relato de un caso clínico. Ginecol. Obstet. Mex.*, v. 82, p. 496-498.
- Sherr G, Statland BE (1985). Abruptio placentae with coagulopathy: a rational basis for management. *Clin Obstet Gynecol*, v. 28, n. 1, p. 15-23.
- Sylvester HC, Stringer M (2017). Placental abruption leading to hysterectomy. *BMJ Case Rep*. doi:10.1136/bcr-2016-218349.
- Tsirulnikov MS (1979). Ligation of the uterine vessels during obstetrical hemorrhages. Immediate and long-term results. *J. Gynecol. Obstet. Biol. Reprod.*, v. 8, p. 751-3.
- Uwagbai ON, Wittich AC (2017). A 30-year-old female found to have a Couvelaire uterus with placenta accreta during planned cesarean delivery. *Mil. Med.*, v. 182, n. 3/4, p. e1877-e1879.