

# Mandibular buccal bifurcation cyst: Case report and literature review

Larissa Porto Lima<sup>1</sup>, Henrique Côrtes Meira<sup>2</sup>, Tânia Mara Pimenta Amaral<sup>2</sup>, Patrícia Carlos Caldeira<sup>2</sup>, Evandro Neves Abdo<sup>2</sup>, Cláudia Borges Brasileiro<sup>2</sup>

## SUMMARY

The present study reports a case of a mandibular buccal bifurcation cyst (MBBC) associated with a partially erupted mandibular first molar. The intraoral examination revealed vestibular swelling in the right mandibular permanent first molar region. Panoramic radiography and cone-beam computed tomography (CBCT) showed a well-delimited radiolucent image involving the roots and part of the crown of the right mandibular permanent first molar with bulging and areas of buccal cortical bone resorption. An incisional biopsy was performed and the diagnosis was MBBC. The lesion was surgically removed by enucleation and curettage. Bone repair was observed seven months after the surgical procedure.

**Keywords:** odontogenic cysts, diagnosis, therapy.

## INTRODUCTION

The mandibular buccal bifurcation cyst (MBBC) is a rare inflammatory odontogenic cyst, first described by Stoneman and Worth in 1983. It predominantly involves the buccal face of the erupting mandibular first (and occasionally the second) molar (1). According to the World Health Organization (WHO)'s latest classification of head and neck tumors, MBBCs, and paradental cysts form a group of inflammatory collateral cysts (2). The etiology of MBBCs is not yet fully understood, but it is believed that they originate from reduced enamel epithelium (3), inflammatory proliferation of epithelial cell rests of Malassez (4) or the superficial mucosa of an erupting tooth (5). Patients may present facial asymmetry resulting from edema in the vicinity of the involved tooth, which may be displaced towards the lingual face of the cortical bone. Radiographically, it presents as a well-delimited, corticated radiolucent lesion, involving the roots and bifurcation region of the associated tooth (6). The histopathologic features resemble those of other inflammatory odontogenic cysts, with non-keratinized squamous epithelial lining, presence of leukocyte exocytosis, and hyperplasia of the connective tissue capsule with chronic inflammation. Thus, the diagnosis should be

defined by an association of clinical, radiographic, and histopathological features (7). Lesion enucleation with preservation of the involved tooth has been the approach indicated to treat MBBC (6).

The goal of the present article is to report a mandibular buccal bifurcation cyst case with clinical, imaging, histopathological, and follow-up documentation and to discuss the etiology, clinical, radiographic, and histopathological aspects and the proposed treatments for this uncommon odontogenic cyst.

## CASE REPORT DESCRIPTION

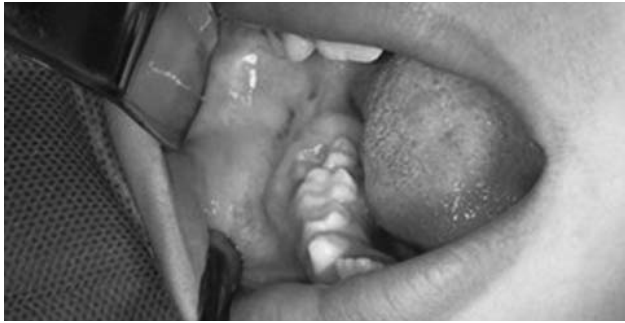A seven-year-old male patient was referred by a dental surgeon to the Clinic of Pathology, Stomatology, and Radiology of the School of Dentistry, Universidade Federal de Minas Gerais (Belo Horizonte, Minas Gerais state, Brazil) to evaluate a "swelling on the right side of the jaw" that had been ongoing for a period of two months. Clinically, an extra-oral, painful on palpation edema was observed in the right region of the mandible. The intra-oral examination revealed a volume increase in the right mandibular permanent first molar region, with no signs of inflammation of the adjacent mucosa (Figure 1). Carious lesions were absent, and the tooth responded positively to the pulp sensitivity test. Furthermore, no mobility was observed.

The panoramic radiograph (Figure 2) showed a well-delimited, corticated, radiolucent image involving the mesial and distal roots and a part of the right mandibular permanent first molar's crown, extending to the completely unerupted second molar crown with ves-

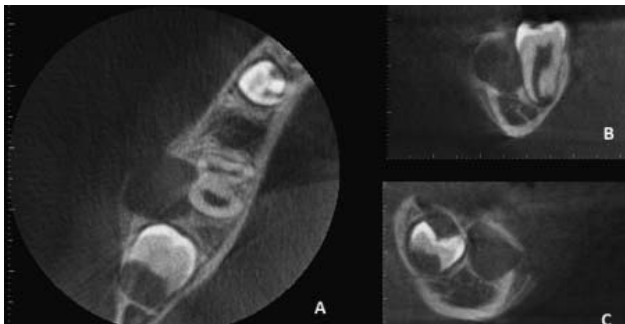
<sup>1</sup>Universidade Federal de Minas Gerais, Belo Horizonte/Minas Gerais, Brazil.

<sup>2</sup>Department of Oral Surgery and Pathology, School of Dentistry, Universidade Federal de Minas Gerais, Belo Horizonte/Minas Gerais, Brazil

Address correspondence to Cláudia Borges Brasileiro, Department of Oral Surgery and Pathology, School of Dentistry, Universidade Federal de Minas Gerais, Av. Antônio Carlos, 6627, Pampulha, 31270-901, Belo Horizonte/MG, Brazil.  
E-mail address: cbbrazilero@gmail.com



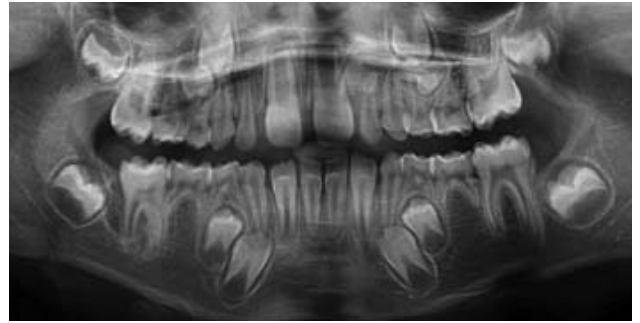**Fig 1.** Intraoral view showing swelling in the vestibular region of the right permanent mandibular first molar, partially erupted, covered by otherwise healthy normal tissue. Red spots are due to anesthesia needle injection.



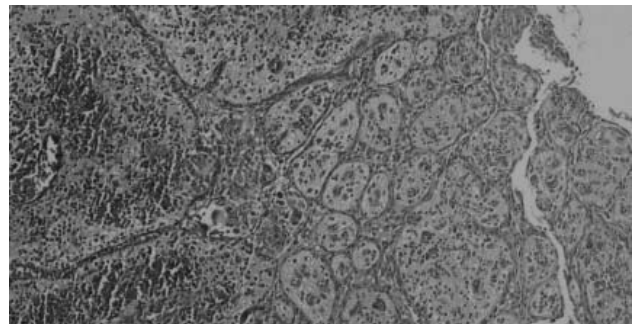
**Fig 3.** Cone beam computed tomography scans in the axial (A), coronal (B), and sagittal (C) views revealing a hypodense image in the vestibular area of the right permanent mandibular first molar, promoting expansion and areas of rupture of the buccal cortical bone with displacement of the tooth towards the lingual cortical bone. spots are due to anesthesia needle injection.

tibular expansion. The right mandibular first molar was partially erupted and exhibited incomplete rhizogenesis. The maxillary right lateral incisor and the maxillary and mandibular second premolars were absent. Cone-beam computed tomography (CBCT) imaging revealed a hypodense, buccal aspect image in the region of the right mandibular permanent first molar, causing bulging and rupture of the buccal cortical bone areas, with displacement of the tooth towards the lingual face of the cortical bone (Figure 3). With the anamnesis, intra- and extra-oral examination, and complementary imaging data, the buccal bifurcation cyst diagnostic hypothesis was raised. The differential diagnosis included other odontogenic cysts.

An incisional biopsy was performed, whose histopathological analysis revealed the presence of cystic cavity fragments lined with non-keratinized squamous epithelium, exhibiting spongiosis, exocytosis, and arcing pattern proliferation, with a cyst capsule composed of fibrous connective tissue, vascularized with intense inflammatory lymphoplasmocytic infiltrate, and a few giant multinuclear cells (Figure 4). The lesion was surgically excised by enucleation under local anesthesia, performed in a surgical block of the School of Dentistry. Histopathological examination revealed aspects similar to those of the biopsy. The clinical, radiographic, and histopathological data allowed the definitive diagnosis of MBBC. The patient remained under periodic observation;



**Fig 2.** Panoramic radiography revealing a radiolucent, well-delimited image involving the mesial and distal roots and part of the crown of the right permanent mandibular first molar.



**Fig 4.** Histopathologic examination showing a cystic lesion lined by non-keratinized stratified epithelium with hyperplasia, exocytosis, and spongiosis. The cystic wall is composed of connective tissue exhibiting dilated capillaries and diffuse infiltration of mononuclear inflammatory cells (hematoxylin-eosin, 100 $\times$ ).

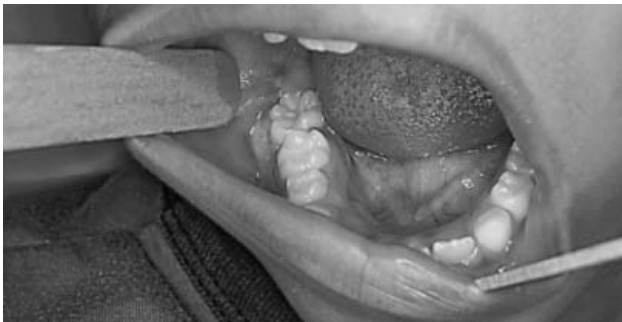the complete eruption of the right mandible permanent first molar (Figure 5) and bone repair of the lesion (Figures 6 and 7) were observed seven months after surgery.

## DISCUSSION

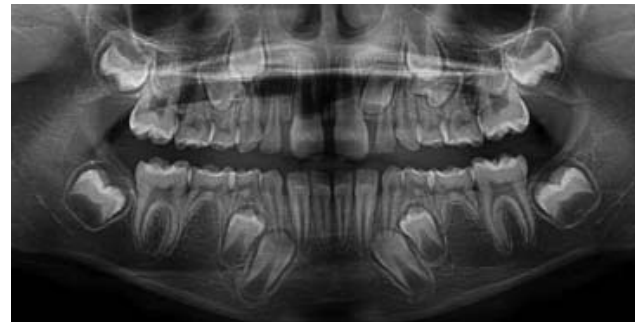
Cysts are defined as epithelium-delimited pathological cavities, filled by a liquid or semi-solid content (8, 9). They are designated odontogenic cysts when associated with the epithelium derived from dental development, i.e., odontogenesis-related epithelial rests (9). The proliferation of non-odontogenic epithelial rests may give rise to so-called non-odontogenic cysts (10).

Several jaw-affecting cystic lesions show similar clinical, radiographic, and histopathological features. The determination of the probable diagnosis may be aided by knowing the prevalence and frequency of odontogenic and non-odontogenic cysts and the most common lesion presentations and distribution sites by age and gender. Odontogenic cysts are the most common destructive bone lesions affecting the jaw; since cysts are asymptomatic, and some exhibit an aggressive behavior, special attention is required from dental surgeons (9, 10).

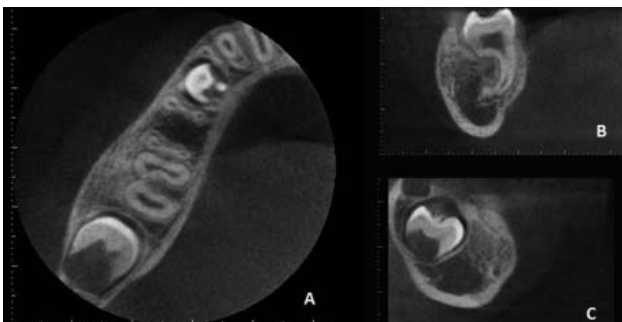Various odontogenic cyst classifications have been put forward due to the wide variety of presentation forms, etiologies, biological behaviors, and treatments. The WHO proposed the first odontogenic cysts and tu-



**Fig 5.** Intraoral view seven months after surgery showing complete eruption of the right permanent mandibular first molar and absence of edema.



**Fig 6.** Panoramic radiography revealing bone repair of the lesion and complete eruption of the right permanent mandibular first molar.



**Fig 7.** Cone beam computed tomography scans of the axial (A), coronal (B), and sagittal (C) sections showing bone neoformation and complete eruption of the tooth.

mors and associated lesions classification in 1971, with several modifications proposed since. According to the most recent WHO classification (2017), inflammatory odontogenic cysts are divided into periapical cysts and inflammatory collateral cysts (Table). Inflammatory collateral cysts appear in partially or recently erupted teeth roots as a result of pericoronal tissue inflammation and are subdivided into MBBCs or paradental cysts (2). The difference between MBBCs and paradental cysts lies in their location. The former are localized in the buccal surfaces of lower vital molars – usually first molars – of

**Table.** Classification of odontogenic and non-odontogenic cysts

Odontogenic cysts of inflammatory origin
Radicular cyst
Inflammatory collateral cyst
Paradental cyst
Mandibular buccal bifurcation cyst
Odontogenic and non-odontogenic developmental cysts
Dentigerous cyst
Odontogenic keratocyst
Lateral periodontal and botryoid odontogenic cyst
Gingival cyst
Glandular odontogenic cyst
Calcifying odontogenic cyst
Orthokeratinized odontogenic cyst
Nasopalatine duct cyst

Adapted from WHO Classification of Head and Neck Tumours, Chapter 8- Odontogenic and maxillofacial bone tumours (2017).

children with mixed dentition and promote a periosteal expansion, with displacement of the involved tooth’s root apex towards the lingual aspect of the cortical bone (1, 8, 11-17). Paradental cysts occur on the buccal, distal, and (rarely) mesial sides of vital, partially erupted third molars, with a history of pericoronitis (4, 13, 18-22). MBBCs account for 0.9 to 4.7% of odontogenic cysts (22). However, their true incidence may be higher than reported, as many cases are misdiagnosed as other cysts or are resolved with the eruption of the tooth itself (14). Paradental cysts correspond to 5% of all odontogenic cysts (22, 23).

In 1964, Thoma (24) described an MBBC-like lesion – the circumferential dentigerous cyst, associated with a partially erupted mandibular second molar. In 1983, Stoneman and Worth described 17 inflammatory odontogenic cyst cases, referred to as mandibular infected buccal cysts or buccal-mandibular bone cysts, which are currently known as MBBCs (1, 6-8, 11-13, 16, 25, 26). The MBBC has received several different names, including infected mandibular buccal bifurcation cyst (1, 2, 12, 16), circumferential dentigerous cyst (1, 6, 17), inflammatory collateral cyst (6, 16, 17), mandibular bifurcation buccal cyst (6, 16, 26), inflammatory cyst (16), lateral periodontal cyst (16), juvenile paradental cyst (1, 2, 26) and paradental inflammatory cyst (2, 16, 17).

The majority of MBBCs present unilaterally but may occur bilaterally (11, 14, 17, 23). The first bilateral MBBC case was reported by Stanback (1970) (26) on the partially erupted mandibular first molars of a 9-year-old child. However, the author considered the case as a dentigerous cyst. Martinez-Conde *et al.* (1995) (11) and Ramos *et al.* (2012) (1) have also described cases of bilateral mandibular buccal bifurcation cysts.

The MBBC etiology is yet not fully understood (22, 23, 28), but it is believed that the inflammatory response occurring in the connective tissue during tooth eruption and rupture of the oral epithelium may stimulate epithelial proliferation and, consequently, cyst formation (1, 12, 18, 22, 23, 28). This theory is supported by the coincidental timings of cyst appearances and dental eruptions (18, 22). Epithelium proliferation may stem from reduced enamel epithelium, junctional epithelium, dental lamina epithelial

rests, or epithelial rests of Malassez (4, 18, 19, 2-23, 29). Enamel pearls may predispose plaque to accumulate in a specific area, facilitating periodontal and bone destruction progressions, which may trigger cyst development (21). The lesion's buccal location can be explained by the fact that the mesiobuccal cusp is the first to erupt in the buccal cavity (1, 7, 8, 11, 12, 14, 21, 26). Factors such as crown shape, fissure pattern, adjacent teeth, and gingival architecture may influence cyst location (21), while predisposing factors such as enamel projections from the bifurcation's cemento-enamel junction and covered by reduced enamel epithelium are also proposed etiological factors (1, 8, 12, 16, 26). This hypothesis seems unlikely, as enamel development projections are absent in most case reports (12, 26). Other hypotheses propose that these cysts are variants of the lateral periodontal cyst (26), that deep periodontal pockets may be the source of inflammation (1), and that the cystic epithelium may be derived from the rests of Serres cells or Malassez cells, either from the dental lamina or the reduced enamel epithelium (8, 12, 14, 16, 26).

Regarding clinical aspects, MBBCs affect children between the ages of four and fourteen, are associated with the first lower molar with pulp vitality (occasionally the lower second molar), with a deep periodontal pocket on the vestibular face, presenting a compromised eruption with tilted crown (1, 6, 12, 15-17, 25, 26). The swelling observed in the vicinity of the affected tooth is often asymptomatic; however, infections with pus drainage and pain may be present (1, 2, 6, 22). The patient in the present case exhibited all of the described characteristics, except purulent secretion.

Radiologically, the MBBC is characterized as a well-defined radiolucent lesion, covering the roots of the involved tooth, whose lamina dura and periodontal ligament are intact, since the lesion's inflammatory component is not endodontic in origin (21). Superficial periosteal reaction can be observed (1, 16, 17, 26). All aspects described herein were observed in the imaging studies performed in the present case except the periosteal reaction. CBCT also showed bulging and tapering, with areas of buccal cortical cleavage in the region of the right mandibular permanent first molar.

All MBBC reports describe similar histopathological features. In the present case, cystic cavity fragments coated by non-keratinized squamous epithelium, and cystic capsule comprising vascularized connective tissue exhibiting a moderate presence of inflammatory mononuclear cell infiltrates. The histopathological features resemble those of periapical and paradental cysts, which are both inflammatory origin lesions (6, 7, 17, 26). Thus, MBBCs should be diagnosed based on the association of clinical, radiographic, surgical, and histological data since its microscopic characteristics are not specific to this lesion (1, 12, 15, 25, 26).

The clinical-radiographic differential diagnosis of this lesion includes periodontal abscess (15), dentigerous cyst (15, 19), dental follicle (15), unicystic ameloblastoma (15), odontogenic keratocyst (15, 22), eosinophilic granuloma (15, 24), central giant cell lesion (25), lateral periodontal cyst (19, 22, 25), idiopathic bone cavity (25), and lateral periapical cyst (22).

Three basic surgical protocols have been reported for BBC cases: marsupialization, enucleation, or initial marsupialization and subsequent enucleation after cyst decompression (28). Stoneman and Worth (1983) reported a procedure involving enucleation and tooth extraction. The authors treated 17 BBC cases but did not address their outcome (12). Martinez-Conde *et al.* (1995) (11) reported a bilateral MBBC case using the same approach. According to the authors, when the formation of the tooth is incomplete and the papilla or lamina dura are involved, it is possible that the dental pulp is also compromised. In such cases, endodontic treatment or exodontia of the involved tooth is indicated. A conservative surgical treatment involving simple enucleation and lesion curettage without extracting the involved tooth has been the most suitable approach for BBC cases (1, 6, 16, 17, 26) due to the importance of maintaining the first and second molars for dental occlusion (6, 8). The largest series of patient cases treated by enucleation was reported by Pompurra *et al.* (1997) (12). Full lesion bone repair was observed in all 44 cases over a two-and-a-half-year postoperative follow-up period. Other more conservative, non-surgical treatments were suggested: periodontal probing and irrigation of the buccal pouch with saline solution and hydrogen peroxide, followed by daily saline irrigation (30). It is thought that periodontal probing induces a small opening in the cyst, resulting in a "micromarsupialization" that allows the cyst to depressurize and regress spontaneously (6, 15-17, 26). Spontaneous lesion regression cases have also been reported; it is speculated that they arise from microtraumas that induce lesion "automarsupialization" (7, 16, 22, 26). Marsupialization has been reported as an MBBC treatment option for small and asymptomatic lesions due to children's great bone tissue repair potential, whereas larger and infected cysts require surgical treatment (22). The disadvantages of this procedure are the long term required for the treatment (16) and the risk of prolonged pathological tissue existence in the body (22). This therapy has not been supported in the literature since it hinders a definitive lesion diagnosis, which may result in an inadequate treatment of a potentially more destructive lesion, such as an odontogenic keratocyst (6). Bone grafting is used as a complementary treatment in some cases, providing temporary stability to the tooth involved in the major bone defect, improving bone regeneration, restoring alveolar bone height, and allowing suitable tissue regeneration (17). The lesion's prognosis is good, and it rarely relapses when treated properly (8, 14). Surgical

lesion removal via enucleation with preservation of the associated tooth was the treatment of choice for the present case. Bone repair, confirmed by imaging exams, and complete eruption of the involved tooth, without relapse, were observed seven months after the surgical procedure.

## CONCLUSION

The MBBC is a rare odontogenic cyst, usually associated with a partially erupted mandibular first molar. MBBC diagnosis is a result of the association between

clinical, radiographic, and histopathological findings. Since the cyst affects children and involves the first molars, a conservative surgical treatment, such as cyst enucleation and preservation of the involved tooth, is the most indicated procedure. Bone repair after surgical treatment is observed after a few months, and relapses are rare.

## CONFLICT OF INTEREST

The authors state no conflict of interest.

## REFERENCES

- Ramos LMA, Vargas PA, Coletta RD, Almeida OP, Lopes MA. Bilateral buccal bifurcation cyst: Case report and literature review. *Head Neck Pathol* 2012;6:455-59.
- El-Naggar AK, Chan JKC, Grandis JR, Takata T, Slootweg PJ. WHO classification of head and neck tumours international agency for research on cancer. Lyon; 2017.
- Craig GT. The paradental cyst. A specific inflammatory odontogenic cyst. *Br Dent J* 1976;141:9-14.
- Ackermann G, Cohen M, Altini M. The paradental cyst: a clinicopathologic study of 50 cases. *Oral Surg Oral Med Oral Pathol* 1987;64:308-12.
- Kramer IRH, Pindborg JJ, Shear M. The WHO histological typing of odontogenic tumours. A commentary on the second edition. *Cancer* 1992;70:2988-94.
- Thikkurissy S, Glazer KM, McNamara KK, Tatakis DN. Buccal bifurcation cyst in a 7-year-old: surgical management and 14-month follow-up. *J Periodontol* 2010;81:442-46.
- Santos SE, Sato FRL, Sawazaki R, Asprino L, Moraes M, Moreira RWF. Mandibular buccal bifurcation cyst: a case report and literature review. *J Dent Child* 2011;78:62-5.
- Carvalho RWF, Avelar RL, Araújo FAC, Antunes AA, Falção PGCB, Andrade ESS. Estudo Retrospectivo de cisto paradentário na cidade do Recife, Pernambuco, Brasil (retrospective study of paradental cyst in the city of Recife, Pernambuco Brazil). *Pesq Bras Odontoped Clin Integr* 2009;9:361-65.
- Pereira JV, Figueirêdo DU, Souza EA, Holmes TSV, Gomes DQC, Cavalcanti AL. Prevalência de cistos e tumores odontogênicos em pacientes atendidos na Fundação Assistencial da Paraíba: estudo retrospectivo (Prevalence of odontogenic cysts and tumors in patients treated at the Paraíba Health Assistance Foundation: a retrospective study). *Arq Odontol* 2010;46:75-81.
- Grossmann SM, Machado VC, Xavier GM, Moura MD, Gomez RS, Aguiar MC, et al. Demographic profile of odontogenic and selected nonodontogenic cysts in a Brazilian population. *Oral Surg Oral Med Oral Pathol Oral Radiol Endod* 2007;104:35-41.
- Martinez-Conde R, Aguirre JM, Pindborg JJ. Paradental cyst of the second molar: Report of a bilateral case. *J Oral Maxillofac Surg* 1995;53:1212-14.
- Pompura JRP, Sándor GKB, Stoneman DW. The buccal bifurcation cyst: A prospective study of treatment outcomes in 44 sites. *Oral Surg Oral Med Oral Pathol Oral Radiol Endod* 1997;83:215-21.
- Silva TA, Batista AC, Camarini ET, Lara VS, Consolaro A. Paradental cyst mimicking a radicular cyst on the adjacent tooth: case report and review of terminology. *J Endod* 2003; 29:73-6.
- Lacaita MG, Capodiferro S, Favia G, Santarelli A, Lo Muzio L. Infected paradental cysts in children: a clinicopathological study of 15 cases. *Br J Oral Maxillofac Surg* 2006;44:112-5.
- Zadik Y, Yitschaky O, Neuman T, Nitzan DW. On the self-resolution nature of the buccal bifurcation cyst. *J Oral Maxillofac Surg* 2011; 69: 282-4.
- Lizio G, Corinaldesi G, Bianchi A, Marchetti C. Successful resolution of juvenile paradental cysts after marsupialization in five consecutive patients. *Aust Dent J* 2011;56:427-32.
- Levarek RE, Wiltz MJ, Kelsch RD, Kraut RA. Surgical management of the buccal bifurcation cyst: bone grafting as a treatment adjunct to enucleation and curettage. *J Oral Maxillofac Surg* 2014;72:1966-73.
- Vedtofte P, Praetorius F. The inflammatory paradental cyst. *Oral Surg Oral Med Oral Pathol* 1989;68:182-8.
- Bsoul SA, Flint DJ, Terezhalmay GT, Moore WS. Paradental cyst (inflammatory collateral, mandibular infected buccal cyst). *Quintessence Int* 2002;33:782-3.
- Castro AL, Bernabé DG, Ranieri AAP, Crivelini MM. Cisto paradental – uma atualização e relato de caso (Paradental cyst – an update and case report). *RFO* 2008;13:61-5.
- Chrcanovic BR, Abreu MHNG, Custódio ALN. Prevalence of enamel pearls in teeth from a human teeth bank. *J Oral Sci* 2010;52:257-60.
- Stepić J, Pejović M, Čolić S. Marsupialization of juvenile paradental cyst: A case report. *Stomatološki glasnik Srbije* 2011;58:239-43
- Borgonovo AE, Reo P, Grossi GB, Maiorana C. Paradental cyst of the first molar: Report of a rare case with bilateral presentation and review of the literature. *J Indian Soc Pedod Prev Dent* 2012;30:343-8.
- Thoma KH. The circumferential dentigerous cyst. *Oral Surg Oral Med Oral Pathol* 1964;18:368-71.
- Camarda AJ, Pham J, Forest D. Mandibular infected buccal cyst: Report of two cases. *J Oral Maxillofac Surg* 1989;47:528-34.
- Corona-Rodriguez J, Torres-Labardini R, Tizcareno-Velasco M, Mora-Rincones O. Bilateral buccal bifurcation cyst: Case report and literature review. *J Oral Maxillofac Surg* 2011;69:1694-96.
- Stanback JS. The management of bilateral cysts of the mandible. *Oral Surg Oral Med Oral Pathol* 1970;30:587-91.
- Borgonovo AE, Rigaldo F, Censi R, Conti G, Re D. Large buccal bifurcation cyst in a child: a case report and literature review. *Eur J Paediatr Dent* 2014;15:237-40.
- Wolf J, Hietanen J. The mandibular infected buccal cyst (paradental cyst). A radiographic and histological study. *Br J Oral Maxillofac Surg* 1990;28:322-5.
- David LA, Sandor GK, Stoneman DW. The buccal bifurcation cyst: in non-surgical treatment an option? *J Can Dent Assoc* 1998; 64:712-6.

Received: 01 03 2018  
Accepted for publishing: 21 06 2019