



Case Report

Jejunal stromal tumor and neurofibromatosis[☆]



Daniela Fonseca Lisboa Kayser ^{a,*}, Lígia Nascimento Figueiredo Amaral^a,
Livia Paulucci Cavalcanti Andrade^b, Fernando Augusto Santos Vasconcelos^{b,c,d},
Luiz Felipe de Campos-Lobato^{b,c,e}, Juliano Alves Figueiredo^{b,c,e}

^a Faculdade da Saúde e Ecologia Humana de Vespasiano, Vespasiano, MG, Brazil

^b Hospital Vila da Serra, Belo Horizonte, MG, Brazil

^c Sociedade Brasileira de Coloproctologia, Rio de Janeiro, RJ, Brazil

^d Faculdade de Ciências Médicas de Minas Gerais (FCMMG), Departamento de Cirurgia, Belo Horizonte, MG, Brazil

^e Universidade Federal de Minas Gerais (UFMG), Faculdade de Medicina, Belo Horizonte, MG, Brazil

ARTICLE INFO

Article history:

Received 20 March 2019

Accepted 8 May 2019

Available online 31 May 2019

Keywords:

Gastrointestinal neoplasms

Gastrointestinal stromal tumors

Small intestine

Type 1 neurofibromatosis

ABSTRACT

Gastrointestinal stromal tumors, although rare, are the most common primary mesenchymal neoplasms of the gastrointestinal tract and originate from the interstitial cells of Cajal. They present slow growth and symptoms such as bleeding, abdominal pain or discomfort, and the presence of an abdominal mass. The most affected organs are the stomach and small intestine. Differential diagnoses for gastrointestinal stromal tumor include adenocarcinoma and small intestine lymphoma, metastasis, and carcinoid tumor. Gastrointestinal stromal tumors have been associated with familial syndromes such as type 1 neurofibromatosis, considered a predisposing factor for tumors in the small intestine. This study aimed to report a case of gastrointestinal stromal tumor in the jejunal region in a patient with type 1 neurofibromatosis, followed-up for two years, who underwent laparoscopic segmental enterectomy and diagnosis determined by histopathology and immunohistochemistry. The diagnosis of small intestine gastrointestinal stromal tumor is challenging because of its low incidence, nonspecific symptoms, relative inaccessibility of the small intestine to conventional endoscopic examination, broad spectrum of radiological appearances, and the fact that the nature of the mass is difficult to determine with imaging examinations of the abdomen alone. Thus, the small intestine gastrointestinal stromal tumor may be erroneously diagnosed as pancreatic, gynecological, or mesenteric tumors. The literature does not present many reports on the association of jejunal gastrointestinal stromal tumor with neurofibromatosis. Understanding the tumoral behavior of small intestine gastrointestinal stromal tumor in this subgroup of patients would allow better follow-up.

© 2019 Sociedade Brasileira de Coloproctologia. Published by Elsevier Editora Ltda. This is an open access article under the CC BY-NC-ND license (<http://creativecommons.org/licenses/by-nc-nd/4.0/>).

[☆] Study conducted at Hospital Vila da Serra, Department of Surgery, Belo Horizonte, MG, Brazil.

* Corresponding author.

E-mail: danielakayser@yahoo.com.br (D.F. Kayser).

<https://doi.org/10.1016/j.jcol.2019.05.006>

2237-9363/© 2019 Sociedade Brasileira de Coloproctologia. Published by Elsevier Editora Ltda. This is an open access article under the CC BY-NC-ND license (<http://creativecommons.org/licenses/by-nc-nd/4.0/>).

Tumor estromal de jejuno e neurofibromatose

R E S U M O

Palavras-chave:

Neoplasias gastrointestinais
Tumores do estroma
gastrointestinal
Intestino delgado
Neurofibromatose tipo 1

Os tumores estromais gastrointestinais, embora raros, são as neoplasias mesenquimais primárias mais comuns do trato gastrointestinal e originam-se das células intersticiais de Cajal. Apresentam crescimento lento e manifestam sintomas como sangramento, dor ou desconforto abdominal e presença de massa abdominal. Os órgãos mais acometidos são estômago e intestino delgado. Os diagnósticos diferenciais para tumores estromais gastrointestinais incluem adenocarcinoma e linfoma de intestino delgado, metástases e tumor carcinoide. Os tumores estromais gastrointestinais têm sido associados a síndromes familiares como a neurofibromatose tipo 1, considerada um fator predisponente para tumores no intestino delgado. O objetivo desse trabalho é relatar um caso de tumor estromal gastrointestinal em região jejunal em paciente portadora de neurofibromatose tipo 1, com 2 anos de seguimento, submetida a enterectomia segmentar laparoscópica e diagnóstico determinados pela histopatologia e imuno-histoquímica. O diagnóstico de tumor estromal gastrointestinal do intestino delgado é desafiador, devido a sua baixa incidência, sintomas inespecíficos, relativa inacessibilidade do intestino delgado ao exame endoscópico convencional, amplo espectro de aparências radiológicas e difícil determinação da natureza da massa apenas com exames de imagens do abdome. Assim, tumor estromal gastrointestinal no intestino delgado podem ser erroneamente diagnosticados como tumores pancreáticos, tumores ginecológicos, ou tumores do mesentério. A descrição científica da associação de tumor estromal gastrointestinal de jejuno com neurofibromatose é incomum. Tais descrições permitem melhor seguimento dos pacientes a partir do momento que se entende o comportamento tumoral do tumor estromal gastrointestinal de intestino delgado nesse subgrupo de pacientes.

© 2019 Sociedade Brasileira de Coloproctologia. Publicado por Elsevier Editora Ltda. Este é um artigo Open Access sob uma licença CC BY-NC-ND (<http://creativecommons.org/licenses/by-nc-nd/4.0/>).

Introduction

Gastrointestinal stromal tumors (GISTs) are slow-growing malignant tumors originating from the interstitial cells of Cajal. Albeit rare, they are common primary mesenchymal neoplasms of the gastrointestinal tract (GI), with an annual incidence between 11 and 14.5 cases per million and accounting for 1–3% of all gastrointestinal neoplasms.¹ It is estimated that approximately 70% of GISTs occur in the stomach, 25% develop in the small intestine, and less than 10% in other parts of the gastrointestinal tract.^{2,3} Most patients (80–88%) are symptomatic at presentation, with the most common symptoms being gastrointestinal bleeding, abdominal pain or discomfort, and presence of abdominal mass.¹ In adults, GISTs have been associated with familial syndromes such as type 1 neurofibromatosis (NF1), considered a predisposing factor for tumors in the small intestine.⁴ In these patients, the prevalence ranges from 5% to 25%; they are clinically asymptomatic and most tumors are detected as incidental findings.^{3,5,6} The authors present the case of a patient with NF1, diagnosed with GIST of the first portion of the jejunum, who underwent laparoscopic treatment.

Case report

A 45-year-old female patient with NF1 presented with mild dyspepsia and persistent epigastric pain for two years. The

endoscopy examination was normal. She had a family history of colorectal cancer (first-degree relative). A colonoscopy was performed until the terminal ileum and indicated no epithelial alteration. Abdominal computed tomography showed a nodular formation, with regular soft tissue density and borders, at the posterior wall of the proximal portion of the jejunum, extending into the intestinal lumen, measuring approximately 2.3 cm × 2.1 cm × 1.7 cm (Fig. 1).

Nuclear magnetic resonance imaging indicated a similar lesion. The patient refused to undergo surgery within the first two years of follow-up. After two years of observation, a new magnetic resonance imaging revealed an increase in size. No signs of dilatation of the main pancreatic duct were observed. There was an absence of collected and/or free peripancreatic fluid. Surgical treatment was indicated, which led to the identification of a proximal jejunal wall lesion (Fig. 2). The patient underwent laparoscopic segmental enterectomy, with a side-to-side jejunum-jejunum anastomosis. No intraoperative complications were observed and the patient was discharged after four days. Histology showed subserous spindle cell neoplasia adhered to the jejunum muscular wall, with low mitotic index. Immunohistochemistry revealed a low-risk GIST, enteric, with positive VIMENTINA, DOG-1, CD-34, and CD-117 (C-kit) immunomodulators in neoplastic cells and S-100 immunomarkers and SMA (1A4) in neoplastic cells. One mitotic figure was observed in 50 HFP. The tumor was staged as T2N0M0, with low mitotic index, stage IA, associated with low rate of disease progression. Six months after the operation,

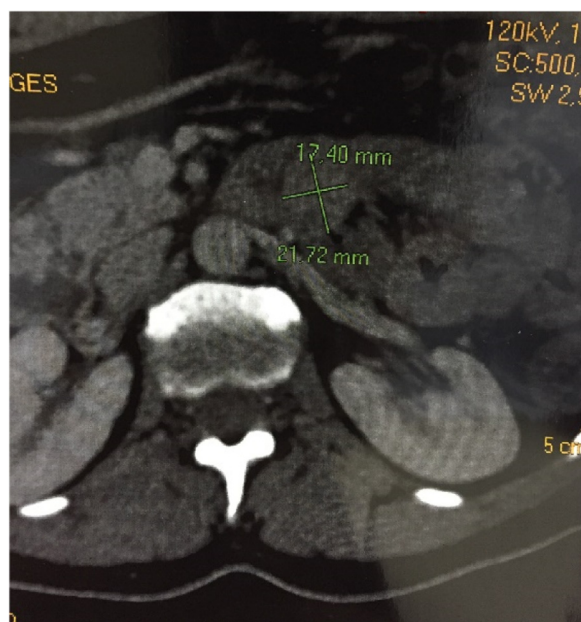


Fig. 1 – Computed tomography of the abdomen showing nodular lesion in the first jejunal portion.

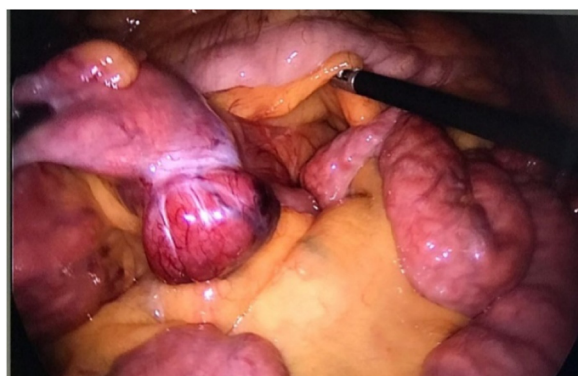

Fig. 2 – Laparoscopic image of the stromal lesion located in the first jejunal portion.

the patient remains in follow-up, showing good progress to date.

Discussion

The diagnosis of small intestine GIST is challenging because of its low incidence, nonspecific symptoms, the relative inaccessibility of the small intestine to conventional endoscopic examination, and its broad spectrum of radiological appearances.¹⁻⁶ Furthermore, it may be difficult to determine the nature of the mass only with imaging tests of the abdomen. Therefore, small intestine GISTs may be erroneously diagnosed as pancreatic tumors, gynecological tumors, or tumors of the mesentery.¹ Clinical imaging diagnosis is based on computed tomography (CT) of the abdomen or upper endoscopy and/or endoscopic ultrasonography and staging is obtained by CT and PET-CT. The characteristic images include the presence of a solid mass with a smooth

outline that is enhanced by the use of intravenous contrast. Differential diagnoses for GIST include small intestine adenocarcinoma, lymphoma, metastasis, and neuroendocrine neoplasia.^{6,7} Between 12% and 18% of patients with small intestine GIST may be asymptomatic, and their tumors are detected incidentally.¹

The definitive diagnosis of GIST is made with tissue histology, supported by immunohistochemistry. Histologic examination is performed by ultrasound-guided biopsy or percutaneous biopsy before surgery. When there is a high clinical and radiological suspicion of GIST, preoperative biopsy is generally not recommended for resectable lesions. However, a preoperative biopsy is preferable to confirm the diagnosis if metastatic disease is suspected, if the drug imatinib is considered, in cases where there is high operative morbidity, or if the diagnosis is unclear.³ CD117, a proto-oncogenic C-Kit protein, is the most important GIST-specific immunohistochemical marker, being positive in more than 95% of the cases.¹ The pathogenic signature of GIST is the presence of activating mutations in the tyrosine kinase receptor (KIT) or the platelet-derived growth factor receptor alpha (PDGFRA); GIST responds to tyrosine kinase inhibitors (TKIs), such as imatinib mesylate.⁶ The use of histopathology and immunohistochemical staining, along with other immunomarkers, including CD34, DOG1, smooth muscle actin (SMA), S100 protein, and desmin, help to distinguish GIST from other primary mesenchymal tumors of the gastrointestinal tract.⁶

Surgical resection with clean margins (R0) is the only potentially curative therapeutic option for non-metastatic GIST. The primary goal is to ensure complete resection of the tumor with free margins.^{1,3} A complete *en bloc* resection is recommended in cases where contiguous organs are involved. Lymphadenectomy is generally not necessary, since GISTs rarely have local or regional lymph node metastases. An exploration of the liver and parietal peritoneum is important for observing possible metastases. Surgery for small intestine GIST may include local excision, resection of the small intestine segment, and pancreatoduodenectomy. Laparoscopic resection is a safe surgical approach. When possible, laparoscopic segmental resection with intra- or extracorporeal anastomosis is the elective approach that achieves comparable oncological results.^{1,3} In a series of cases, laparoscopic removal of tumors up to 85 mm presented low rates of morbidity (10%), mortality (1.3%), and conversion (19%).^{1,3}

Mitotic tumor cell counts (or mitotic index) are one of the factors that predict the prognosis for GIST of the small intestine, as this reflects tumor grade and growth rate.¹ Bucher et al. analyzed the prognosis after the primary resection of GIST and concluded that low-grade GISTs (less than five mitotic figures per mm²) had an excellent prognosis after isolated resection. However, high-grade GISTs (more than five mitotic figures per mm²) were associated with a high risk of recurrence after primary resection. This finding is consistent with a study by Yao et al., who also identified unfavorable prognostic factors such as incomplete resection, histological features of high grade, and tumor size of 5 cm or more ($p < 0.5$). Interestingly, Nilsson et al. estimated a 10% reduced risk of death in gastric GIST patients when compared with those who presented small intestine and colon GIST.² According to the American Joint Committee on Cancer (AJCC), the mitotic index

associated with the TNM criteria allows staging of the cancer in stages I through IV. Stages IA to IIIA have low mitotic index and a rate of disease progression of up to 52%. Stage IIIB has a high mitotic index and is associated with a disease progression rate greater than 73%.^{8–11}

GISTs have been associated with syndromes such as NF1. These cases usually present unique characteristics: patients are younger (mean age 49 years), lesions are multiple in 60% of cases, or develop in multiple sites, are smaller in size with low mitotic activity, have a better prognosis, and occur mainly in the small intestine. These patients do not have GIST-specific mutations; therefore, they show a variable but generally incomplete response to TKI treatment.^{3,5,6}

In the present case, the patient was symptomatic and had some characteristics that have been associated with GIST in patients with neurofibromatosis, such as younger age, small intestine localized lesion, and low mitotic activity. In turn, the lesion was an isolated finding to date, and the histologic assessment presented GIST-specific mutations, contrary to what has been reported in the literature. In the present case, VIMENTINE, DOG-1, CD-34, and CD-117 (C-kit) were positive. A preoperative biopsy was not performed due to the risk of loop perforation and because it was considered a resectable lesion with high clinical suspicion of GIST. In the present case, laparoscopic segmental resection was chosen, as it presents a quick postoperative recovery.

The literature does not present many reports on the association of jejunal GIST with neurofibromatosis. Understanding the tumoral behavior of small intestine GIST in this subgroup of patients allows a better follow-up.

Conflicts of interest

The authors declare no conflicts of interest.

REFERENCES

1. Zhou L, Liao Y, Wu J, Yang J, Zhang H, Wang X, et al. Small bowel gastrointestinal stromal tumor: a retrospective study of 32 cases at a single center and review of the literature. *Ther Clin Risk Manag.* 2018;14:1467–81.
2. Thacoor A. Gastrointestinal stromal tumours: advances in surgical and pharmacological management options. *J Gastrointest Oncol.* 2018;9:573–8.
3. Sanchez-Hidalgo JM, Duran-Martinez M, Molero-Payan R, Rufian-Peña S, Arjona-Sanchez A, Casado-Adam A, et al. Gastrointestinal stromal tumors: a multidisciplinary challenge. *World J Gastroenterol.* 2018;24:1925–41.
4. Machuca MER, Junior AJTA, Junior JAR, Banci O, Oliveira LH, Kagohara OH, et al. Série de casos: tumor de intestino delgado. *J Coloproctol.* 2018;38:48.
5. Garrouche N, Abdallah AB, Arifa N, Hasni I, Cheikh YB, Farhat WB, et al. Spectrum of gastrointestinal lesions of neurofibromatosis type 1: a pictorial review. *Insights Imaging.* 2018;9:661–71.
6. Baheti AD, Shinagare AB, O'Neill AC, Krajewski KM, Hornick JL, George S, et al. MDCT and clinicopathological features of small bowel gastrointestinal stromal tumours in 102 patients: a single institute experience. *Br J Radiol.* 2015;88:1–9.
7. Amaro AN, Franciscatto MC, Magalhães CF, Andreotti T, Nunes JAF, Martinez LF, et al. Relato de caso – GIST de intestino delgado. *J Coloproctol.* 2018;38:29.
8. Bucher P, Egger JF, Gervaz P, Ris F, Weintraub D, Villiger P, et al. An audit of surgical management of gastrointestinal stromal tumours (GIST). *Eur J Surg Oncol.* 2006;32:310–4.
9. Yao KA, Talamonti MS, Langella RL, Schindler NM, Rao S, Small W Jr, et al. Primary gastrointestinal sarcomas: analysis of prognostic factors and results of surgical management. *Surgery.* 2000;128:604–12.
10. Nilsson B, Bümbling P, Meis-Kindblom JM, Odén A, Dortok A, Gustavsson B, et al. Gastrointestinal stromal tumors: the incidence, prevalence, clinical course, and prognostication in the preimatinib mesylate era – a population-based study in western Sweden. *Cancer.* 2005;103:821–9.
11. Amin MB, Edge S, Greene F, Byrd DR, Brookland RK, Washington MK, et al. Gastrointestinal tumor. In: *American Joint Committee on Cancer, editor. AJCC Cancer Staging Manual.* 8th ed. Chicago: Springer; 2017. p. 523–9 [chapter 43].

1. Zhou L, Liao Y, Wu J, Yang J, Zhang H, Wang X, et al. Small bowel gastrointestinal stromal tumor: a retrospective study of