

Indices in dental image exams for bone mineral density evaluation of aromatase inhibitor users

Sâmila Gonçalves BARRA^(a) 
José Alcides Almeida DE ARRUDA^(a) 
Alessandra Figueiredo SOUZA^(a) 
Cláudia Borges BRASILEIRO^(a) 
Bruno Muzzi CAMARGOS^(b) 
Enaldo Melo de LIMA^(b) 
Leandro Napier SOUZA^(a) 
Marina Chaves de OLIVEIRA^(c) 
Soraia MACARI^(d) 
Tarcília Aparecida SILVA^(e) 
Lucas Guimarães ABREU^(e) 
Ricardo Alves MESQUITA^(a) 

^(a)Universidade Federal de Minas Gerais - UFMG, School of Dentistry, Department of Oral Surgery, Pathology and Clinical Dentistry, Belo Horizonte, MG, Brazil.

^(b)Hospital Mater Dei, Bone Densitometry Center, Belo Horizonte, MG, Brazil.

^(c)Universidade Federal de Minas Gerais - UFMG, Nursing School, Department of Nutrition, Belo Horizonte, MG, Brazil.

^(d)Universidade Federal de Minas Gerais - UFMG, School of Dentistry, Department of Restorative Dentistry, Belo Horizonte, MG, Brazil.

^(e)Universidade Federal de Minas Gerais - UFMG, School of Dentistry, Department of Child's and Adolescent's Oral Health, Belo Horizonte, MG, Brazil.

Declaration of Interests: The authors certify that they have no commercial or associative interest that represents a conflict of interest in connection with the manuscript.

Corresponding Author:

Sâmila Gonçalves Barra
E-mail: samilagbarra@gmail.com

<https://doi.org/10.1590/1807-3107bor-2022.vol36.0138>

Submitted: November 22, 2021
Accepted for publication: July 4, 2022
Last revision: July 29, 2022

Abstract: We evaluated the accuracy of radiomorphometric indices (RI) and fractal dimension (FD) for screening bone mineral density (BMD) in postmenopausal patients who had breast cancer and were using aromatase inhibitors (AI). The sample consisted of 40 participants. Digital panoramic radiography (DPR) and cone beam computed tomography (CBCT) were evaluated along with dual-energy X-ray absorptiometry (DXA), which is the gold standard for detecting low BMD. According to the T-scores of DXA, the subjects were assigned into two groups: with normal BMD and with low BMD (osteopenia and osteoporosis). The area under the curve (AUC), sensitivity, and specificity with their respective confidence intervals were determined for DPR and CBCT. For DPR indices, AUC ranged from 52.6 to 75.8%. The mandibular cortical width (MCW) had the highest AUC. For FD, the total trabecular index had the highest sensitivity, while the index anterior to the mental foramen (MF) had the highest specificity. In CBCT, the AUC ranged from 51.8 to 62.0%. The indices with the highest AUC were the molar (M) and anterior (A). The symphysis (S) index had the highest sensitivity and the posterior (P) index had the highest specificity. Sensitivity and specificity were adequate for the computed tomography index (Inferior; CTI [I]). Therefore, MCW, FD of the mandible angle, and total trabecular ROI in DPR and the CTI (I), M, P, and A indices in CBCT proved to be promising tools in distinguishing individuals with low BMD. Cutoff point for these indices could be a useful tool to investigate low BMD in postmenopausal women taking AI.

Keywords: Bone Density; Cone-Beam Computed Tomography; Aromatase Inhibitors.

Introduction

Breast cancer remains an important public health issue. It is estimated that this malignancy has surpassed lung cancer as the first in incidence among all types of cancer in women, with 2,261,419 new cases worldwide in 2020.¹ About one-third of all breast cancer cases are estrogen-dependent,² with deprivation therapy of this hormone being established for management of the disease.³ In the postmenopausal stage, the ovaries have limited or no function, and circulating estrogen levels are reduced. The synthesis of estrogen depends on the aromatization of androgens



(androstenedione and testosterone) into estrogens (estrone and estradiol), which are produced in the adrenal glands, skin, muscle, adipose tissue, liver, and in the breast tumor itself.³

Aromatase inhibitors are the drugs of first choice for the treatment of breast cancer. They act as selective and potent inhibitors of the aromatase enzyme and are classified according to their mechanism of action and the assigned generation (first, second, or third). They are responsible for stopping the conversion of steroidal hormones, thus decreasing circulating estrogen levels.⁴ Residual estrogen levels are important for maintaining bone strength, even after menopause. However, estrogen suppression is detrimental to bone, causing increased bone resorption, decreased bone mineral density (BMD), risk of osteopenia/osteoporosis, bone fragility, and increased risk of fractures, leading to severe complications in affected women.⁵

The best-known exam for analyzing and diagnosing BMD is dual-energy X-ray absorptiometry (DXA), and its results are reported using scores. Nevertheless, the routine use of this tool is unfeasible due to its high cost and lack of access by the general population.⁶ In this context, digital panoramic radiography (DPR) is a dental imaging exam regularly used in clinical practice by oral health providers. Radiomorphometric indices of the lower jaw can be used to detect changes in bone mass, and this can be a useful tool for BMD screening and determining the need for referral of affected individuals for more specific exams and therapy for osteopenia/osteoporosis.⁷⁻¹⁰ With DPR, it is also possible to analyze bone characteristics through mathematical methods, called fractal dimension analysis, which measures the complexity of irregular structures, providing further information that can help in the diagnosis of low BMD due to trabecular bone changes caused by osteoporosis.⁶ In recent years, access to cone beam computed tomography (CBCT) has increased, particularly in dentistry, due to its low cost and reduced radiation dose compared to other imaging exams such as computed tomography.¹¹ CBCT also has critical properties that can be used to measure and visualize radiomorphometric indices.^{11,12}

Previous studies have investigated the usefulness of DPR and CBCT indices in BMD evaluation by comparing their accuracy with that of DXA.^{13,14} In panoramic radiography, there are quantitative indices such as mandibular cortical width (MCW) in the region of the mental foramen.¹⁵ In this exam, the fractal dimension may be used to quantify trabecular bone based on the region of interest (ROI).^{6,16,17} Moreover, qualitative data such as the mandibular cortex index (MCI), which assesses erosions in the mandibular cortex in the region between the mental foramen and the region near the third molar, can also be analyzed.⁷ Regarding CBCT, quantitative index assessments in the mental foramen region have been reported.¹⁸⁻²⁰ Since CBCT images can be taken in several ROI, validation of other areas is important. It is also worth to evaluate the applicability of the exams and indices for the investigation of BMD in specific populations. However, as far as we know, only one study evaluated areas other than the mental foramen region and found that some of these indices can identify postmenopausal women with low BMD.²¹

The properties of mandibular indices and fractal dimension on panoramic radiographs of individuals using aromatase inhibitors have been recently reported in the literature.²² However, data concerning CBCT and its parameters, including its accuracy in diagnosing low BMD, have been poorly documented. Therefore, the purpose of the present accuracy study was to investigate the usefulness of fractal dimension and radiomorphometric indices in DPR and radiomorphometric indices in CBCT for the assessment of BMD in postmenopausal women who had breast cancer and were taking aromatase inhibitors. DXA was the reference standard for accuracy calculation. Considering that both dental images are ancillary tools in the detection of systemic disorders, our alternative hypothesis was that fractal dimension and radiomorphometric indices in DPR and radiomorphometric indices in CBCT would have sufficient accuracy and therefore be useful for detecting low BMD in individuals who undergo therapy with aromatase inhibitors.

Methodology

Study design, period of recruitment and ethical issues

This diagnostic accuracy study included postmenopausal women who had breast cancer, were using aromatase inhibitors (anastrozole, letrozole, or exemestane), and had an indication for DXA in an Outpatient Clinic at Mater Dei Hospital (Belo Horizonte, Brazil) and had been referred to the Oral and Maxillofacial Radiology Service of the School of Dentistry (Federal University of Minas Gerais, Belo Horizonte, Brazil) with a request for imaging exams and dental treatment. The subjects were recruited between 2018 and 2020 and gave written informed consent to participate in the study. Clinicodemographic data were collected from all participants. Exclusion criteria were individuals with a history of other types of cancer, use of other drugs (e.g., tamoxifen), missing data, and image exams with an undefined area of evaluation. At the time, 125 postmenopausal women were undergoing treatment with aromatase inhibitor at the service, but 40 were included and evaluated in this study. The reasons for non-participation in this study were: personal reasons ($n = 47$), limited physical mobility ($n = 16$), no response to the invitation ($n = 15$), resident of a distant city ($n = 6$), or having had bariatric surgery recently ($n = 1$). The study was approved by the Ethics Committee of the two services (#84967518.0000.5149; #84967518.0.3001.5128).

BMD assessment

BMD was assessed by DXA (Hologic Discovery DXA System, Hologic Inc.; Bedford, USA) in all patients recruited for this study according to the recommendations of The International Society for Clinical Densitometry (<https://iscd.org/>). The lumbar spine regions (L1-L4) and the proximal femur (neck and total) were examined. The lowest ROI T-score between the neck of the femur and the total femur was considered for assessment of the proximal femur. The lowest T-score between the lumbar spine and the proximal femur was used for the diagnosis of BMD. The absolute BMD values (g/cm^2) were compared to determine the BMD-monitored differences between the examinations of

each patient. BMD was calculated using the enCORE software (version 14.1; GE Healthcare, Madison, WI, USA). Based on the DXA scores and World Health Organization criteria,²³ the participants were allocated into two groups according to the score obtained: (I) individuals with normal BMD (T-score ≥ -1) and (II) individuals with low BMD, i.e., those with osteopenia ($-1 \leq \text{T-score} < -2.5$) and those with osteoporosis (T-score ≤ -2.5).

Image acquisition

The interval between DXA and DPR/CBCT did not exceed two weeks. DPR and CBCT images were obtained using the same equipment (KODAK 9000C 3D[®] system; Kodak Dental Systems, Carestream Dental LLC, Atlanta, USA), with a tube voltage of 70 kVp, a tube current of 10 mA, and a scan time of 20 s. A trained operator conducted the examinations (S.G.B.). Images were saved in JPG format with a resolution of 264 dpi and evaluated using Adobe Photoshop 7.0 (Adobe Systems; San Jose, USA) with a standardized image increase of 66.6%. CBCT images were obtained using a 200 μm voxel size, 50 mm diameter \times 37 mm height field of view, 72 kVp tube voltage, 10 mA tube current, and 32.40 s scan time. Digital Imaging and Communications in Medicine files were processed using the panoramic cutting curve function in Imaging Studio 3.2[®] (Anne Solutions; São Paulo, SP, Brazil). All images were analyzed on a single LG 15' monitor (LG Electronics; Taubaté, Brazil) at night in a room with dim light.

Radiomorphometric indices

The radiomorphometric indices used to evaluate the individuals in the DPR exams were mandibular cortical index (MCI; Figure 1), with the inferior cortical bone visualized in the region from the mental foramen to the region of the third molar and used for the classification of the MCI as C1, C2, or C3.⁷ The MCW (Figure 2) was measured along a vertical line drawn from the mental foramen on both sides of the cortical bone and the mean value was calculated.¹⁵ Fractal dimension (Figure 3) was determined in three mandible areas in order to assess the trabecular and cortical bone according to previously published methods.^{22,24} A square area of 50 \times 50 pixels was

defined for the trabecular bone, i.e., in the anterior region of the mental foramen and in the angle of the mandible. The anatomical ROI was defined in the area of cortical bone from the mental foramen to the third molar region. Considering that some individuals may have overlap with the hyoid bone image, two anatomical ROI measurements were performed; the first area of the hyoid bone was included and the second was used to remove the overlapping area. The total trabecular fractal dimension was calculated for each patient based on the angle of the mandible and the anterior region of the mental foramen fractal dimension. The list of ImageJ 1.4.3.67 commands (<https://rsbweb.nih.gov/ij>) was used to predetermine ROI selection automatically. The list of commands in the sequential form included set tool ("polygon"), with which a rectangle of each area was drawn with a manual choice of coordinates (x, y) and was evaluated in the DPR and ROI standardization (width = 50, height = 50 in pixels scale). The anatomical ROI of the right and left mandibular cortical bone was selected with the polygonal tool of ImageJ and the images were processed with ImageJ according to a method published elsewhere.¹⁶

The radiomorphometric indices used to evaluate subjects based on CBCT exams (Figure 4) were the posterior (P), molar (M), anterior (A), and symphysis (S), which were measured in cross-sectional images

of the mandible using slice thicknesses of 1 mm with interslice intervals of 1 mm based on a previous study by our group.²¹ Also, the computed tomography mandibular index (CTMI), computed tomography index (inferior) [CTI (I)], and computed tomography index (superior) [CTI (S)] were measured bilaterally in the cross-sectional image, where the mental foramen was better visualized.²⁰ A trained oral and maxillofacial radiologist (S.G.B.) performed the measurements as previously described.²¹

Statistical analysis

Receiver operator characteristic (ROC) analyses were conducted using the MedCalc software (BVBA; Ostend, Flanders, Belgium). The area under the curve (AUC) and the sensitivity and specificity with their confidence intervals were determined for each index. The Youden index was used to determine the value of the index test measuring the indices which, when employed as the cutoff discriminator between the two groups, resulted in the most appropriate combination of sensitivity and specificity.

Results

The mean age of the 40 participants was 61.6 ± 10.5 years (range: 36 to 86 years). The mean time of use of aromatase inhibitors was 27.0 ± 18.8 months (range:

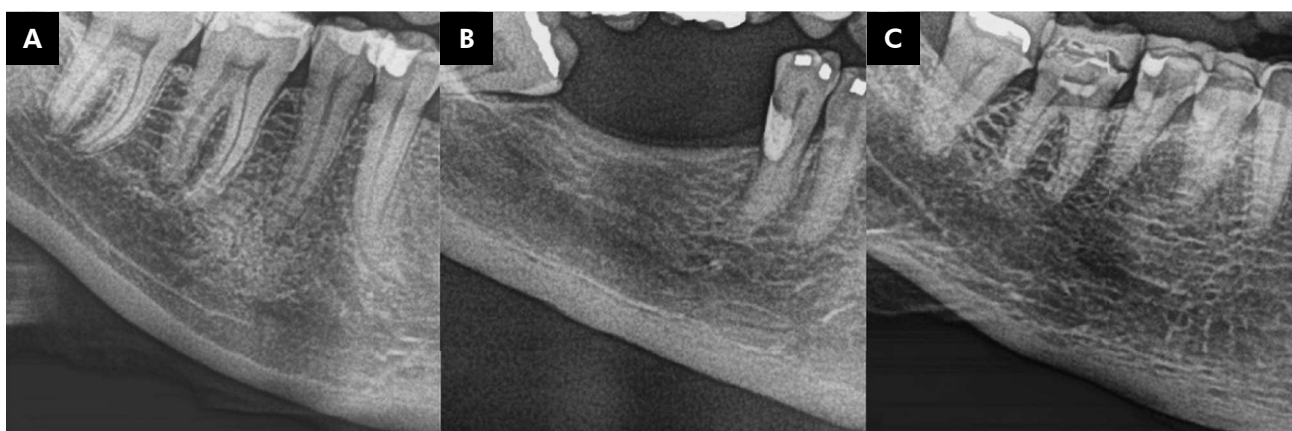


Figure 1. The mandibular cortical index (MCI) is visualized from the region of the mental foramen to the third molar region. **(A)** Mandibular cortical bone without erosion, when the cortical endosteal margin was normal on both sides, is classified as C1. **(B)** Mandibular cortical bone with erosions in the superficial portion, when semilunar defects occur in the endosteal margin on one or both sides, is classified as C2. **(C)** A porous mandibular cortical bone, when more than two-thirds of the height of the mandibular cortex have been affected, is classified as C3.

1 to 72 months), while the mean postmenopausal time was 14.1 ± 9.5 years (range: 1 to 36 years). Regarding tobacco and alcohol habits, 29 (72.5%) individuals never smoked, 1 (2.5%) was a smoker, and 10 (25.0%) gave up smoking, while 21 (52.5%) individuals never drank alcohol, 18 (45.0%) still had the habit of drinking alcohol, and 1 (2.5%) stopped alcohol consumption.

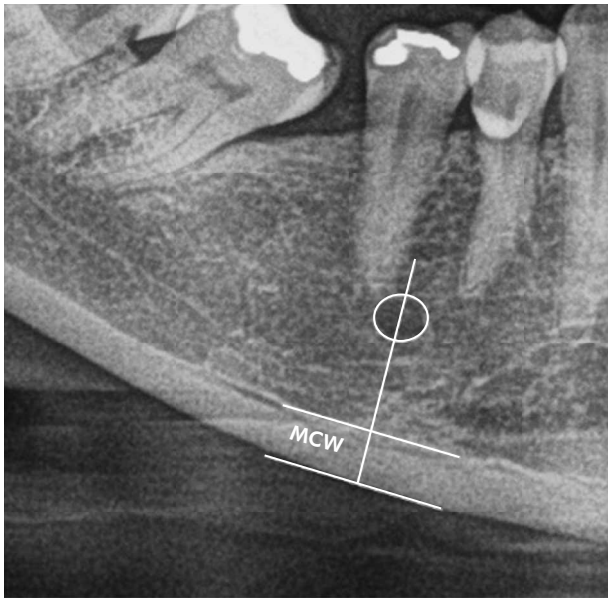


Figure 2. Vertical line measuring the mandibular cortical width (MCW) in the region of the mental foramen.

For MCI in DPR, the AUC was 55.3% (38.7–71.0%). Sensitivity was 100.0% (83.9–100.0%) and specificity was 10.5% (1.3–33.1%). Among the other radiomorphometric indices in DPR, the AUC values ranged from 52.6 to 75.8%. The MCW had the highest AUC. Sensitivity ranged from 38.1 to 100.0% and specificity from 36.8 to 84.2%. In the fractal dimension, the total trabecular index had the highest sensitivity and the anterior to the mental foramen index had the highest specificity. The cutoff points to discriminate between individuals with normal BMD and individuals with low BMD ranged from 1.12 to 3.25 (Table 1; Figure 5).

Regarding the radiomorphometric indices in the CBCT, the AUC values ranged from 51.8 to 62.0%. The index with the highest AUC was the M index. Sensitivity ranged from 9.5 to 85.7%, while specificity ranged from 36.8 to 89.5%. The S index had the highest sensitivity, and the P index had the highest specificity. The cutoff points to discriminate between individuals with normal BMD and individuals with low BMD ranged from 0.24 to 3.80 (Table 2; Figure 6).

Discussion

This study demonstrated that the radiomorphometric indices and fractal dimension proposals of DPR and CBCT might be additional tools for the detection of low BMD in individuals using

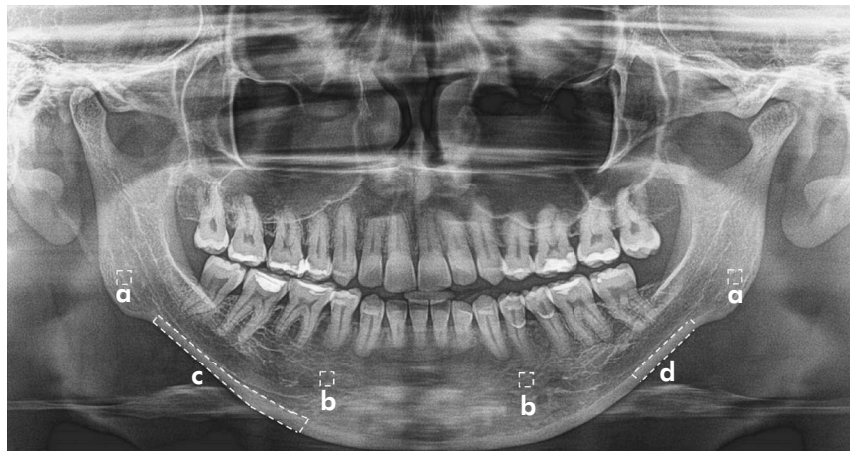


Figure 3. Regions of interest (ROI) used in the fractal dimension. ROI of 50×50 pixels were selected on the trabecular bone of the mandibular angle (A) and anterior regions of the premolars (B). An anatomical ROI was drawn on the mandibular cortical bone with an image overlap of the hyoid bone (C) and without an image overlap of the hyoid bone (D).

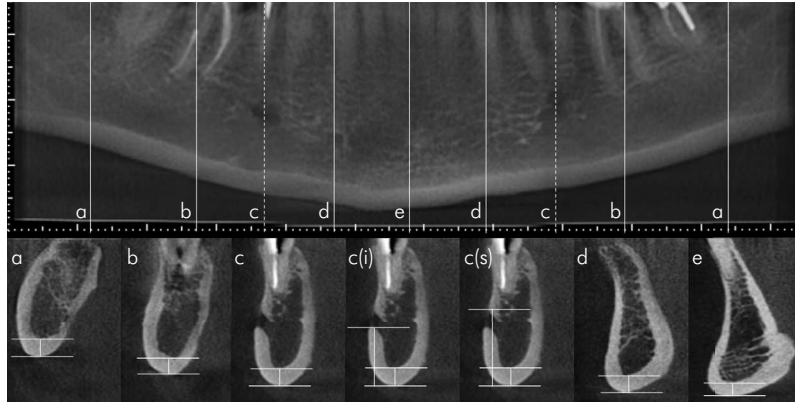


Figure 4. Radiometric indices in cone beam computed tomography. **(A)** Posterior index (P): thickness in millimeters of the inferior cortex of the mandible 25 mm posterior to the cross-sectional image through the mental foramen. **(B)** Molar index (M): thickness in millimeters of the inferior cortex of the mandible 10 mm posterior to the cross-sectional image through the mental foramen. **(C)** Computed tomography mandibular index (CTMI): inferior cortical width of the mandible. **(C I)**. Computed tomography index (inferior) [CTI (I)]: ratio of the inferior cortical width to the distance from the inferior margin of the mental foramen to the inferior border of the mandible. **(C S)**. Computed tomography index (superior) [CTI (S)]: ratio of the inferior cortical width to the distance from the superior margin of the mental foramen to the inferior border of the mandible. **(D)**. Anterior index (A): thickness in millimeters of the inferior cortex of the mandible 10 mm anterior to the cross-sectional image through the mental foramen. **(E)**. Symphysis index (S): thickness in millimeters of the inferior cortex of the mandible equidistant from the centers of the right and left mental foramen.

Table 1. Evaluation of area under the curve (AUC), sensitivity, specificity, Youden index, and cutoff point of the radiomorphometric indices in digital panoramic radiography (DPR).

Mandibular cortical width	Region of interest	AUC (95% CI)	Sensitivity (95% CI)	Specificity (95% CI)	Youden index	Cutoff point
Fractal dimension		75.8 (59.7–87.9)	81.0 (58.1–94.6)	63.2 (38.4–83.7)	0.441	3.25
Mandible angle	50 × 50	67.5 (50.9–81.5)	95.2 (76.2–99.9)	42.1 (20.3–66.5)	0.373	1.26
Region anterior to the mental foramen	50 × 50	59.6 (43.0–74.8)	38.1 (18.1–61.6)	84.2 (60.4–96.6)	0.223	1.12
Total trabecular	50 × 50	70.2 (53.7–83.6)	100.0 (83.9–100.0)	36.8 (16.3–61.6)	0.368	1.21
Cortical bone with hyoid bone	Anatomic	54.4 (37.9–70.2)	76.2 (52.8–91.8)	52.6 (28.9–75.6)	0.288	1.30
Cortical bone without hyoid bone	Anatomic	52.6 (36.3–68.6)	71.4 (47.8–88.7)	52.6 (28.9–75.6)	0.240	1.28

CI: confidence interval.

aromatase inhibitors. Traditionally, monitoring of BMD in breast cancer patients starting aromatase inhibitors has been done with DXA because there is evidence that baseline DXA screening is associated with a reduced risk of fractures.²⁵ Meanwhile, DPR and CBCT are often ordered in daily dental practice and the indices applied to these imaging exams have shown to be cost-effective and reliable tools to identify low BMD in postmenopausal women.^{13,20,21,26-29} In particular, patients using aromatase inhibitors need dental treatment, and non-invasive, easy-to-

use methods may provide helpful information about bone changes and serve as an aid for clinicians in the treatment plan. Although a systematic review revealed that data such as MCI based on panoramic radiography can be used to screen early loss of BMD in women over 30 years, MCI did not appear to be a viable tool for detecting osteopenia/osteoporosis.²⁸ Moreover, former studies have investigated the capability of CBCT images to identify individuals with BMD.^{21,30} Barra et al.²¹ evaluated the radiomorphometric indices of the CBCT to assess

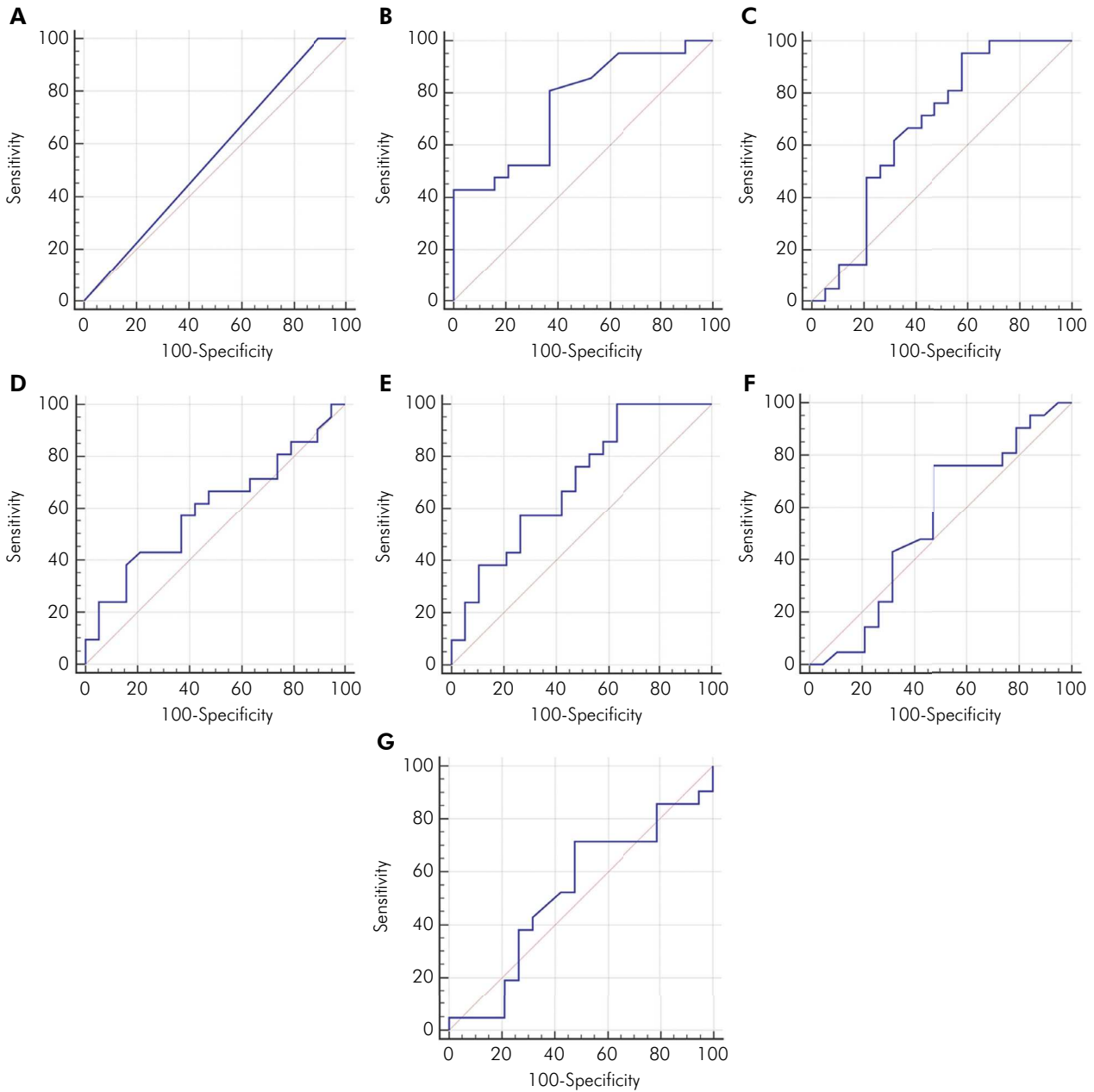


Figure 5. Graphs representing the receiver operator characteristic (ROC) of the mandibular cortical index (A), mandibular cortical width (B), fractal dimension of the mandible angle (C), region anterior to the mental foramen (D), total trabecular bone (E), cortical bone with hyoid bone (F), and cortical bone without hyoid bone (G).

BMD in postmenopausal women and found that the new M and P indices proved useful in identifying low BMD. These studies, however, reported that linear measurements of the inferior mandibular cortex were lower in individuals with osteoporosis, indicating that radiomorphometric indices through CBCT should be a promising tool to identify individuals

with low BMD.^{21,30} Leite et al.³¹ tested the correlations of seven panoramic radiomorphometric indices with the mineral densities of the lumbar spine and hip bone to investigate the accuracy of these recordings in predicting osteoporosis. The most accurate indices for predicting low BMD in women were the mental index and qualitative measures of the MCI and

Table 2. Evaluation of area under the curve (AUC), sensitivity, specificity, Youden index, and cutoff point of the radiomorphometric indices in cone beam computed tomography (CBCT).

Radiomorphometric indices in CBCT	AUC (95%CI)	Sensitivity (95%CI)	Specificity (95%CI)	Youden index	Cutoff point
Posterior (P)	60.4 (43.7–75.5)	33.3 (14.6–57.0)	89.5 (66.9–98.7)	0.228	2.74
Molar (M)	62.0 (45.3–76.9)	38.1 (18.1–61.6)	89.5 (66.9–98.7)	0.275	2.90
Anterior (A)	61.0 (44.3–76.0)	47.6 (25.7–70.2)	73.7 (48.8–90.9)	0.213	3.80
Symphysis (S)	52.8 (36.4–68.7)	85.7 (63.7–97.0)	36.8 (16.3–61.6)	0.225	3.13
CTMI	51.8 (35.4–67.8)	9.5 (1.2–30.4)	68.4 (43.4–87.4)	0.220	4.43
CTI (I)	55.5 (39.0–71.2)	71.4 (47.8–88.7)	47.4 (24.4–71.1)	0.188	0.32
CTI (S)	52.0 (35.7–68.0)	57.1 (34.0–78.2)	57.9 (33.5–79.7)	0.150	0.24

CI: confidence interval; CTI (I): computed tomography index (inferior); CTI (S): computed tomography index (superior); CTMI: computed tomography mandibular index.

the visual estimate of cortical width.³¹ Conversely, diagnostic thresholds for MCW and clinical risk index can be chosen to provide the combination of sensitivity and specificity that is more suitable for detecting osteoporosis in women.³²

Considering the records evaluated in the DPR of the current study, MCW demonstrated the ability to indicate individuals with low BMD. However, MCW higher than 4 mm has been reported in healthy individuals, while women with low BMD had mean values of less than 3 mm.^{8,17,33} Diagnostic accuracy studies investigating radiomorphometric indices show that MCW is one of the indices that better predict women with low BMD.^{31,32} It has been reported that women with MCW <3.15 should be referred for osteoporosis assessment.³¹ In addition, the lowest cutoff of 3 mm permitted an easier identification of the lowest BMD, while the 4.5 mm cutoff permitted the identification of healthy patients.²⁸ Herein, MCW analysis revealed good sensitivity (81.0%), specificity (63.2%), and AUC (75.8%) values, showing that this measure provided better identification of individuals with low BMD. Accordingly, the MCW cutoff point between groups was 3.25 mm.^{8,17,24,28,31} In individuals using aromatase inhibitors, a recent study was a pioneer in the investigation of radiomorphometric indices in this group, but no significant difference was found between control patients and those using medication. It is noteworthy that the mean values found were above 4 mm for both groups, but individuals undergoing treatment had a lower mean value than healthy individuals.²²

Over the last decades, fractal dimension analysis has been widely used in dental images, mainly for bone evaluations.^{29,34,35} Panoramic and periapical radiographs are the most used exams in investigations with fractal dimension purposes. Furthermore, some studies on fractal dimension analysis were also performed with CBCT data, but results can be compromised due to the resolution of CBCT images and data compression.^{18,36,37} In the present study with the evaluation of the fractal dimension in the DPR, we noticed that the mandible angle and the total trabecular ROI showed good sensitivity values (95.2 and 100%, respectively), but low specificity (42.1 and 36.8%, respectively). However, both ROI had acceptable values regarding AUC, *i.e.*, 67.5 and 70.2%, respectively. The cutoff values of the two ROI were very similar (1.26 and 1.21, respectively), showing that both can identify individuals with low BMD. In the study by Göller Bulut et al.²², the angle region showed a significant difference, with the lowest fractal dimension value concerning the other ROI. In contrast, the region anterior to the mental foramen, which had a significant value, did not show the exceptional values needed to identify low BMD. In fact, the ROI relationship can be explained by the different samples and study designs used in the studies. While the study mentioned above²² evaluated healthy patients and patients using aromatase inhibitors, our study evaluated only patients who were taking aromatase inhibitors, separating them into groups according to DXA results. Overall, individuals have normal BMD,

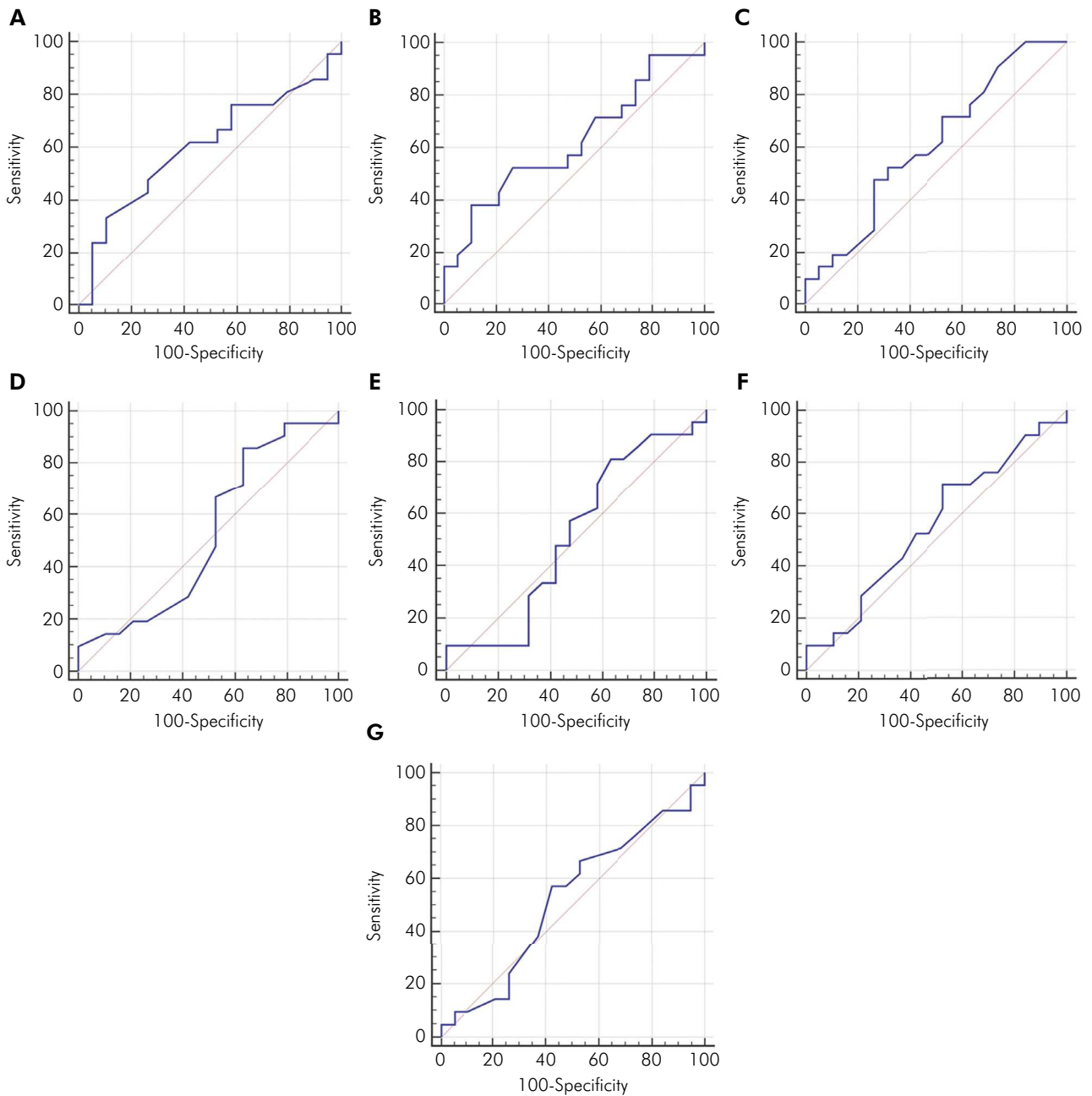


Figure 6. Graphs representing the receiver operator characteristic (ROC) of the posterior (A), molar (B), anterior (C), symphysis (D), computed tomography mandibular index (E), computed tomography index (inferior) (F), and computed tomography index (superior) (G).

even when using AI, and may exhibit changes in trabecular bone. This finding can also be compared to the mean values detected in our study.²²

Previous studies have shown that individuals with changes in BMD have thinner and less dense trabecular bone and, consequently, lower fractal dimension values.^{34,38} In addition, we performed a

diagnostic accuracy test to present the results, which was not done by Göller Bulut et al.²² It is known that in some DPR, the image of the hyoid bone overlaps the mandibular cortical region. Thus, the area of the cortical region was measured with and without hyoid bone image overlap. To investigate the region without the hyoid bone, we analyzed a posterior region of

cortical bone beyond the mental foramen region. Image overlay was evaluated from the mental foramen region to the region near the third molars, as described in the literature²⁴ and the two assessments were found to have very similar specificity and sensitivity. When evaluating the cortical region, however, the results showed that the use of the hyoid bone overlapping area did not seem to interfere with the screening of individuals with low BMD.

In diagnostic accuracy studies investigating radiomorphometric indices, MCI was recommended for screening for low BMD^{6,28} and was shown to have 80% sensitivity and about 60% specificity to identify women with osteopenia.²⁸ Nevertheless, specificity was higher than sensitivity in patients with osteoporosis, and therefore the recommendation of MCI as a screening method for this condition should be made with caution. In our study, MCI was found to have an AUC of 55.3% (38.7–71.0%), similar to other studies that found a higher sensitivity of 100.0% (83.9–100.0%) and a lower specificity of 10.5% (1.3–33.1%).²⁸ In clinical practice, MCI is not indicated for screening patients with low BMD. Possible factors that may have contributed to this outcome include the subjective characteristic of the MCI index, anatomical variability, and limited sample size. In the present study, the small sample size makes generalization of the results unfeasible. Other factors should also be pointed out, including intra- and inter-examiner comparisons to increase the reliability of the method, experience or training of oral and maxillofacial radiologists, and the presence of individuals with low anatomical variability, who did not exhibit alterations in the mandibular cortex.¹³ Conversely, visual analysis of MCI, especially concerning C2 classification, results in lower reproducibility of the findings and may increase observational disagreements.^{19,40} Some studies^{13,40} have shown sufficient consensus, but one report has not.³⁹ In cases of cortical bone classified as C3 in DPR, we believe patients should be referred for medical evaluation due to low BMD.

Accumulating scientific evidence suggests that radiomorphometric indices on CBCT are a promising tool to detect individuals with low BMD.³⁰ Herein, CTI (I) showed the best sensitivity and specificity (71.4 and 47.4%, respectively) and had the best AUC (55.5%),

with a cutoff point of 0.32. Linear measurements of the inferior mandibular cortex showed lower values in individuals with osteoporosis. Nonetheless, a few studies have analyzed radiomorphometric indices through CBCT.^{18–20} For instance, Koh and Kim¹⁸ were the first to assess CBCT as a predictor of low BMD. They evaluated a group of normal women and a group of osteoporotic women and found a significant difference in CTI (I) and CTI (S) between them, but no significant difference in CTMI, although they detected the lowest mean value in the osteoporosis group. Mostafa et al.¹⁹ also evaluated women with a normal densitometric diagnosis and women with osteoporosis and found significant differences in CTMI and CTI. Likewise, Güngör et al.⁴¹ assessed subjects with osteopenia and demonstrated that measurements in the osteoporosis group were lower than those in the osteopenia and normal groups, although there was no difference between the osteopenia and normal groups. Brasileiro et al.²⁰ also evaluated normal women with osteopenia and women with osteoporosis and found no significant difference only in CTI (I) between the normal and osteopenia groups. However, the different classification could explain the discrepancy in the results.

Regarding the additional records of CBCT, only Barra et al.²¹ evaluated CBCT parameters such as P, M, A, and S. The M and P indices proved to be the best to identify individuals with low BMD. The M and P indices showed 75.9% sensitivity and 68.7 and 62.5% specificity, respectively, and the best AUC values (0.740 and 0.693, respectively) with a cutoff point of 2.64 mm for the M index and 2.84 mm for the P index.²¹ In the present study, the M and P indices had greater specificity (89.5% for both) and lower sensitivity (38.1 and 33.3%, respectively) compared to the study mentioned above.²¹ Accordingly, the AUC values were 62.0 and 60.4%, with cutoff points of 2.90 mm for the M index and of 2.74 mm for the P index²¹ but with no contradiction for the A index. In the Barra et al.²¹ study, the A index did not show good values, whereas in our study it had a sensitivity of 47.7% and specificity of 73.7% with an AUC of 61.0% and a cutoff point of 3.80. This discrepancy may be expected due to the difference

in the samples investigated in the two studies, but the eventual application of the A index for BMD assessment is important.

Although the doses used in dental imaging exams are generally low, including in CBCT, compared with multislice CT, radiation dose exposure should be taken into account.⁴² In other words, there are different indications for DPR and CBCT, and affected individuals do not necessarily need both exams concomitantly, but the choice of one of the radiographic exams certainly depends on the dental treatment needs of the patient. Of note, panoramic images have limitations such as overlap, distortion, and magnification of structures. These shortcomings affect the identification of anatomical structures, making it difficult to determine the accuracy of measurements of radiomorphometric indices.⁴³ In contrast, CBCT provides images of anatomic structures without overlap, magnification, or distortion and allows 3-dimensional examination of the craniofacial architecture. CBCT also has the advantage of exposure protocols with a smaller field of view, which can result in a lower radiation dose to patients.⁴³ Nonetheless, the intention here is not to list dental imaging as the first choice for diagnosing BMD in this specific population, but rather to validate these methods as tools for evaluation of BMD. Because both exams in our study revealed similarities in terms of accuracy, decision-making in clinical practice could be focused on the more cost-effective exam.

Taken together, our findings indicate a new perspective concerning BMD parameters based on DPR and CBCT as candidates to screen BMD changes

in postmenopausal women using aromatase inhibitors. Although we recognize that the sample of this study was not large, the authors were careful to investigate a group of individuals with a very specific condition. This group of patients may also use polypharmacy, so other variables associated with the diagnosis of breast cancer may have influenced bone parameters (e.g., bone turnover markers, vitamins, calcium) and should not be ruled out.

Conclusion

Within the limitations of this study, the MCW, fractal dimension of mandible angle and total trabecular ROI in DPR and the CTI (I), M, P, and A indices in CBCT proved to be promising tools in distinguishing individuals with low BMD. Cutoff points for these indices could be a useful tool for clinicians to investigate low BMD in postmenopausal women using aromatase inhibitors, but prospective studies with robust samples should be performed to generalize these results.

Acknowledgements

This study was supported by Coordenação de Aperfeiçoamento de Pessoal de Nível Superior (Capes, Finance Code 001), Brazil. S.G.B. and J.A.A.A. are recipients of fellowships. We also thank Conselho Nacional de Desenvolvimento Científico e Tecnológico (CNPq) (#305493/2018-3; #435644/2018-1; #404710/2018-2; #310797/2019-5; #302157/2017-4) and Fundação de Amparo à Pesquisa do Estado de Minas Gerais (Fapemig, #APQ-03166-17). T.A.S., L.G.A., and R.A.M. are research fellows of CNPq.

References

1. Sung H, Ferlay J, Siegel RL, Laversanne M, Soerjomataram I, Jemal A, et al. Global cancer statistics 2020: GLOBOCAN estimates of incidence and mortality worldwide for 36 cancers in 185 countries. *CA Cancer J Clin.* 2021 May;71(3):209-49. <https://doi.org/10.3322/caac.21660>
2. Buzdar AU, Robertson JF, Eiermann W, Nabholz JM. An overview of the pharmacology and pharmacokinetics of the newer generation aromatase inhibitors anastrozole, letrozole, and exemestane. *Cancer.* 2002 Nov;95(9):2006-16. <https://doi.org/10.1002/cncr.10908>
3. Patani N, Martin LA. Understanding response and resistance to oestrogen deprivation in ER-positive breast cancer. *Mol Cell Endocrinol.* 2014 Jan;382(1):683-94. <https://doi.org/10.1016/j.mce.2013.09.038>
4. Gibson L, Lawrence D, Dawson C, Bliss J. Aromatase inhibitors for treatment of advanced breast cancer in postmenopausal women. *Cochrane Database Syst Rev.* 2009 Oct;2009(4):CD003370. <https://doi.org/10.1002/14651858.CD003370.pub3>

5. Khalid AB, Krum SA. Estrogen receptors alpha and beta in bone. *Bone*. 2016 Jun;87:130-5. <https://doi.org/10.1016/j.bone.2016.03.016>
6. Leite AF, Figueiredo PTS, Caracas H, Sindeaux R, Guimarães AT, Lazarte L, et al. Systematic review with hierarchical clustering analysis for the fractal dimension in assessment of skeletal bone mineral density using dental radiographs. *Oral Radiol*. 2015 Jan;31(1):1-13. <https://doi.org/10.1007/s11282-014-0188-y>
7. Klemetti E, Kolmakov S, Kröger H. Pantomography in assessment of the osteoporosis risk group. *Scand J Dent Res*. 1994 Feb;102(1):68-72. <https://doi.org/10.1111/j.1600-0722.1994.tb01156.x>
8. Sindeaux R, Figueiredo PT, Melo NS, Guimarães AT, Lazarte L, Pereira FB, et al. Fractal dimension and mandibular cortical width in normal and osteoporotic men and women. *Maturitas*. 2014 Feb;77(2):142-8. <https://doi.org/10.1016/j.maturitas.2013.10.011>
9. Camargo AJ, Cortes AR, Aoki EM, Baladi MG, Arita ES, Watanabe PC. Diagnostic performance of fractal dimension and radiomorphometric indices from digital panoramic radiographs for screening low bone mineral density. *Braz J Oral Sci*. 2017 Apr-Jun;15(2):131-6. <https://doi.org/10.20396/bjos.v15i2.8648764>
10. Johanan A, Jonasson G, Lund H, Bernhardsson S, Hagman J, Hange D, et al. Trabecular bone patterns as a fracture risk predictor: a systematic review. *Acta Odontol Scand*. 2021 Oct;79(7):482-91. <https://doi.org/10.1080/00016357.2021.1886322>
11. Gaêta-Araujo H, Alzoubi T, Vasconcelos KF, Orhan K, Pauwels R, Casselman JW, et al. Cone beam computed tomography in dentomaxillofacial radiology: a two-decade overview. *Dentomaxillofac Radiol*. 2020 Dec;49(8):20200145. <https://doi.org/10.1259/dmfr.20200145>
12. Nemtoi A, Czink C, Haba D, Gahleitner A. Cone beam CT: a current overview of devices. *Dentomaxillofac Radiol*. 2013;42(8):20120443. <https://doi.org/10.1259/dmfr.20120443>
13. Kato CN, Tavares NP, Barra SG, Amaral TM, Brasileiro CB, Abreu LG, et al. Digital panoramic radiography and cone-beam CT as ancillary tools to detect low bone mineral density in post-menopausal women. *Dentomaxillofac Radiol*. 2019 Feb;48(2):20180254. <https://doi.org/10.1259/dmfr.20180254>
14. Castro JG, Carvalho BF, Melo NS, Figueiredo PTS, Moreira-Mesquita CR, de Faria Vasconcelos K, et al. A new cone-beam computed tomography-driven index for osteoporosis prediction. *Clin Oral Investig*. 2020 Sep;24(9):3193-202. <https://doi.org/10.1007/s00784-019-03193-4>
15. Ledgerton D, Horner K, Devlin H, Worthington H. Panoramic mandibular index as a radiomorphometric tool: an assessment of precision. *Dentomaxillofac Radiol*. 1997 Mar;26(2):95-100. <https://doi.org/10.1038/sj.dmfr.4600215>
16. White SC, Rudolph DJ. Alterations of the trabecular pattern of the jaws in patients with osteoporosis. *Oral Surg Oral Med Oral Pathol Oral Radiol Endod*. 1999 Nov;88(5):628-35. [https://doi.org/10.1016/S1079-2104\(99\)70097-1](https://doi.org/10.1016/S1079-2104(99)70097-1)
17. Yaşar F, Akgünlü F. The differences in panoramic mandibular indices and fractal dimension between patients with and without spinal osteoporosis. *Dentomaxillofac Radiol*. 2006 Jan;35(1):1-9. <https://doi.org/10.1259/dmfr/97652136>
18. Koh KJ, Kim KA. Utility of the computed tomography indices on cone beam computed tomography images in the diagnosis of osteoporosis in women. *Imaging Sci Dent*. 2011 Sep;41(3):101-6. <https://doi.org/10.5624/isd.2011.41.3.101>
19. Mostafa RA, Arnout EA, Abo El-Fotouh MM. Feasibility of cone beam computed tomography radiomorphometric analysis and fractal dimension in assessment of postmenopausal osteoporosis in correlation with dual X-ray absorptiometry. *Dentomaxillofac Radiol*. 2016;45(7):20160212. <https://doi.org/10.1259/dmfr.20160212>
20. Brasileiro CB, Chalub LL, Abreu MH, Barreiros ID, Amaral TM, Kakehasi AM, et al. Use of cone beam computed tomography in identifying postmenopausal women with osteoporosis. *Arch Osteoporos*. 2017 Dec;12(1):26. <https://doi.org/10.1007/s11657-017-0314-7>
21. Barra SG, Gomes IP, Amaral TM, Brasileiro CB, Abreu LG, Mesquita RA. New mandibular indices in cone beam computed tomography to identify low bone mineral density in postmenopausal women. *Oral Surg Oral Med Oral Pathol Oral Radiol*. 2021 Mar;131(3):347-55. <https://doi.org/10.1016/j.oooo.2020.07.016>
22. Göller Bulut D, Bayrak S, Uyeturk U, Ankarali H. Mandibular indexes and fractal properties on the panoramic radiographs of the patients using aromatase inhibitors. *Br J Radiol*. 2018 Nov;91(1091):20180442. <https://doi.org/10.1259/bjr.20180442>
23. World Health Organization. Scientific Group on the Assessment of Osteoporosis at Primary Health Care Level. Brussels: World Health Organization, 2007.
24. Yasar F, Akgunlu F. Evaluating mandibular cortical index quantitatively. *Eur J Dent*. 2008 Oct;2(4):283-90. <https://doi.org/10.1055/s-0039-1697393>
25. Lu H, Lei X, Zhao H, Elting L, Siricilla M, Ursani MA, et al. Bone mineral density at the time of initiating aromatase inhibitor therapy is associated with decreased fractures in women with breast cancer. *J Bone Miner Res*. 2021 May;36(5):861-71. <https://doi.org/10.1002/jbmr.4250>
26. Nakamoto T, Taguchi A, Ohtsuka M, Suei Y, Fujita M, Tsuda M, et al. A computer-aided diagnosis system to screen for osteoporosis using dental panoramic radiographs. *Dentomaxillofac Radiol*. 2008 Jul;37(5):274-81. <https://doi.org/10.1259/dmfr/68621207>
27. Pachêco-Pereira C, Almeida FT, Chavda S, Major PW, Leite A, Guerra EN. Dental imaging of trabecular bone structure for systemic disorder screening: A systematic review. *Oral Dis*. 2019 May;25(4):1009-26. <https://doi.org/10.1111/odi.12950>

28. Kinalski MA, Boscato N, Damian MF. The accuracy of panoramic radiography as a screening of bone mineral density in women: a systematic review. *Dentomaxillofac Radiol.* 2020 Feb;49(2):20190149. <https://doi.org/10.1259/dmfr.20190149>
29. Franciotti R, Moharrami M, Quaranta A, Bizzoca ME, Piattelli A, Aprile G, et al. Use of fractal analysis in dental images for osteoporosis detection: a systematic review and meta-analysis. *Osteoporos Int.* 2021 Jun;32(6):1041-52. <https://doi.org/10.1007/s00198-021-05852-3>
30. Guerra EN, Almeida FT, Bezerra FV, Figueiredo PT, Silva MA, Canto GDL, et al. Capability of CBCT to identify patients with low bone mineral density: a systematic review. *Dentomaxillofac Radiol.* 2017 Dec;46(8):20160475. <https://doi.org/10.1259/dmfr.20160475>
31. Leite AF, Figueiredo PT, Guia CM, Melo NS, Paula AP. Correlations between seven panoramic radiomorphometric indices and bone mineral density in postmenopausal women. *Oral Surg Oral Med Oral Pathol Oral Radiol Endod.* 2010 Mar;109(3):449-56. <https://doi.org/10.1016/j.tripleo.2009.02.028>
32. Karayianni K, Horner K, Mitsea A, Berkas L, Mastoris M, Jacobs R, et al. Accuracy in osteoporosis diagnosis of a combination of mandibular cortical width measurement on dental panoramic radiographs and a clinical risk index (OSIRIS): the OSTEDENT project. *Bone.* 2007 Jan;40(1):223-9. <https://doi.org/10.1016/j.bone.2006.07.025>
33. Yasar F, Apaydin B, Yilmaz HH. The effects of image compression on quantitative measurements of digital panoramic radiographs. *Med Oral Patol Oral Cir Bucal.* 2012 Nov;17(6):e1074-81. <https://doi.org/10.4317/medoral.17912>
34. Magat G, Ozcan Sener S. Evaluation of trabecular pattern of mandible using fractal dimension, bone area fraction, and gray scale value: comparison of cone-beam computed tomography and panoramic radiography. *Oral Radiol.* 2019 Jan;35(1):35-42. <https://doi.org/10.1007/s11282-018-0316-1>
35. Horner K, Devlin H. The relationship between mandibular bone mineral density and panoramic radiographic measurements. *J Dent.* 1998 May;26(4):337-43. [https://doi.org/10.1016/S0300-5712\(97\)00020-1](https://doi.org/10.1016/S0300-5712(97)00020-1)
36. Taguchi A, Suei Y, Ohtsuka M, Otani K, Tanimoto K, Ohtaki M. Usefulness of panoramic radiography in the diagnosis of postmenopausal osteoporosis in women. Width and morphology of inferior cortex of the mandible. *Dentomaxillofac Radiol.* 1996 Nov;25(5):263-7. <https://doi.org/10.1259/dmfr.25.5.9161180>
37. Jowitt N, MacFarlane T, Devlin H, Klemetti E, Horner K. The reproducibility of the mandibular cortical index. *Dentomaxillofac Radiol.* 1999 May;28(3):141-4. <https://doi.org/10.1038/sj.dmfr.4600427>
38. Nakamoto T, Taguchi A, Ohtsuka M, Suei Y, Fujita M, Tanimoto K, et al. Dental panoramic radiograph as a tool to detect postmenopausal women with low bone mineral density: untrained general dental practitioners' diagnostic performance. *Osteoporos Int.* 2003 Aug;14(8):659-64. <https://doi.org/10.1007/s00198-003-1419-y>
39. Halling A, Persson GR, Berglund J, Johansson O, Renvert S. Comparison between the Klemetti index and heel DXA BMD measurements in the diagnosis of reduced skeletal bone mineral density in the elderly. *Osteoporos Int.* 2005 Aug;16(8):999-1003. <https://doi.org/10.1007/s00198-004-1796-x>
40. Arsan B, Köse TE, Çene E, Özcan İ. Assessment of the trabecular structure of mandibular condyles in patients with temporomandibular disorders using fractal analysis. *Oral Surg Oral Med Oral Pathol Oral Radiol.* 2017 Mar;123(3):382-91. <https://doi.org/10.1016/j.oooo.2016.11.005>
41. Güngör E, Yildirim D, Çevik R. Evaluation of osteoporosis in jaw bones using cone beam CT and dual-energy X-ray absorptiometry. *J Oral Sci.* 2016;58(2):185-94. <https://doi.org/10.2334/josnusd.15-0609>
42. Metsälä E, Henner A, Ekholm M. Quality assurance in digital dental imaging: a systematic review. *Acta Odontol Scand.* 2014 Jul;72(5):362-71. <https://doi.org/10.3109/00016357.2013.840736>
43. Suomalainen A, Pakbaznejad Esmaili E, Robinson S. Dentomaxillofacial imaging with panoramic views and cone beam CT. *Insights Imaging.* 2015 Feb;6(1):1-16. <https://doi.org/10.1007/s13244-014-0379-4>