



ANATOMICAL VARIATIONS OF PORTAL VENOUS SYSTEM: IMPORTANCE IN SURGICAL CLINIC

VARIAÇÕES ANATÔMICAS DO SISTEMA VENOSO PORTA: IMPORTÂNCIA EM CLÍNICA CIRÚRGICA

Edmundo Vieira PRADO NETO¹®, Andy PETROIANU²®

ABSTRACT – BACKGROUND: Knowledge of the portal system and its anatomical variations aids to prevent surgical adverse events. The portal vein is usually made by the confluence of the superior mesenteric and splenic veins, together with their main tributaries, the inferior mesenteric, left gastric, and pancreaticoduodenal veins; however, anatomical variations are frequent. **AIM:** This article presents a literature review regarding previously described anatomical variations of the portal venous system and their frequency. **METHODS:** A systematic review of primary studies was performed in the databases PubMed, SciELO, BIREME, LILACS, Embase, ScienceDirect, and Scopus. Databases were searched for the following key terms: *Anatomy, Portal vein, Mesenteric vein, Formation, Variation, Variant anatomic, Splenomesenteric vein, Splenic vein tributaries, and Confluence.* **RESULTS:** We identified 12 variants of the portal venous bed, representing different unions of the splenic vein, superior mesenteric vein, and inferior mesenteric vein. Thomson classification of the end of 19th century refers to the three most frequent variants, with type I as predominant (M=47%), followed by type III (M=27.8%) and type II (M=18.6%). **CONCLUSION:** Thomson classification of variants is the most well-known, accounting for over 90% of portal venous variant found in clinical practice, inasmuch as the sum of the three junctions are found in over 93% of the patients. Even though rarer and accounting for less than 7% of variants, the other nine reported variations will occasionally be found during many abdominal operations.

HEADINGS: Anatomy. Portal System. Portal Vein. Mesenteric Veins. Splenic Vein

RESUMO – RACIONAL: O conhecimento do sistema porta e de suas variações anatômicas contribui para prevenir acidentes cirúrgicos. Usualmente, a veia porta é formada pela confluência das veias mesentérica superior e esplênica, junto com suas principais tributárias: as veias mesentérica inferior, gástrica esquerda e pancreatoduodenal. Entretanto, variações anatômicas são frequentes. **OBJETIVO:** Este artigo apresenta uma revisão da literatura em relação às variações anatômicas previamente descritas do sistema venoso porta e sua frequência. **MÉTODOS:** Foi realizada revisão sistemática de estudos primários nas bases de dados PubMed, Scielo, BIREME, LILACS, Embase, Science Direct e Scopus. As bases de dados foram pesquisadas pelas seguintes palavras-chave: Anatomia, Veia porta, Veia mesentérica, Formação, Variação, Variante anatômica, Veia esplenomesentérica, Veia esplênica, tributárias e Confluência. **RESULTADOS:** Foram identificadas doze variantes do sistema venoso portal, representando diferentes formações da veia esplênica, veia mesentérica superior e veia mesentérica inferior. A classificação de Thomson, do final do século XIX, refere três variantes mais frequentes, com predomínio do tipo I (M = 47%), seguido do tipo III (M = 27,8%) e do tipo II (M = 18,6%). **CONCLUSÃO:** A classificação de variantes de Thomson é a mais conhecida e responde por mais de 90% da variante venosa portal encontrada na prática clínica, na medida em que a soma das três junções é encontrada em mais de 93% dos pacientes. Embora mais raras e representando menos de 7% das variantes, as outras nove variações relatadas ocasionalmente serão encontradas durante muitas cirurgias abdominais.

DESCRIPTORIOS: Anatomia. Sistema Porta. Veia Porta. Veias Mesentéricas

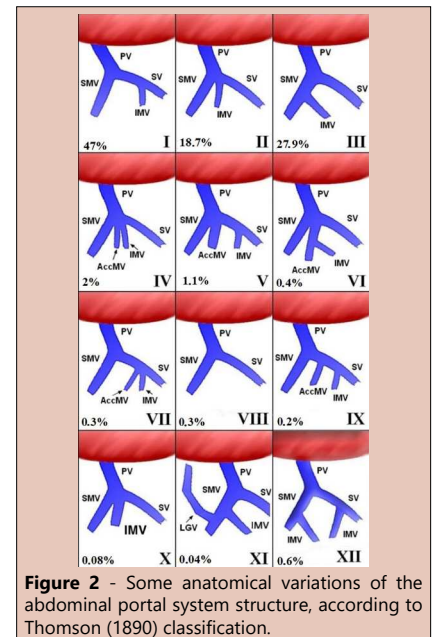


Figure 2 - Some anatomical variations of the abdominal portal system structure, according to Thomson (1890) classification.

Central Message

Although rare, the anatomical variations of portal venous system are possible to be found during operations such as gastroduodenopancreatectomy (Whipple surgery), colectomies, venous bypasses developed due to portal hypertension, hepatectomies and hepatic transplants, as well as in several surgeries on the pancreas and extrahepatic biliary pathways.

Perspectives

A total of 12 anatomical variations of the portal vein have been published. The most common is type I described by Thomson (1890), which consists of the portal vein constitution by the confluence of splenic and superior mesenteric veins, and having the inferior mesenteric and left gastric veins as tributaries.

INTRODUCTION

The abdominal portal vein (PV) starts at the level of the second lumbar vertebra, anterior to the inferior vena cava and posterior to the pancreatic neck. It is composed of the hepatic pedicle, posterior to the hepatic artery and to the common bile duct. The PV is formed by the convergence of superior mesenteric vein (SMV) and splenic vein (SV), measures about 6.5 cm in length and 0.8 cm in diameter on average^{6,9,11}. Its main tributaries are the left gastric vein, which ends at its left border; the pancreaticoduodenal vein, superoposteriorly close to the head of the pancreas^{9,11}; and the veins proceeding from the small and large intestines (SMV and inferior mesenteric vein [IMV]). Other tributaries of the hepatic PV are the cystic veins, proceeding from the gallbladder; pancreatic veins; and right and left gastroepiploic vessels, besides the short gastric veins through the splenic and right gastric veins. The IMV receives blood from the upper part of the rectum, sigmoid, and descending colon^{6,9,11,14}. IMV is predominantly ventral and to the left of the superior mesenteric artery, at the level of the third portion of the duodenum together with the duodenojejunal flexure. The SV is formed by 5–15 venules, originated at the red pulp of the splenic parenchyma, which join together close to the tail of the pancreas. Then, the SV receives as tributaries the short gastric veins in variable number; pancreaticoduodenal veins, also variable in number; and posterior gastric veins, including, eventually, the left gastric vein as well as the IMV. It must be emphasized that the splenogastric vessels are independent and are not among the tributaries of the SV, despite that communicating vessels could occur among them. The SV continues in a dorsal sulcus of the pancreas toward the direction of its head, which can be visible through the lower border of the pancreas. The blood supply of the SV comes from the spleen, larger curvature of the stomach, pancreas, left half of the colon, upper rectum, and retroperitoneum⁶.

The SMV is formed by tributaries of the small intestine, right colon, head of the pancreas, and part of the stomach – through the right gastroepiploic vein. Its position is predominantly ventral and is a short vein that is formed from multiple tributaries as they cross the third portion of the duodenum to the right of the duodenojejunal junction, close to the uncinat process¹¹.

This presentation of the abdominal portal system is the most commonly found; however, there are variations which are the reason of the study among the anatomists for more than a century ago. The first work relating variations of the PV tributaries was published by Thomson et al., which distributed them into three types²⁵:

- **Type I** – IMV as tributary of the SV
- **Type II** – trifurcation in the PV, formed by the union of the SMV, IMV, and SV
- **Type III** – IMV as tributary of the SMV

Despite that there are many anatomical works on the PV, its variations still continue to be described and, sometimes, they are unprecedented. Benninger et al. suggested another tributary of the PV, i.e., the splenomesenteric vein³. Recently, it was also described as modification to Thomson classification¹⁴, with variations of the left gastric vein as direct tributary of the PV or the SV.

The objective of this study was to review the literature related to anatomical variations of the PV system and their frequency, accentuating the morphological knowledge and its surgical applicability, which may aid to prevent surgical adverse events.

METHODS

Systematic review of primary studies was performed with the elaboration based on the *Checklist Preferred Reporting Items*

for Systematic Reviews and Meta-Analyses (PRISMA)¹⁸ in the databases such as PubMed.gov, SciELO, BIREME, LILACS, Embase, ScienceDirect, and Scopus. In the search strategy, the uniterms used were as follows: *Anatomy, Portal vein, Mesenteric vein, Formation, Variation, Variant anatomic, Splenomesenteric vein, Splenic vein tributaries, and Confluence*. The research included MeSH/DeCS/Emtree and Allfiels, excluding animals, *in vitro* studies, studies published in congress annals, secondary studies, and articles with inexplicit method. The included articles were only on humans with studies in cadavers, imaging examination, reports, and case series. Complete articles in English, Spanish, and Portuguese were studied without restriction from the institution of origin nor year of publication (Figure 1).

Only 61 articles were found for reading in their entirety, as well as the title of the articles of their respective bibliographical references. After reading all texts, 19 were selected for this review, 18 with studies discussing (n=20) and 1 study reporting a case not described yet in the literature with a total of 2418 cases in 11 countries. Only one work investigated the PV during the operative act (Table 1). The other articles were not included in this review because they do not discuss the frequency of the variations, do not present anatomical descriptions of the variations found, and do not present statistical data of measuring the frequency of the variations of the portal system.

There are 12 variations described relative to PV system through the union of the SV, SMV, and IMV (Figure 2), such that Thomson (1890) classification refers to the three most frequent, with predominance of type I (28–75%, M=47%), followed by type III (15–40%, M=27.8%) and type II (1.4–28.8%, M=18.6%). The three variations described by Thomson were the only ones described in 16 out of 19 articles. The rest are rarer and make a total of 5.2% of the cases^{2,8,9,10,12,13,15,16,17,20,21,22,25,27}.

Krumm et al.¹⁶ presented six variants that were not previously described: type IV (n=70–2%), in which an accessory mesenteric vein (AccMV) enters at the angle of portal confluence as in Thomson type II; type V (n=28–1.1%), similar to Thomson variant I with two equal SMVs and the introduction of the IMV into the PV; type VI

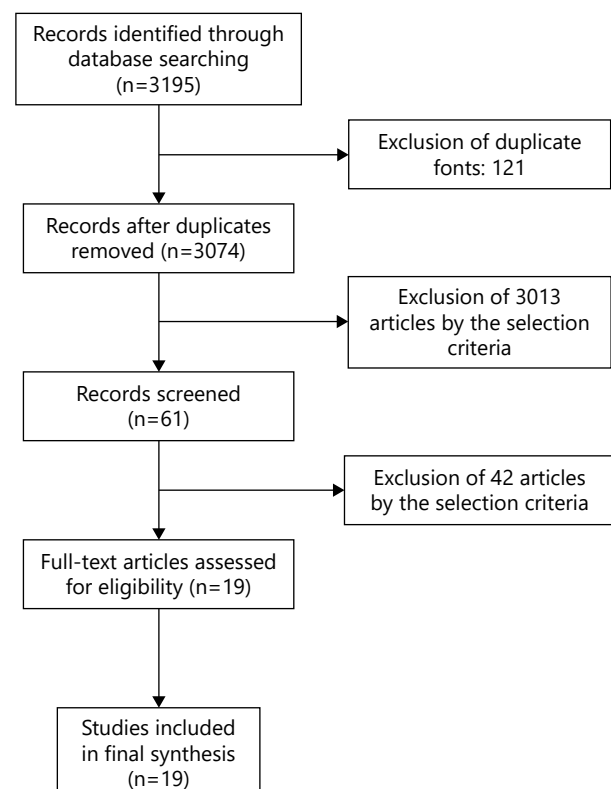


Figure 1 - Flow diagram of literature selected articles related to abdominal portal vein system.

Table 1 - Thomson classification of abdominal portal vein system published in selected literature studies in number of cases (N) and (percentages).

Author, year (country)	N	Method	Type I N (%)	Type II N (%)	Type III N (%)	Others (types IV–XII) N (%)
Thomson et al., 1890 (England)	118	Cadaver dissection	71 (60.1)	8 (6.7)	39 (33)	
Walcker et al., 1922 (the United States)	150	Cadaver dissection	69 (46)	33 (22)	48 (32)	
Gilfillan et al., 1950 (the United States)	54	Cadaver dissection	30 (55.6)	8 (14.8)	16 (29.6)	
Purcell et al., 1951 (the United States)	100	Cadaver dissection	28 (28)	3 (3)	53 (53)	16 (16)
Duques et al., 2000 (Brazil)	56	Cadaver dissection	42 (75)	2 (3.6)	12 (21.4)	
Cabrera et al., 2005 (Cuba)	20	Cadaver dissection	15 (75)	2 (10)	3 (15)	
Ibukuro et al., 1996 (Japan)	43	Angiographies	19 (46)	11 (25)	13 (29)	
Graf et al., 1997 (the United States)	51	Angiographies	28 (55)	9 (17)	14 (27)	
Misuta et al., 2004 (Japan)	27	Angiographies	14 (51.8)	4 (14.8)	9 (33)	
Kim et al., 2007 (South Korea)	205	Angiographies	112 (53)	26 (12)	67 (31)	
Zhang et al., 2007 (China)	191	Angiographies	86 (45)	34 (18)	71 (37)	
Gorantla et al., 2007 (India)	01	Cadaver dissection	00	00	00	01
Sakaguchi et al., 2010 (Japan)	87	Angiographies	63 (68.5)	7 (7.6)	17 (18.5)	
Chaijaroonkhanarak et al., 2010 (Thailand)	65	Cadaver dissection	38 (69.1)	10 (15.38)	17 (30.9)	
Krumm et al., 2011 (Germany)	916	Angiographies	344 (37.6)	266 (28.8)	176 (19.2)	130 (14.2)
Benninger et al., 2013 (the United States + Lebanon)	53	Cadaver dissection	38 (71.1)	5 (9.43)	10 (18.9)	
Khamanarong et al., 2015 (Thailand)	211	Cadaver dissection	117 (56.2)	3 (1.4)	91 (43.7)	
Rault and Bahetee, 2015 (India)	40	Cadaver dissection	12 (30)	19 (47.5)	9 (22.5)	
Kaur et al., 2016 (India)	30	Cadaver dissection	15 (50)	3 (10)	12 (40)	
Total	2418		1141 (47.1)	453 (18.7)	677 (27.9)	147 (6.0)

(n=10–0.4%), similar to variant V, that is, the IMV enters in one of the SMV; type VII (n=8–0.3%), similar to variant I, in which an AccMV enters into the PV at the IMV introduction site; type VIII (n=8–0.3%), in which the IMV is absent; type IX (n=6–0.2%), similar to Thomson type I, with an AccMV which discharges in the PV between the IMV and the confluence of the SMV and PV; and type X (n=2–0.08%), with two equal mesenteric trunks at the confluence of the PV. Gorantla et al.¹⁰ reported type XI, in which the left gastric vein is introduced into the SMV (n=1–0.04%). Purcell et al.²⁰ described 16 cases of type XII, where there were 2 IMVs: a tributary of the SMV and another from SV (0.6%).

According to Krumm et al.¹⁶, the variations can be distributed into three IMV introduction groups as follows:

- **Group 1:** IMV is tributary of SV (variants I, V, VII, and IX).
- **Group 2:** IMV is tributary of SMV (variants III, VI, and XI).
- **Group 3:** It does not fit into group 1 or 2 (variants II, IV, VIII, and X).

Variant XII is an exception because there are two IMVs, which can be included in groups 1 and 2.

DISCUSSION

Thomson variants are the most well known in the surgical practice, inasmuch as the sum of the three junctions are

found in over 90% of the patients. Less than 7% of the cases form the set of other nine variations. Even though rare, these variations are possible to be found during operations such as gastroduodenopancreatectomy (Whipple surgery)^{17,24}, colectomies²⁸, venous bypasses due to portal hypertension (PH)^{5,19}, hepatectomies¹⁹ and liver transplants²⁶, as well as in diverse operations on the pancreas and extrahepatic biliary pathways.

In minimally invasive surgeries, and, most recently, in those performed with the aid of remotely guided robotic devices, perfect knowledge of the anatomical structures and their variations became indispensable in abdominal operations, mainly those who have visceral venous times, all pertaining to the portal system²⁸. Variations in the vascular architecture are the common causes of operative accidents with consequent increasing in surgical time and of the postoperative hospitalization period²⁷.

Portal hypertension is one of the diseases with multiple complications, including cirrhosis, schistosomiasis, retroperitoneal and biliopancreatic tumors, as well as adjacent arterial aneurysms and right heart failure^{4,5,19}. With the increase in pressure, the PV system is reorganized, with the increase in caliber of the veins, such as PV (>13 mm), SMV, and SV (>10 mm), associated with splenomegaly^{5,19}.

The anatomy of the portal system is also important in portal thrombosis (PT)²⁶. The disease is classified into four types in accordance with the stricken venous system and clinical manifestations as follows: type I: asymptomatic

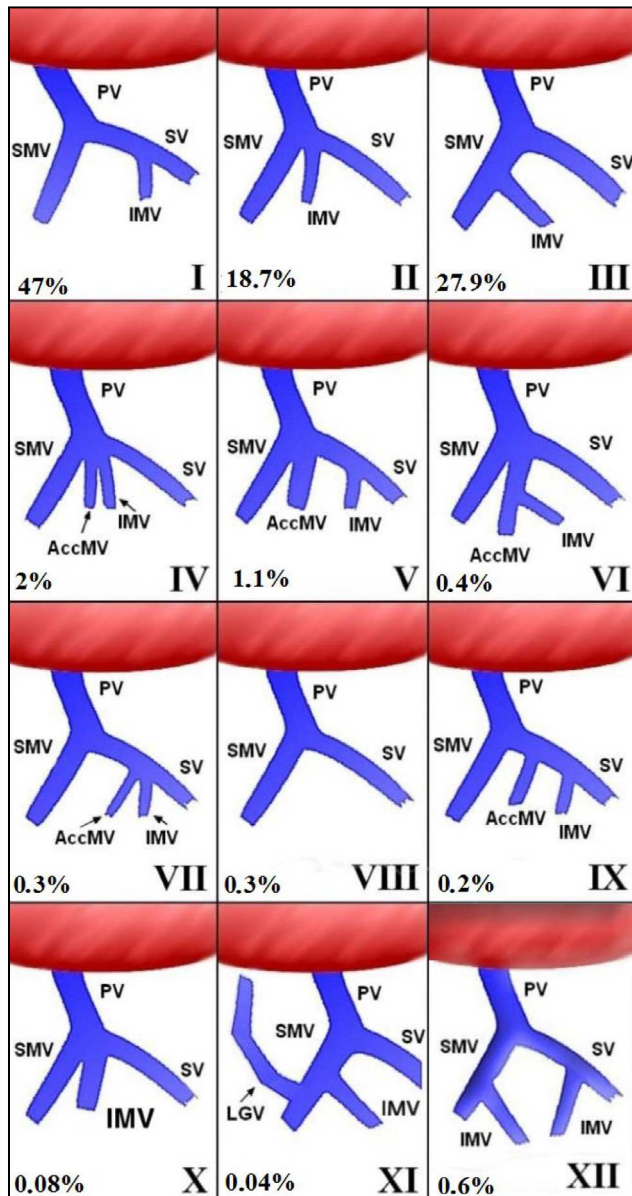


Figure 2 - Some anatomical variations of the abdominal portal system structure, according to Thomson (1890) classification²³. Type I: IMV as a tributary of the SV; type II: three veins constitute the portal vein, i.e. SMV, IMV, and SV; type III: IMV as a tributary of the SMV; type IV: AccMV at the angle of portal confluence; type V: two SMVs and the IMV constitute the PV; type VI: IMV is tributary of the SMV; type VII: AccMV is tributary of the PV together with the IMV; type VIII: absence of IMV; type IX: AccMV as tributary of the PV; type X: two SMVs constitute the PV; type XI: LGV as tributary of the SMV; type XII: two IMVs, one a tributary of the SMV and the other a tributary of the SV. PV: portal vein, SV: splenic vein, SMV: superior mesenteric vein, IMV: inferior mesenteric vein, AccMV: accessory mesenteric vein, LGV: left gastric vein.

isolated SV thrombosis; type II: asymptomatic intrahepatic PV thrombosis without PH; type III: asymptomatic diffused PT; and type IV: isolated or diffused symptomatic PT²⁶. It occurs, in general, without known cause and is transitory; however, it has been more widely studied after splenectomy. Usually, it is asymptomatic, and there is no drug treatment yet that may prevent it or promote vascular rechanneling. Eventually, its clinical practice is associated with fever PT,

abdominal pain, diarrhea, ileodynamic, ascites, and bleeding of esophageal varices^{23,26,29}.

The knowledge of the abdominal portal system anatomy allows for the planning of venous bypasses to alleviate PH, mainly when associated with upper digestive hemorrhage. The bypasses include the right portocaval or with prosthesis, mesentericocaval, centralized and distal splenorenal, and left gastric caval.

The knowledge of portal anatomical variations helps also to understand the hepatofugal blood flow in the cases of PH¹. More than 20 pathways have been described; for example, the reflux for inferior mesenteric collateral vessels that are connected through the hemorrhoidal plexus¹.

CONCLUSION

Thomson classification of variants is the most well-known, accounting for over 90% of PV variant found in clinical practice, inasmuch as the sum of the three junctions are found in over 93% of the patients. Even though rarer and accounting for less than 7% of variants, the other nine reported variations will occasionally be found during many abdominal operations.

REFERENCES

1. Addeo P, Nappo G, Felli E, Oncioiu C, Faitot F, Bachellier P. Management of the splenic vein during a pancreaticoduodenectomy with venous resection for malignancy. *Updates Surg.* 2016;68(3):241-246. doi: 10.1007/s13304-016-0396-6.
2. Bacallao Cabrera I, Tamayo González E, Lorenzo Pérez E, Cuba Yordy O. Anatomic variants in liver irrigation and biliary tract. *AMC.* 2005; 9(5): 36-45.
3. Benninger B. Splenomesenteric vein: formally recognising a clinically relevant section of the portal venous drainage system. *Folia Morphol (Warsz).* 2013;72(1):63-6. doi: 10.5603/fm.2013.0010.
4. Bertoldi AS, Guetter CR, Coltro GA, Vosgerau LM, Brighenti LMV, Fauat NI, Kubrusly FB, Marques CAM, Kubrusly LF. Carvedilol as primary prophylaxis for gastric variceal bleeding in portal hypertension model in rats. *Arq Bras Cir Dig.* 2020;33(3):e1525. doi: 10.1590/0102-672020200003e1525. PMID: 33331427; PMCID: PMC7743326.
5. Carneiro C, Brito J, Bilreiro C, Barros M, Bahia C, Santiago I, Caseiro-Alves F. All about portal vein: a pictorial display to anatomy, variants and physiopathology. *Insights Imaging.* 2019;10(1):38. doi: 10.1186/s13244-019-0716-8.
6. Chajjaroonkhanarak W, Woraputtaporn W, Amarttayakong P, Umka J, Brown K, Pannangrong W, Namking M. Length, diameter and variation of types of portal vein formation in Northeastern Thais. *Srinagarind Med J.* 2010; 25(4): 323-327.
7. Christians KK, Lal A, Pappas S, Quebbeman E, Evans DB. Portal vein resection. *Surg Clin North Am.* 2010;90(2):309-22. doi: 10.1016/j.suc.2009.12.001.
8. Duques P, Araújo RS, Tolêdo ES, Rangel MF. Contribution to the study of anatomical variations in portal system formation. *Medicina (Ribeirao Preto. Online).* 2000; 33(4): 486-489.
9. Gilfillan RS, Hills HL. Anatomic study of the portal vein and its main branches. *Arch Surg.* 1950;61(3):449-61. doi: 10.1001/archsurg.1950.01250020454005.
10. Gorantla VR, Potu BK, Pulakunta T, Vollala VR, Addala PK, Nayak SR. Anomalous formation of the portal vein: a case report. *J Vasc Bras.* 2007; 6(4): 399-401. doi.org/10.1590/S1677-54492007000400016
11. Graf O, Boland GW, Kaufman JA, Warshaw AL, Fernandez del Castillo C, Mueller PR. Anatomic variants of mesenteric veins:

- depiction with helical CT venography. *AJR Am J Roentgenol.* 1997;168(5):1209-13. doi: 10.2214/ajr.168.5.9129413.
12. Ibukuro K, Tsukiyama T, Mori K, Inoue Y. Peripancreatic veins on thin-section (3 mm) helical CT. *AJR Am J Roentgenol.* 1996;167(4):1003-8. doi: 10.2214/ajr.167.4.8819401.
 13. Kaur H, Singh M, Bajaj AS. A cadaveric study of morphology of portal vein with its clinical importance. *Med J DY Patil Univ.* 2016; 9: 336-340. doi: 10.4103/0975-2870.182504
 14. Khamanarong K, Woraputtaporn W, Amarttayakong P, Ahojja A, Khuntikeo N. Classification of portal vein tributaries in Thai cadavers including a new type V. *Surg Radiol Anat.* 2016;38(6):735-9. doi: 10.1007/s00276-015-1592-7.
 15. Kim HJ, Ko YT, Lim JW, Lee DH. Radiologic anatomy of the superior mesenteric vein and branching patterns of the first jejunal trunk: evaluation using multi-detector row CT venography. *Surg Radiol Anat.* 2007;29(1):67-75. doi: 10.1007/s00276-006-0153-5. .
 16. Krumm P, Schraml C, Bretschneider C, Seeger A, Klumpp B, Kramer U, Claussen CD, Miller S. Depiction of variants of the portal confluence venous system using multidetector row CT: analysis of 916 cases. *Rofo.* 2011;183(12):1123-9. doi: 10.1055/s-0031-1281745. .
 17. Misuta K, Shimada H, Miura Y, Kunihiro O, Kubota T, Endo I, Sekido H, Togo S. The role of splenomesenteric vein anastomosis after division of the splenic vein in pancreatoduodenectomy. *J Gastrointest Surg.* 2005;9(2):245-53. doi: 10.1016/j.gassur.2004.06.003.
 18. Moher D, Liberati A, Tetzlaff J, Altman DG; PRISMA Group. Preferred reporting items for systematic reviews and meta-analyses: the PRISMA statement. *Ann Intern Med.* 2009;151(4):264-9, W64. doi: 10.7326/0003-4819-151-4-200908180-00135.
 19. Petroianu A. Surgical treatment of portal hypertension in schistosomiasis mansoni. *Rev Soc Bras Med Trop.* 2003;36(2):253-65. doi: 10.1590/s0037-86822003000200010.
 20. Purcell HK, Connor JJ, Alexander WF, Scully NM. Observations on the major radicals of the extrahepatic portal systems. *AMA Arch Surg.* 1951;62(5):670-7. doi: 10.1001/archsurg.1951.01250030680007.
 21. Raut RS, Bahetee BH. Study of variations in the formation of portal vein. *Sch J App Med Sci,* 2015; 3(3):1370-1375
 22. Sakaguchi T, Suzuki S, Morita Y, Oishi K, Suzuki A, Fukumoto K, Inaba K, Kamiya K, Ota M, Setoguchi T, et al. Analysis of anatomic variants of mesenteric veins by 3-dimensional portography using multidetector-row computed tomography. *Am J Surg.* 2010;200(1):15-22. doi: 10.1016/j.amjsurg.2009.05.017.
 23. Silva-Neto WB, Quirese C, Moura EGH, Coelho FF, Herman P. Does the drop in portal pressure after esophagogastric devascularization and splenectomy influence the variation of variceal calibers and the rebleeding rates in schistosomiasis in late follow-up? *Arq Bras Cir Dig.* 2021;34(2):e1581. doi:10.1590/0102-672020210002e1581. PMID: 34669877; PMCID: PMC8521859.
 24. Tewari M. Significance of pathological positive superior mesenteric/portal venous invasion in pancreatic cancer. *Hepatobiliary Pancreat Dis Int.* 2016;15(6):572-578. doi: 10.1016/s1499-3872(16)60156-x.
 25. Thomson A. Report of the Committee of Collective Investigation of the Anatomical Society of Great Britain and Ireland for the Year 1889-90. *J Anat Physiol.* 1890;25(Pt 1):89-101. PMID: 17231900; PMCID: PMC1328111.
 26. Tsamalaidze L, Stauffer JA, Brigham T, Asbun HJ. Postsplenectomy thrombosis of splenic, mesenteric, and portal vein (PST-SMPV): A single institutional series, comprehensive systematic review of a literature and suggested classification. *Am J Surg.* 2018;216(6):1192-1204. doi: 10.1016/j.amjsurg.2018.01.073.
 27. Walcker F. Contribution to knowledge of collaterals: the circulation of the blood in the portal system. *Langenbeck's Arch Klin Chir.* 1922; 120: 819-858.
 28. Ye K, Lin J, Sun Y, Wu Y, Xu J, He S. Variation and treatment of vessels in laparoscopic right hemicolectomy. *Surg Endosc.* 2018;32(3):1583-1584. doi: 10.1007/s00464-017-5751-2.
 29. Zhang XM, Zhong TL, Zhai ZH, Zeng NL. MR venography of the inferior mesenteric vein. *Eur J Radiol.* 2007;64(1):147-51. doi: 10.1016/j.ejrad.2007.02.017.