

Proposal of a Standard for the Condemnation for Turkey Carcasses Due to Fowlpox

■ Author(s)

Ferreira BC^I
Couto RM^{II}
Ecco R^{II}
Coelho HE^{III}
Rossi DA^I
Beletti ME^I
Silva PL^I

^I Universidade Federal de Uberlândia - UFU

^{II} Universidade Federal de Minas Gerais - UFMG

^{III} Universidade de Uberaba - UNIUBE

■ Mail Address

Corresponding author e-mail address
Bruna Ferreira
Rua Ceará, s/n, Bloco 2D, Sala 43, Campus
Umuarama
38402-018. Uberlândia, MG, Brasil
Phone: (5534) 98805-3007
E-mail: bruna_ferreira30@hotmail.com

■ Keywords

Condemnations, Fowlpox, processing plant, SIF.

ABSTRACT

This study aimed at proposing a new technical criteria for condemnation of turkey carcasses due to fowlpox in turkeys as a contribution for the work of the Brazilian Federal Meat Inspection Service. Skin samples from 30 carcasses of a flock of 840 turkeys (*Meleagris gallopavo*), previously vaccinated for fowlpox and slaughtered in June 2013, were collected. Samples were submitted to histological examination under light microscopy. The virus was identified using standard PCR techniques. The main histological findings were hyperplasia and hydropic degeneration of the epithelium and the presence of intracytoplasmic eosinophilic inclusion bodies. PCR results yielded 83.3% positive and 16.7% negative samples. Fowlpox virus is species specific, and there are no reports of its occurrence in mammals. The macroscopic and microscopic findings of the skin lesions do not justify the total condemnation of carcasses of poultry affected with fowlpox, except in cases of cachexia or repulsive appearance, as established by SIF regulation.

INTRODUCTION

Fowlpox is a disease caused by a Avipoxvirus belonging to the Poxviridae family. The fowlpox virus or FPV is species specific and its nomenclature follows the affected species. It has been isolated in avian species, such as chickens, turkeys, quails and canaries. The disease has been reported in over 200 domestic and wild avian species worldwide (Ha *et al.*, 2013).

After the infection by Avipoxvirus, host responses are characterized by two phases: during the first 72 hours, there is dramatic host cell hyperplasia, followed by virus replication 72-96 hs after infection (Cheevers & Randall, 1968; Cheevers *et al.*, 1968). The virus causes proliferative skin lesions, which are discrete and nodular in featherless skin areas (cutaneous form) or fibrin-necrotic and proliferative lesions in the mucous membrane of the upper respiratory tract, mouth and esophagus (mucosal or diphtheritic form) (Moço *et al.*, 2008). Both types of lesion may be present in a same bird, characterizing the mixed form.

Avian pox, contagious epithelioma, molluscum contagiosum, avian diphtheria and fowlpox are used synonyms, but fowlpox is the most commonly used (Van Riper & Forrester, 2008; Tripathy & Reed, 2008). In Brazil, Vargas *et al.* (2011) reported fowlpox in barn owls (*Tyto alba*), and Back *et al.* (1995) in broilers. Because it is a sporadic disease, information is lacking. Fowlpox is prevented by vaccination of susceptible birds with attenuated strains derived from chicken virus or from antigenically-similar pigeon virus.

The Brazilian meat inspection legislation is not clear as to the condemnation of carcasses of poultry with fowlpox. The two articles of the Animal Products Health Inspection Regulation (RIISPOA; Brasil, 1962) indicate different destinations for symptomatic carriers of the disease. Furthermore, there are few records of fowlpox commercial



poultry in Brazil and disease nomenclature widely varies. Article nº 229 of RIISPOA establishes that “during ante or post-mortem examination, all birds presenting symptoms or suspected of tuberculosis, pseudotuberculosis, diphtheria, fowl cholera, fowlpox, [...], must be condemned,” where as Article nº 230 establishes that “Diseases such as [...], contagious epithelioma, [...] require complete rejection when animals are in the acute phase of the disease or extremely emaciated” (Brasil, 1962).

The absence of studies, the lack of clear regulations in the current Brazilian legislation and of standardization in the nomenclature of the disease often cause the unnecessary condemnation of carcasses with fowlpox characteristic lesions, which consequently reduces the productivity of the Brazilian poultry industry.

This study aimed at proposing new technical criteria for the diagnostic of fowlpox in turkey carcasses based on the characterization of lesions and on the molecular identification of the virus.

MATERIALS AND METHODS

The study was carried out in a processing plant in the state of Minas Gerais (MG), Brazil, in collaboration with the Brazilian Federal Meat Inspection Service (SIF). In June 2013, samples were collected from a flock of 840 turkeys (*Meleagris gallopavo*), previously vaccinated against fowlpox and slaughtered with 115 days of age, with 15.440 kg average body weight. Thirty carcasses were removed from the processing line for the collection of skin lesions, after which carcasses were sent to the rendering plant. Samples were collected using sterile scalpel and forceps.

One lesion (Figure 1) per bird was clamped to remove fragments containing both injured and healthy tissues, which were then separated, placed in sterile microtubes containing buffered formalin (10%), and frozen until analyses.

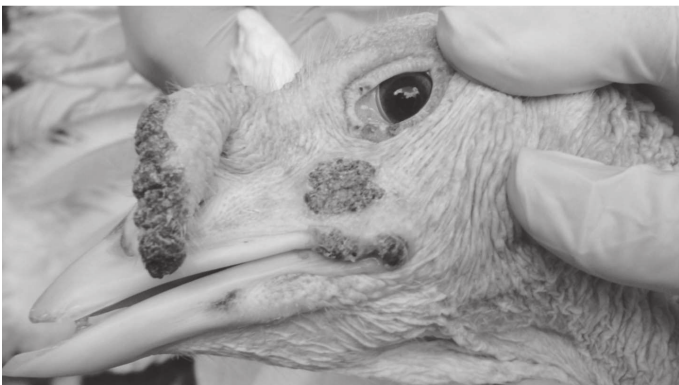

Figure 1 - The turkey (*Meleagris gallopavo*), with nodular skin lesions in areas devoid of feathers, suspected of fowlpox. Minas Gerais, May 2013.

Histopathological examination of the samples was performed at the Laboratory of Histological Techniques of the Federal University of Uberlândia, MG, Brazil. Samples were fixed in formalin, embedded in paraffin, cut into 6µm sections, stained with hematoxylin-eosin, and examined under an optical microscope.

Virus identification was performed by molecular diagnosis in the Laboratory of Molecular Pathology of the Federal University of Minas Gerais, MG, Brazil.

For DNA extraction, samples were thawed and the DNA extracted using sodium iodide (NaI) and silica, according to the methods of Boom *et al.* (1990) and Volglstein & Gilles (1979), with modifications. Tissue samples were scraped using a 2.0 scalpel blade on a Petri dish, transferred to sterile 1.5mL microfuge tubes, and macerated using a small pestle. A volume of 300µL of NaI was added to dissolve the tissue and to break up cell membranes. DNA solution was absorbed in 40µL silica, and then washed serially with ethanol, with a final wash using acetone.

The extracted DNA was eluted in 40µL TE (Tris EDTA), quantified using a spectrophotometer (Nanodrop ND-1000, Thermo Scientific, Wilmington, USA), and stored at -20°C.

PCR reactions were performed according to the manufacturer's recommendation for a volume of 25µL (PCR Master mix Promega), using 200ng of DNA sample and 0.02nmol of primer. The primer sequence applied was 5'-CAGCAGGTGCTAAACAACAA 3' and 5'-CGGTAGCTTAACGCCGAATA 3' (Biins *et al.*, 1989). DNA amplification was performed at 94°C for 5 min, followed by 45 cycles at 94°C for 1 min, 60°C for 1 min, 72°C for 1 min, and final extension at 72°C for 7 min, according to Lawson *et al.* (2012). The amplified PCR products were separated by electrophoresis on 1.5% agarose gel and visualized after ethidium bromide staining under UV transillumination.

The procedures of this study were approved by the Ethics Committee on Animal Use of the Federal University of Uberlândia, under protocol number 199/13, CEUA / UFU 125/13.

RESULTS

The histopathological examination of the lesions (Figures 2 and 3) showed hyperkeratosis, acanthosis, and hydropic degeneration. The presence of intracytoplasmic inclusion bodies (Bollinger bodies) in the keratinocytes, which is a pathognomonic sign of fowlpox, was detected, confirming the diagnosis of the disease.

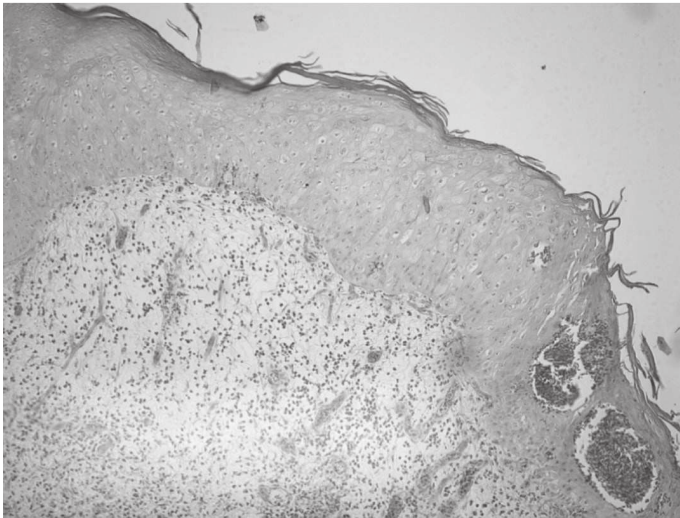


Figure 2 - Hyperplasia and enlargement of the epithelial cells, inflammatory infiltrate bordering the epithelial tissue. H&E x10.

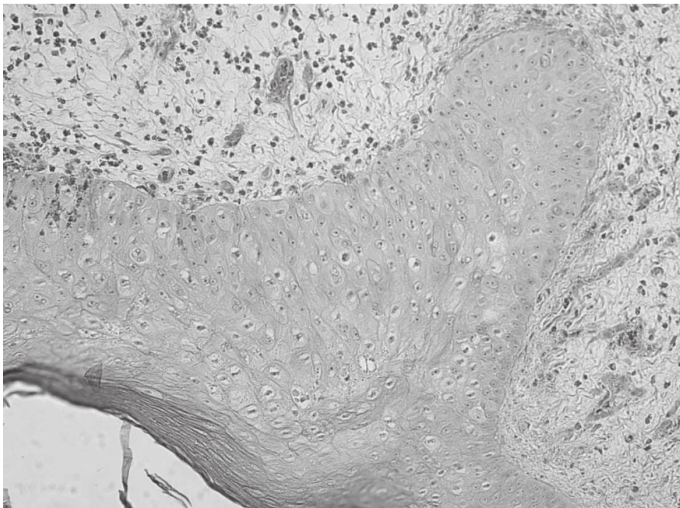


Figure 3 - Cells with hydropic degeneration and vacuolization, inflammatory infiltrate bordering the epithelial tissue. H&E x20

The fowlpox virus was identified by PCR in 25/30 (83.3%) of the samples. Five of the tested samples (16.7%) were negative. Figure 4 shows the amplified products of the P4b region of the fowlpox virus gene in 1.5% agarose gel.

Table 1 shows the percentage of carcasses condemned due to "contagious epithelioma" in the studied processing plant between December 2012 and December 2013.

Table 1 – Percentage of partial condemnation for "other causes" and total condemnations of turkey carcasses due to "contagious epithelioma" in a processing plant under Federal Meat Inspection located in the state of Minas Gerais, Brazil, from January to December 2013.

Condemnation	Causes	Jan	Feb	Mar	Apr	May	Jun	Jul	Aug	Sep	Oct	Nov	Dec
Partial	Other	29.10	19.14	11.20	13.32	19.88	21.14	21.59	16.53	11.91	14.74	21.36	16.98
Total	Contagious epithelioma	-	-	40.38	37.12	16.08	8.68	1.63	0.62	-	0.91	1.29	-

Source: Federal Meat Inspection Service

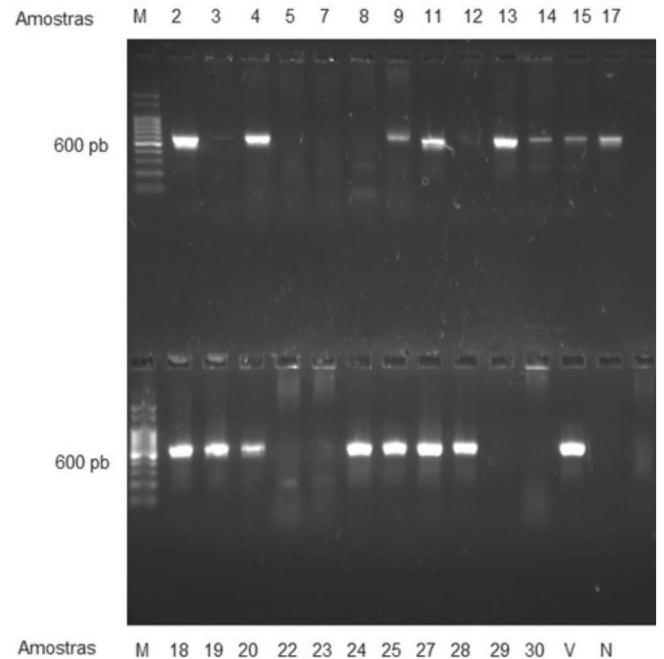


Figure 4 - PCR amplification products of the P4b gene of fowlpox virus. Positive (amplified fragment of 600 bp): 2, 3, 4, 8, 9, 11, 13, 14, 15, 17, 18, 19, 20, 23, 24, 25, 27, 28 and 29; Negative samples: 5, 7, 12, 22 and 30; M, molecular marker; V positive control; N negative control.

DISCUSSION

In January 2013, the registers of the SIF (Federal Meat Inspection Service) showed an increase in partial carcass condemnations due to "other causes". Such carcasses presented multiple nodular lesions in featherless areas, particularly on the neck and head, suggesting fowlpox. In March 2013, after the official confirmation of the presence of the disease by the SIF, the item "contagious epithelioma", a synonym of fowlpox, was included in the SIF's spreadsheets.

After that, carcasses started to be condemned for fowlpox according to criteria established by the SIF, changing the scenario, as carcasses were not previously condemn for this disease. Carcasses were classified in degrees 1-3, according the number of lesions and their distribution. Degree 1 corresponded to carcasses with 1-3 isolated lesions, determining partial condemnation; degree 2 to carcasses with 3-5 lesions, determining



partial condemnation; and degree 3 to carcasses with more than 5 and/or clustered lesions, determining total condemnation. This classification was assigned only to advanced lesions; early-stage lesions were not considered.

Histopathological analysis (Figures 2 and 3) showed the presence of lesions suggestive of fowlpox, such as hyperplasia, hydropic degeneration, and intracytoplasmic inclusion bodies in the epithelial cells. Epithelial hyperplasia (Figure 2) is considered an important feature in the development of fowlpox lesions because of the epidermal growth factor present in the avipoxvirus genome (Tripathy & Reed, 2008). According Arhelger *et al.* (1962), the intracytoplasmic eosinophilic inclusion bodies appear in the epithelial tissue 72 hours after infection. These bodies are found in the cells infected with fowlpox virus and consist of aggregates of virus particles and are also sites of their multiplication (Eaves & Flewett, 1955).

Molecular analysis showed the amplification of 4b gene fragment, important for the formation of the nucleus structure during virus assembly (Chiu & Chang, 2002). This is a highly conserved gene in the avian poxvirus genome (Biins *et al.*, 1989). The 16.7% negative results obtained were probably caused by an uneven distribution of the virus in the samples as small sample volumes are used in molecular methods. However, such methods are required to confirm the diagnosis when the cause of carcass condemnation is truly a non-zoonotic infection, such as fowlpox, needs to be proven.

There are no reports on the occurrence of fowlpox in mammals. Tripathy & Reed (1997) stated that fowlpox has no significance in public health, and there are no reports of infection in humans. Berchieri & Marcari (2000) also claim that it is not a disease of public health interest, and it does not infect mammals. Because fowlpox does not pose any public health risk, the total condemnation of poultry carcasses presenting external lesions, as stipulated in Article n° 229 of Regulation of Industrial and Sanitary Inspection of Animal Products (Brazil, 1962), is not necessary. Article n° 230 provides a better solution, as it establishes that "... complete rejection when animals are in the acute phase of the disease or extremely emaciated" (Brasil, 1962).

Considering that the fowlpox virus is an epitheliotropic virus, and that its cutaneous form causes only superficial skin lesions in featherless areas, only such areas should be trimmed during processing. However, when birds present the diphtheric form of

the disease, their general body condition is sufficient to condemn their carcasses for cachexia or repulsive appearance. In addition, a standard nomenclature should be adopted in the legislation, because fowlpox, diphtheria and avian pox are used and synonyms and may cause confusion during carcass inspection.

The observed macroscopic and microscopic features of the evaluated skin lesions do not justify the total condemnation of the carcasses of poultry affected by the fowlpox virus, except when carcasses present cachexia or repulsive appearance, as established by SIF regulation.

ACKNOWLEDGEMENT

At the Foundation for Research Support of the State of Minas Gerais - FAPEMIG and CAPES for funding of research and scholarship. The Federal Inspection Service for their support.

REFERENCES

- Arhelger RB, Darlington RW, Gafford LG, Randall CC. An electron microscopic study of fowlpox infection in chick scalps. *Laboratory Investigation. Journal of Technical Methods and Pathology* 1962;11:814-825.
- Back A, Soncini RA, Ruthes O, Madureira Jr S, Flores R. An atypical fowl pox outbreak in broilers in southern Brazil. *Avian Diseases* 1995;4:902-906.
- Berchieri Junior A, Macari M. *Doenças das aves*. Campinas: Facta; 2000. p.333-338.
- Binns MM, Boursnell MEG, Tomley FM, Campbell J. Analysis of the fowl poxvirus gene encoding the 4b core polypeptide and demonstration that it possesses efficient promoter sequences. *Virology* 1989;170:288-291.
- Boom R, Sol C, Salimans MM. Rapid and simple method for purification of nucleic acids. *Journal of Clinical Microbiology* 1990;28:495-503.
- Brasil. Decreto n° 30.691 de 29 de março de 1952, alterado pelo Decreto n° 1.255 de 25 de junho de 1962. Regulamento de inspeção industrial e sanitária de produtos de origem animal (RIISPOA). 1962. *Diário Oficial da União*, 7 jul. 1962.
- Cheevers WP, Randall CC. Viral and cellular growth and sequential increase of protein and DNA during fowlpox infection in vivo. *Experimental Biology and Medicine* 1968;127:401-405.
- Cheevers WP, O'Callaghan DJ, Randall CC. Biosynthesis of host and viral deoxyribonucleic acid during hyperplastic fowlpox infection in vivo. *Journal of Virology* 1968;5:421-429.
- Chiu WL, Chang W. Vaccinia virus J1R protein: a viral membrane protein that is essential for virion morphogenesis. *Journal of Virology* 2002;76:9575-9587.
- Eaves G, Flewett TH. The structure of fowl-pox inclusions (Bollinger bodies). *Journal of Hygiene* 1955;53(01):102-105.
- Ha HJ, Alley M, Howe L, Gartrell B. Evaluation of the pathogenicity of avipoxvirus strains isolated from wild birds in New Zealand and the efficacy of a fowlpox vaccine in passerines. *Veterinary Microbiology* 2013;165:268-274.



Lawson B, Lachish S, Colvile KM, Durrant C, Peck KM, Toms MP, et al. Emergence of a novel avian pox disease in British tit species. *PloS One* 2012;11:e40176.

Moço HF, Dias LC, Andolfato LHM, Alves ML, Bronzatto A, Raya DA. Boubá Aviária. *Revista Científica Eletrônica de Medicina Veterinária* 2008;11:1-5.

Tripathy DN, Reed WN. Pox. In: Calnek BW. *Diseases of poultry*. 10th ed. Ames: Iowa State University Press; 1997. p.643-659.

Tripathy DN, Reed WN. Pox. In: Calnek BW. *Diseases of poultry*. 12th ed. Ames: Blackwell Publishing; 2008. p.291-308.

Van Riper C, Forrester DJ. Avian pox. In: Thomas NJ, Hunter DB, Atkinson CT, editors. *Infectious diseases of wild birds*. Ames: Blackwell Publishing Professional; 2008. p.131-171.

Vargas GD, Albano AP, Fischer G, Hübner S, Sallis SE, Nunes CF, et al. Avian pox virus infection in a common barn owl (*Tyto alba*) in southern Brazil. *Pesquisa Veterinária Brasileira* 2011;31:620-622.

Vogelstein B, Gillespie D. Preparative and analytical purification of DNA from agarose. *Proceedings of the National Academy of Sciences* 1979;76:615-619.

