

The Pterygospinous Foramen (Civinini) and the Pterygoalar (Crotaphitico-Buccinatorius). Laboratory Findings

El Foramen Pterigoespinoso (Civinini) y el Pterigoalar (Crotafítico-Buccinatorius). Hallazgos de Laboratorio

Kennedy Martinez de Oliveira¹; Valério Landim de Almeida¹; Carlos Alberto Carranza López¹; Guilherme Tatagiba Brandão²; Marcos Guilherme Bedim Trancoso³; Maísa de Fátima Satiro Oliveira⁴; Isabela Coimbra Ladeira Moraes⁵; Daniele Cristina Barbosa Soares⁵ & Luana Carolina Maletta Costa⁶

OLIVEIRA, K. M.; DE ALMEIDA, V. L.; LÓPEZ, C. A. C.; BRANDÃO, G. T.; TRANCOSO, M. G. B., OLIVEIRA, M. F. S.; MORAIS, I. C. L., SOARES, D. C. B. & COSTA, L. C. M. The pterygospinous foramen (civinini) and the pterygoalar (*Crotaphitico-buccinatorius*) Laboratory findings. *Int. J. Morphol.*, 39(1):198-204, 2021.

SUMMARY: The Pterygospinous foramen and pterygoalar foramen (crotaphitico-buccinatorius) are variant and atavic formations of the skull base and arise respectively from complete or incomplete idiopathic ossifications of the pterygospinous and pterygoalar ligaments. By proximity with areas of relevance for diagnosis and surgery, such as access pathways to the parapharyngeal and retropharyngeal spaces, it is necessary to be aware of these conditions due to the difficulties generated in surgical maneuvers and the promotion of compressive syndromes of mandibular nerve branches. This study was conducted on 45 samples of dry skulls and disarticulated sphenoid bones belonging to the collection of the Federal University of Juiz de Fora, Governador Valadares campus, Minas Gerais, Brazil. Our results indicated a total incidence of complete and incomplete pterygospinous and pterygoalar foramen (crotaphitico-buccinatorius) in 15, 5 % (7 skulls), with a higher incidence for the incomplete form of pterygospinous foramen (Civinini foramen) in 4 skulls (8.8 %), with 3 presenting unilaterally and 3 presenting bilaterally. The pterygoalar foramen (crotaphitico-buccinatorius or Hyrtl) was noted bilaterally in 1 of the skulls (2.2 %). The pterygospinous foramen and pterygoalar foramen are important findings, sometimes incidental, of an area of great anatomical expressiveness and pathological occurrences, besides the indispensable and unclear studies of phylogenetic order.

KEY WORDS: Pterygospinous ligament; Pterygoalar ligament; Oval foramen and Pore crotaphitico-buccinatorius.

INTRODUCTION

For access to the base of the skull the transnasal, transoral and transfaryngeal pathways are used and also, in many of the access procedures to pathological formations, the lateral transzigomatic, which will follow to the infratemporal fossa and, from there, through adjacent retro and parapharyngeal spaces (Al-Khatib, 2006; Ryu *et al.*, 2016), with the sphenoid bone spine, the styloid process and the pterygoid process constituting important anatomical landmarks of this transition (von Lüdinghausen *et al.*, 2006; Saran *et al.*, 2013).

The ossification of fibrous tissues and/or ligaments associated with sphenoid bone are common and occur in up

to 58.3 %, according to a large study conducted by Touska *et al.* (2019), and among these occurrences, and with neurological and surgical relevance, we note the pterygospinous and pterygoalar foramen (crotaphitico-buccinatorius) (Goyal & Jain, 2016). These foramen are atypical formations of the homonymous ligaments present in the sphenoid bone and, due to their positions, of paramount importance because they make extracranial access procedures more difficult, mainly aiming at the oval foramen and its surroundings (Isolan & Al-Mefty, 2008; Erdogmus *et al.*, 2009; Suazo *et al.*, 2010; B & K, 2014; Singh & Niranjana, 2019; Somayaji *et al.*, 2019; Henry *et al.*, 2020). Nevertheless, detailed clinical and anatomical information associated with the foramen formations and their

¹ Department of Basic Life Sciences, Federal University of Juiz de Fora, campus Governador Valadares, Minas Gerais, Brazil.

² Faculty of Medicine, Federal University of Juiz de Fora, campus Governador Valadares, Minas Gerais, Brazil.

³ Faculty of Medicine, Higher School of Sciences of Santa Casa de Misericórdia de Vitória, Espírito Santo, Brazil.

⁴ Faculty of Medicine, Federal University of Minas Gerais, Minas Gerais, Brazil.

⁵ Faculty of Odontology, Federal University of Juiz de Fora, campus Governador Valadares, Minas Gerais, Brazil.

⁶ Postgraduate studies in Art in Education: dance, music and theater of Faculty Venda Nova do Imigrante – FAVENI, Espírito Santo, Brazil.

proximity to the oval foramen still require studies (Tubbs *et al.*, 2009), especially the relations of the fascial tissues and skull, which are fundamental in understanding the fibrous formations at the cranial base (Komune *et al.*, 2019). In addition to the ligament structures, in the constitution of these foramen, the pterygospinous muscle, as described by von Lüdinghausen *et al.* was reported in 9.2 % of its specimens and the modalities of associations between this and the homonymous ligamentous form, ossified or not, in the investigations of Al-Khatib.

The pterygospinous muscle, variant, is probably a third head of the lateral pterygoid muscle and the pterygospinous ligament, a reinforced extension of the interpterygoid fascia (von Lüdinghausen *et al.*; Saran *et al.*; Komune *et al.*). Iwanaga *et al.* (2020) dissected 30 infratemporal fossae for the pterygoalar and pterygospinous ligaments and their respective bars and did not report any muscle formations similar to the pterygospinous or pterygoalar type. Regarding the origins of these ossifications or calcifications, with their respective foraminal formations, there is strong evidence, by comparative anatomy, that they are phylogenetic and atavistic remnants and, therefore, erratic in humans (von Lüdinghausen *et al.*; Al-Khatib). The incidence is very variable, probably related to differences in ethnic groups (Yadav *et al.*, 2014) or to individual differences in the methods of analysis and acceptance of these occurrences (Goyal & Jain). Yadav *et al.* reported 10.2 % of pterygospinous formations of 500 evaluated skulls, while Goyal & Jain noted 17.33 % of complete and incomplete pterygospinous foramen formation in 75 evaluated specimens. In this paper we discuss the laboratory findings of five incomplete pterygospinous foramen formations and another complete and bilateral pterygoalar foramen (*crotaphitico-buccinatorius*), and its anatomical implications.

MATERIAL AND METHOD

A total of 45 specimens between dry skulls and disjointed sphenoid bones (90 halves in total) from the shared collection of the anatomy laboratory at the University of Juiz de Fora, Governador Valadares campus (UFJF / GV) were selected and studied over the years of 2018 and 2019. All evaluated by direct cranioscopy, without special lighting and by a single examiner, from the perspective of the pterygospinous foramen and pterygoalar foramen (*crotaphitico-buccinatorius*), considering, in each skull, the microregional integrity of the infratemporal fossa roof and the structural conformation typical of a natural foramen. In none of the structures was there identification regarding sex and age. The dimensions of the complete foramen and the pterygoalar bone bars were taken using a digital caliper (Western Pro), resolution of 0.1 mm. The area for each foramen was calculated using the Radinsky's formula.

RESULTS

Our work resulted in the combined identification of 10 foraminal formations in 7 skulls (15.5 %) with the following distribution: two complete and bilateral *crotaphitico-buccinatorius* foramen, in one of the skulls (2.2 % of those evaluated) (Fig. 1) and in the other 6 skulls there were 5 incomplete formations of the pterygospinous foramen (Figs. 2 and 3), being unilateral in 3 skulls and in the fourth, bilaterally and 3 incomplete formations of the pterygoalar foramen, according to Table I. The two pterygoalar foramens (*crotaphitico-buccinatorius*) occurred in a lateral position to the oval foramen and underwent morphometry according to Table II.

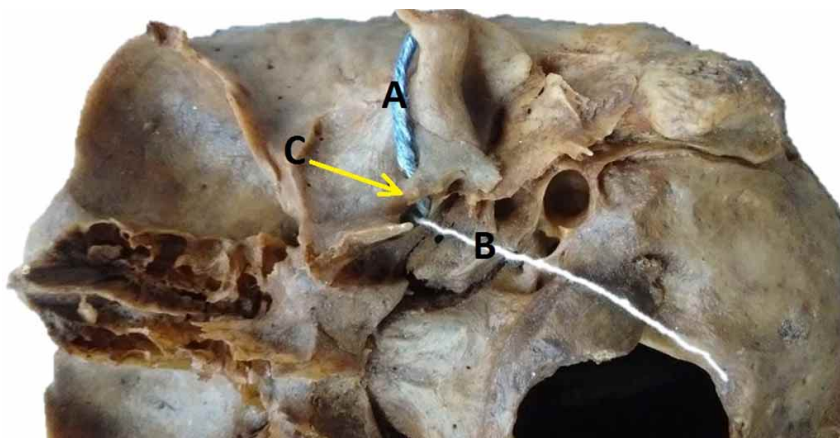


Fig. 1. Skull in basal norm demonstrating the complete left pterygoalar bar in "C" and the pterygoalar foramen in "A" where the string crosses it from the oval foramen. In "B" the string crosses exclusively the foramen ovale.

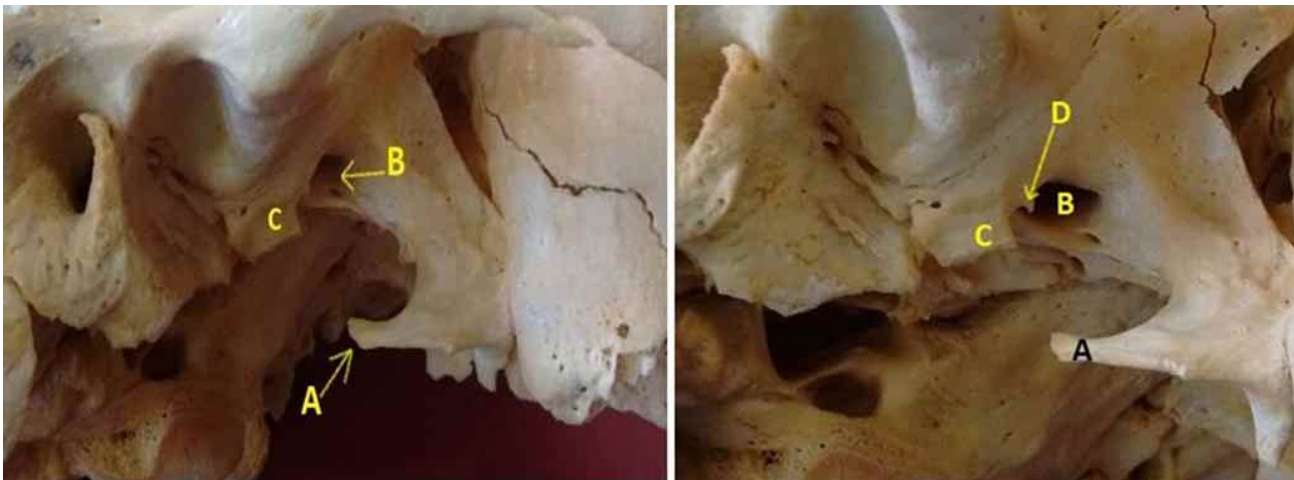


Fig. 2. Skull in right inferior-lateral view. In "A" Civinini's spine (in an inferior position). In "B" the oval foramen, in "C" the spine of the sphenoid bone is very sharp and in "D" incomplete formation of the pterygoalar bone bar.

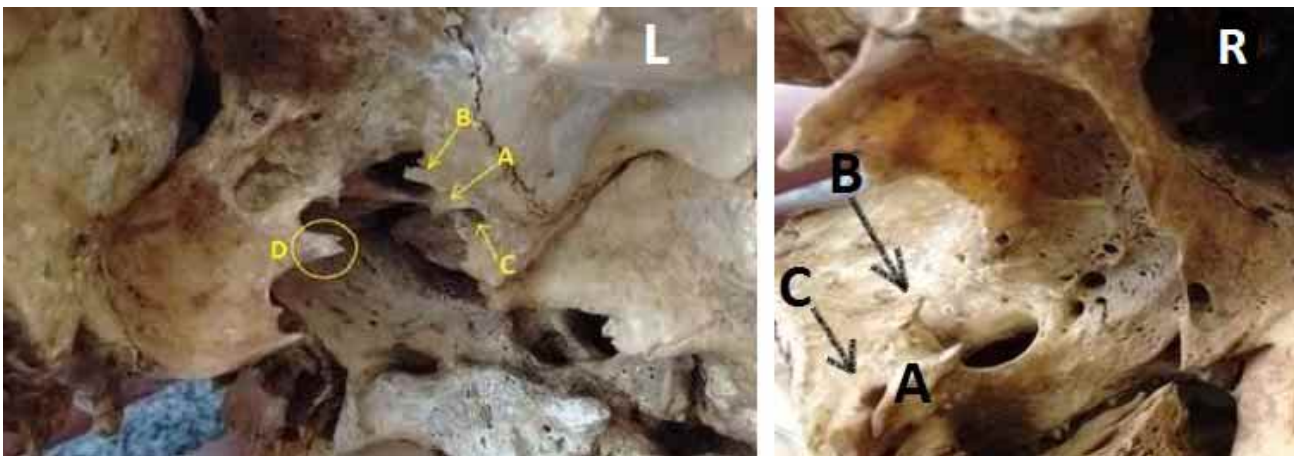


Fig. 3. In the image "L", on the left side, the Civinini spine sharpened and delimited by the yellow circle in "D", the arrow "C" indicates the spinous foramen; the arrow "A" indicates the incomplete ossification of the pterygospinous bar from the spine of the sphenoid bone and the arrow "B" indicates the incomplete ossification of the pterygoalar bar. In the image "R", right side, the arrow in "C" indicates the spinous foramen; the arrow "A" indicates the incomplete ossification of the pterygospinous bar and in "B" the incomplete ossification of the pterygoalar bar.

Table I. Occurrences of the crotaphitico-buccinatorius and pterygospinous foramen in the sample of 45 skulls and disarticulated sphenoid bones.

	Foramen crotaphitico-buccinatorius		Total	Foramen pterigoespinhoso		Total
	Complete	Incomplete		Complete	Incomplete	
Right	0	1 skull	1	0	2 skulls	2
Left	0	0	0	0	1 skull	1
Bilateral	1 skull	1 skull	2	0	1 skull	1
Total	1 skull	2 skulls	3(3,3 %)	0	4 skulls	4 (8,8 %)

Table II. Morphometry of complete pterygoalar foramen and pterygoalar bone bars.

Structure	Length	Width	Thickness	Area	Side
Foramen pterygoalar 1	5,5 mm	2,3 mm	-	9,9 mm ²	Right
Foramen pterygoalar 2	4,15 mm	2,0 mm	-	6,5 mm ²	Left
Bar pterygoalar 1	8,3 mm	3,20 mm	1,15 mm	-	Right
Bar pterygoalar 2	7,2 mm	2,70 mm	1,20 mm	-	Left

DISCUSSION

The ossification of pterygospinous and pterygoalar ligaments are relevant conditions in the clinic, due to their proximity, in the infratemporal fossa, with the foramen ovale and the parapharyngeal and retropharyngeal spaces, important in surgical maneuvers of resections, decompressions, punctures and anesthetic infiltrations (Al-Khatib; Erdogmus *et al.*; Tubbs *et al.*; Rosa *et al.*, 2010; Yadav *et al.*; Singh & Niranjana).

The sphenoid bone has ligaments in narrow points of neurovascular pathways and subject to ossification and/or calcification, resulting, under certain conditions, in compressive nerve syndromes, as can occur with the petrosphenoid ligament (abducent nerve), the petroclinoid ligament (oculomotor nerve) and the pterygospinous and pterygoalar ligaments (mandibular nerve branches) (Somayaji *et al.*; Touska *et al.*; Iwanaga *et al.*). The disposition of the pterygospinous ligament occurs from the lateral lamina of the pterygoid process to the spine of the sphenoid bone, immediately superior to the foramen ovale (Erdogmus *et al.*; Goyal & Jain), while that of the pterygoalar ligament is from the inferior portion of the greater wing of the sphenoid bone, near the anterolateral edge of the foramen spinosum, to the root of the lateral lamina of the pterygoid process (Tubbs *et al.*).

Shapiro & Robinson (1967) related the fascia between the pterygoid muscles and the bone bar formations – pterygospinous and pterygoalar and their respective foramen. von Lüdinghausen *et al.* report that there are not only ossified bridges between the pterygoid process and the sphenoid spine, in the case of the pterygospinous foramen, there are the fibrous bridges of firm connective tissue and the muscular bridges that also affect the distribution of the mandibular nerve. The muscle bridges were reported in the findings of Komune *et al.*; and in the investigations of Al-Khatib, (2006), the author identifies them as a distinct variant muscle called pterygospinous, found in 8 out of 68 of his preparations (11.76 %), and may have two origins and several associations to the pterygospinous ligament. von Lüdinghausen *et al.* also report the possibility of ligament fixation of the pterygospinous ligament, in addition to the sphenoid bone spine, with extensions to the articular tuber and articular disc of the temporomandibular joint. However, Iwanaga *et al.* reported the concomitant existence, in some of their dissected specimens, of bone formation, in bridges, independent of the pterygoalar ligament, and suggest, which is controversial, the independence between the ossification and the ligament structure. The same occurred with some pterygospinous ligaments in which they were next to ossified

formations, indicating perhaps, by suggestion, an incomplete or independent ossification process. As for the incidences, conformations and presentations of these foramen, there are very discrepant findings in the literature.

A study with 500 dry skulls from the Kanpur Museum of Anthropology and Anatomy, India, specifically focused on the analysis of the occurrence of pterygospinous foramen, among complete and incomplete classifications, the authors pointed to an incidence of 10.2 % (51 skulls) (Yadav *et al.*). Of the 312 dry skulls in the UNIFESP (Brazil) collection, 37.18 % were identified, in varying degrees of complete and incomplete foramina formations (Suazo *et al.*). An Indian study conducted by B & K, on a sample of 100 dry skulls from the Department of Forensic Medicine and Medical Sciences of Shimoga, the authors reported the total incidence, between the various extensions of ligament ossifications, to form both foramina, at 41 %. Tubbs *et al.* in examinations of 154 skulls with detailed analyses of the dimensions of foramen and associated ligaments, reported an incidence of completely closed and open foramen in 2.6 % of the specimens (2 foramen from each: pterygospinous and crotaphitico-buccinatorius).

When the foramen are examined for its conformations, simultaneity (between the pterygospinous and pterygoalar) and extensions of its calcifications there are various classifications, as is the case with the survey conducted by B & K, in which the authors classified the foramen, considering these parameters, into three types, already in the studies of Suazo *et al.* from 312 dry skulls, classified them into four types, using the criterion of extensions of ossifications (complete or incomplete) and without morphometric analysis, similar classification adopted by Ryu *et al.* However, his studies applied morphometric analysis to the foramen dimensions.

Iwanaga *et al.* proposed a classification to differentiate foramen by its relationship with the mandibular nerve and then differentiate the pterygoalar foramen, when characterized in two types, also with respect to the mandibular nerve and its branches.

The pterygospinous foramen was first described by the Italian anatomist Filippo Civinini, however, Giovanni Filippo Ingrassia, also an Italian anatomist from Sicily, is credited with being the first to accurately describe the sphenoid bone and recognize the foramina variant structure (Cappello *et al.*, 2010; Saran *et al.*; Costea *et al.*, 2018). It is an infratemporal, variant and low incidence cranial formation, representing an important condition for neurological diagnoses and a limiting element for neurosurgery (Tubbs *et al.*; Goyal & Jain).

The pterygospinous foramen is located medially to the oval foramen and is delimited between the upper edge of the ossified pterygospinous ligament and the base of the skull and complemented by cribiform tissue from an extension of the interpterygoid fascia and being crossed by the tensor palatine veil muscle, accessory middle meningeal artery and medial pterygoid nerve (Saran *et al.*; B & K; Komune *et al.*; Somayaji *et al.*).

Saran *et al.* report that typically, to form the pterygospinous foramen, there is mineralization of fibrous tissue from the Civinini's spine, present at the base of the lateral blade of the pterygoid process or from its central part, to the sphenoid bone spine. In our studies, we recognized the incomplete pterygospinous foramen, in those findings that we noticed accentuated and acute projections of Civinini's spines in postero-inferior prominence, in the direction of a sphenoid bone spine also very projected. As for conformation, the pterygospinous foramen may be complete or incomplete, depending on the extent of its ossification, in addition to uni or bilateral (Tubbs *et al.*; Goyal & Jain; Somayaji *et al.*). Suazo *et al.* reported only 1.6 % of a complete pterygospinous foramen formation (Type I of these authors).

Singh & Niranjana in a study of 530 dry skulls, noted, between complete and incomplete formations, ossifications in 9.8 % of the specimens, 31 skulls with complete foramina formations and 21 incomplete skulls. Chouké (1946), in 1544 skulls, reported 6.28 % occurrence for pterygospinous foramen formation more frequently in white individuals than in black individuals. B & K reported 17 skulls (17 %) between incomplete (16) and complete formations (1), similar incidence to Goyal & Jain in which the authors reported a total of 17.33 % complete and incomplete of 75 specimens (150 laterals). Jansirani *et al.* (2012) on 204 skulls, reported complete ossification of the pterygospinous ligament on only 2 skulls (0.98 %) and incomplete ossification on 22 skulls (10.78 %). In the studies of Yadav *et al.* the authors reported an incidence of 4 % for the complete formation of pterygospinous foramen. Tubbs *et al.* reported, of 154 skulls, only 2 skulls, one with complete formation and another with incomplete formation of pterygospinous foramen (1.3 %). Saran *et al.* noted between complete and incomplete foramen the incidences of 1.25 and 7.5 %, respectively. Henry *et al.* in a metanalytical study involving 35 studies (14,047 specimens), reported a higher prevalence of incomplete formation of pterygospinous foramen in 11.6 % compared to complete formation (4.4 %) between the selected studies.

Our findings pointed to 8.8 % of pterygospinous foramen in varying degrees of incomplete conformation. As for the antimeres, B & K noted a higher incidence of

pterygospinous foramen on the left side of 62.5 % (all of them incomplete), values that are very expressive and coincident with the side also verified by Tubbs *et al.* who identified 75 % of their findings on the left side. von Lüdinghausen *et al.* and Al-Khatib reported that the pterygospinous foramen would represent a phylogenetic remnant in humans. von Lüdinghausen *et al.* noted, in studies by computerized tomography of old world monkeys (*Macaca fuscata*) and skulls of herbivores, rodents and carnivores, the presence of an expressive ossified pterygospinous ligament (monkeys, herbivores and carnivores) and a tenuous formation in rodents. Justifiable structure for higher muscle fixation. Which is unusual for humans. In monkeys of the new world, there was no detection of this formation (Al-Khatib).

The pterygoalar foramen or crotaphitico-buccinatorius, described by Hyrtl in 1862 (Chouké), is related to the ossification of the pterygoalar ligament and, by proximity to the pterygospinous, also related to the neurological and vascular clinical conditions in the infratemporal fossa by proximity to the oval foramen. Iwanaga *et al.* report that the pterygoalar ligament or the result of its ossification can be subdivided (classification proposal) into types I and II as to the topographic relationship of this ligament and the branches of the mandibular nerve. Thus, Type I is positioned between the buccal nerve and mandibular nerve and Type II is located medially to the inferior alveolar nerve and lateral to the lingual nerve. Suazo *et al.* reported, with a complete ossification, only in 12 cases (3.84 %). Chouké recorded in an extensive work with 1544 skulls, from the anatomy department of the University of Washington, of the white and black individuals, 10.3 % of occurrence for the pterygoalar foramen, being twice as frequent in skulls of black individuals.

Ryu *et al.* in 284 dry skulls of adult Koreans, described 8 complete pterygoalar ligament ossifications (2.8 %) and 16 incomplete (5.6 %). Natsis *et al.* (2014) in 145 skulls, reported the presence of the pterygoalar ligament in 46 skulls (31.7 %), but only in 6 skulls were the foramen complete (4.1 %), in 4 unilaterally (2.7 %), and in 2 bilaterally (2.7 %). Jansirani *et al.* reported complete ossification in the pterygoalar ligament in 5 skulls (2.45 %) and in 8 skulls the incomplete form (3.92 %). Skrzat *et al.* (2005), analyzed 70 dry human skulls, and noted in only 5 the pterygoalar foramen, all unilateral, and positioned medial, lateral, and crossing the oval foramen.

Singh & Niranjana noted that in Lemurs the position of the ossified bar (ossified ligament) is medial to the foramen ovale and in anthropoids lateral to the foramen ovale. In B & K the complete formation by ossification of the

pterygoalar ligament occurred in only 1 of the skulls, and most of the incomplete formations occurred on the left side in 51.72 % of the cases and without measurements of their findings. Iwanaga *et al.* reported the occurrence of the pterygoalar ligament in 16 out of 30 of their specimens (53 %), 11 cases being the type I ligament and 5 ligaments classified as type II by the authors. In this study, the occurrence of a complete pterygoalar foramen was bilateral and in one of the 45 specimens evaluated (2.2 %). Both foramen variants were lateral to the foramen ovale. As for dimensions, Skrzat *et al.* reported that the fully ossified ligament ranged from 4 to 8 mm, while the diameter of the pterygoalar foramen ranged from 7 to 11 mm.

Tubbs *et al.* reported an area of 9.42 mm² for a pterygoalar foramen. Jansirani *et al.* reported, for the ossified ligament, mean length of 6.3 mm and mean width of 3.1 mm, and for the pterygoalar foramen, the authors reported 3.2 mm in the horizontal dimension of the foramen and 2.7 mm in the vertical dimension. Suazo *et al.* identified a maximum diameter of 5.2 mm and a minimum diameter of 3.79 mm in totally formed pterygoalar foramen. Touska *et al.* in an extensive retrospective review of 240 computed tomography, identified a mean thickness of 1.2 mm for the pterygoalar calcified ligament, and a mean diameter of 13.3 mm² for the pterygoalar foramen. In our results, the areas found for the right and left pterygoalar foramen were 9.9 mm² and 6.5 mm², respectively.

CONCLUSIONS

Knowledge of the processes of ossification and/or heterotopic calcification of ligamentous or non ligamentous fibrous structures, whether of atavistic or non origin, is important for diagnosis and effective surgical approaches. Pterygospinous and pterygoalar foramen, due to their close relations with anatomotopographic territories of high neurovascular complexities, such as the infratemporal fossa and, by extension, the associated fascial spaces, require studies that can disseminate them more extensively and establish a fruitful correlation of phylogenetic basis.

OLIVEIRA, K. M.; DE ALMEIDA, V. L.; LÓPEZ, C. A. C.; BRANDÃO, G. T.; TRANCOSO, M. G. B., OLIVEIRA, M. F. S.; MORAIS, I. C. L., SOARES, D. C. B. & COSTA, L. C. M. El foramen pterigoespinoso (civinini) y el pterigoalar (*Crotaphitico-buccinatorius*) Hallazgos de laboratorio. *Int. J. Morphol.*, 39(1):198-204, 2021.

RESUMEN: El foramen pterigoespinoso y el foramen pterigoalar (*crotaphitico-buccinatorius*) son formaciones variantes y atávicas de la base del cráneo y surgen respectivamente de osificaciones idiopáticas completas o incompletas, de los ligamentos pterigoespinoso y pterigoalar. Debido a la proximidad con áreas

de relevancia para el diagnóstico y la cirugía, como las vías de acceso a los espacios parafaríngeo y retrofaríngeo, es necesario conocer estas condiciones por las dificultades que se generan en las maniobras quirúrgicas. Este estudio se realizó en 45 muestras de cráneos secos y huesos esfenoides desarticulados pertenecientes a la colección de la Universidad Federal de Juiz de Fora, campus Governador Valadares, Minas Gerais, Brasil. Nuestros resultados indicaron una incidencia total de foramen pterigoespinoso y pterigoalar completo e incompleto (*crotaphitico-buccinatorius*) en el 15,5 % (7 cráneos), con una mayor incidencia de la forma incompleta de foramen pterigoespinoso (agujero de Civinini) en 4 cráneos (8,8 %), con 3 de presentación unilateral y 3 de presentación bilateral. El foramen pterigoalar (*crotaphitico-buccinatorius* o Hyrtl) se observó bilateralmente en 1 de los cráneos (2,2 %). El foramen pterigoespinoso y pterigoalar son hallazgos importantes, a veces incidentales, de un área de gran expresividad anatómica y ocurrencias patológicas, además de los estudios indispensables y poco claros de orden filogenético.

PALABRAS CLAVE: Ligamento pterigoespinoso; Ligamento pterigoalar; Foramen oval y poro *crotaphitico-buccinatorius*.

REFERENCES

- Al-Khatib, M. *Die pterygospinösen strukturen beim menschen und anderen primaten*. Würzburg, Institut für Anatomie und Zellbiologie, Universität Würzburg, 2006.
- B, K. K. & K, V. Anatomical study of pterygospinous and pterygoalar bar in human skulls with their phylogeny and clinical significance. *J. Clin. Diagn. Res.*, 8(9):AC10-3, 2014.
- Cappello, F.; Gerbino, A. & Zummo, G. Giovanni Filippo Ingrassia: A five-hundred year-long lesson. *Clin. Anat.*, 23(7):743-9, 2010.
- Chouké, K. S. On the incidence of the foramen of Civinini and the porus crotaphiticobuccinatorius in American whites and Negroes; observations on 1544 skulls. *Am. J. Phys. Anthropol.*, 4(2):203-26, 1946.
- Costea, C.; Turluc, S.; Cucu, A.; Dumitrescu, G.; Caraleanu, A.; Buzduga, C.; Sava, A.; Costache, I. & Turluc, D. The "polymorphous" history of a polymorphous skull bone: the sphenoid. *Anat. Sci. Int.*, 93(1):14-22, 2018.
- Erdogmus, S.; Pinar, Y. & Celik, S. A cause of entrapment of the lingual nerve: ossified pterygospinous ligament – a case report. *Neuroanatomy*, 8:43-5, 2009.
- Goyal, N. & Jain, A. An anatomical study of the pterygospinous bar and foramen of Civinini. *Surg. Radiol. Anat.*, 38(8):931-6, 2016.
- Henry, B. M.; Pe, kala, P. A.; Fra, czech, P. A.; Pe, kala, J. R.; Natsis, K.; Piagkou, M.; Tomaszewski, K. A. & Tomaszewska, I. M. Prevalence, morphology, and morphometry of the pterygospinous bar: a meta-analysis. *Surg. Radiol. Anat.*, 42(5):497-507, 2020.
- Isolan, G. R. & Al-Mefty, O. Fossa infratemporal: microanatomia e abordagens cirúrgicas. *J. Bras. Neurocir.*, 19(1):7-18, 2008.
- Iwanaga, J.; Clifton, W.; Dallapiazza, R. F.; Miyamoto, Y.; Komune, N.; Gremillion, H. A.; Dumont, A. S. & Tubbs, R. S. The pterygospinous and pterygoalar ligaments and their relationship to the mandibular nerve: Application to a better understanding of various forms of trigeminal neuralgia. *Ann. Anat.*, 229:151466, 2020.
- Jansirani, D. D.; Mugunthan, N.; Anbalagan, J.; Sudha, R. & Shivadeep, S. A study on ossified pterygospinous and pterygoalar ligaments in Indian skulls. *Natl. J. Basic Med. Sci.*, 3(2):103-8, 2012.
- Komune, N.; Matsuo, S. & Nakagawa, T. The fascial layers attached to the skull base: a cadaveric study. *World Neurosurg.*, 126:e500-e509, 2019.

- Natsis, K.; Piagkou, M.; Skotsimara, G.; Totlis, T.; Apostolidis, S.; Panagiotopoulos, N. A. & Skandalakis, P. The ossified pterygoalar ligament: an anatomical study with pathological and surgical implications. *J. Craniomaxillofac. Surg.*, 42(5):e266-70, 2014.
- Rosa, R. R.; Faig-Leite, H.; Faig-Leite, F. S.; Moraes, L. C.; Moraes, M. E. L. & Filho, E. M. Radiographic study of ossification of the pterygospinous and pterygoalar ligaments by the hirtz axial technique. *Acta Odontol. Latinoam.*, 23(1):63-7, 2010.
- Ryu, S. J.; Park, M. K.; Lee, U. Y. & Kwak, H. H. Incidence of pterygospinous and pterygoalar bridges in dried skulls of Koreans. *Anat. Cell Biol.*, 49(2):143-50, 2016.
- Saran, R. S.; Ananthi, K. S.; Subramaniam, A.; Bajali, M. T.; Vinaitha, D. & Vaithianathan, G. Foramen of Civinini: a new anatomical guide for maxillofacial surgeons. *J. Clin. Diagn. Res.*, 7(7):1271-5, 2013.
- Shapiro, R. & Robinson, F. The foramina of the middle fossa: a phylogenetic, anatomic and pathologic study. *Am. J. Roentgenol. Radium Ther. Nucl. Med.*, 101(4):779-94, 1967.
- Singh, A. K. & Niranjana, R. Study of pterygospinous and pterygoalar bars in relation to foramen ovale in dry human skulls. *Natl. J. Clin. Anat.*, 8(3):97-100, 2019.
- Skrzat, J.; Walocha, J.; & Srodek, R. An anatomical study of the pterygoalar bar and the pterygoalar foramen. *Folia Morphol. (Warsz.)*, 64(2):92-6, 2005.
- Somayaji, K.; Rao, M. & Somayaji, N. Anatomical and clinical significance of Pterygospinous and Pterygoalar ligaments and bony bars in dentistry. *J. Oral Res.*, 8(1):82-90, 2019.
- Suazo, G. I.; Zavando, M. D. & Smith, R. L. Anatomical study of the pterygospinous and pterygoalar bony bridges and foramina in dried crania and its clinical relevance. *Int. J. Morphol.*, 28(2):405-8, 2010.
- Touska, P.; Hasso, S.; Oztek, A.; Chinaka, F. & Connor, S. E. J. Skull base ligamentous mineralisation: evaluation using computed tomography and a review of the clinical relevance. *Insights Imaging*, 10:55, 2019.
- Tubbs, R. S.; May Jr., W. R.; Apaydin, N.; Shoja, M. M.; Shokouhi, G.; Loukas, M. & Cohen-Gadol, A. A. Ossification of ligaments near the foramen ovale: an anatomic study with potential clinical significance regarding transcranial approaches to the skull base. *Neurosurgery*, 65(6 Suppl.):60-4, 2009.
- von Lüdinghausen, M.; Kageyama, I.; Miura, M. & AlKhatib, M. Morphological peculiarities of the deep infratemporal fossa in advanced age. *Surg. Radiol. Anat.*, 28(3):284-92, 2006.
- Yadav, A.; Kumar, V. & Niranjana, R. Pterygospinous Bar and foramen in the adult human skulls of North India: its incidence and clinical relevance. *Anat. Res. Int.*, 2014:286794, 2014.

Corresponding author:

Kennedy Martinez de Oliveira
Department of Basic Life Sciences
Federal University of Juiz de Fora
São Paulo Street 745
Governador Valadares
CEP 35010-180, Minas Gerais
BRAZIL

E-mail: kennedy.martinez@gmail.com

Received: 29-06-2020

Accepted: 08-07-2020