

Morphometric Analyses of the Caroticoclinoid and Interclinoid Foramina: A Study in Brazilian Dry Skulls

Análisis Morfométricos del Foramen Caroticoclinoideo e Interclinoideo:
Un Estudio en Cráneos Secos Brasileños

Kennedy Martinez de Oliveira¹; Valério Landim de Almeida¹; Gabriel das Chagas Benevenuto²; Gustavo Maia de Faria²; Ana Clara Camillato e Silva²; Thayná Cristina Ferreira Costa³; Daniel Gonçalves de Oliveira²; Leonardo Braga Bueno²; Pedro Lucas Rodrigues²; Marcos Túlio Castro Peixoto²; Talita Cardoso Gomes²; Maísa de Fátima Satiro Oliveira⁴; Giuliano Roberto Gonçalves⁵ & Leandro Henrique Grecco⁶

DE OLIVEIRA, K. M.; DE ALMEIDA, V. L.; BENEVENUTO, G. C.; DE FARIA, G. M.; SILVA, A. C. C.; COSTA, T. C. F.; DE OLIVEIRA, D. G.; BUENO, L. B.; RODRIGUES, P. L.; PEIXOTO, M. T. C.; GOMES, T. C.; OLIVEIRA, M. F. S.; GONÇALVES, G. R. & GRECCO, L. H. Morphometric analyses of the caroticoclinoid and interclinoid foramina: A study in Brazilian dry skulls. *Int. J. Morphol.*, 39(5):1345-1352, 2021.

SUMMARY: The caroticoclinoid (CF) and the interclinoid (IF) foramina are variant formations of the middle cranial fossa, which result from idiopathic and possibly atavistic ossifications of the caroticoclinoid and interclinoid ligaments, respectively. Topographically, these foramina are intimately associated, to varying degrees, depending on their conformations, with the neurovascular elements of the paraclinoid region and have important clinical and surgical significance. Thus, this study, conducted from 38 dry skulls belonging to the shared collection of the Federal University of Juiz de Fora, Governador Valadares campus, revealed 11 skulls (28.95 %) with one of the two complete formations - the caroticoclinoid or the interclinoid, and in 6 skulls the caroticoclinoid foramen occurred uni or bilaterally. As a result, 50 % of these skulls presented the CF exclusively on the right (or 62.5 % of the total number of variant foramina), with an average transverse diameter of 4.91 mm and 5.8 mm AP (anteroposterior) diameter and an average area of 22.5 mm². Concerning the IF, the findings occurred in 5 skulls with variable distributions between the clinoid processes and lateralities. The average length of the bone bridges in the IF was 7.7 mm. In conclusion, detailed anatomical knowledge of the caroticoclinoid and the interclinoid foramina is fundamental to the practice of neurosurgical procedures, since they have intimate relationships at a location of high structural complexity.

KEY WORDS: Caroticoclinoid and surgery; Caroticoclinoid foramen and caroticoclinoid ligament.

INTRODUCTION

The ossifications of the skull base is a complex process that begins in the fourth week of gestation from the neural crest cells and mesoderm. As the ossification of the lesser wing of the sphenoid bone, it occurs between the 17th and 18th week of intrauterine life and continues after birth until two years of age (Beger *et al.*, 2020). The lesser wing of the sphenoid bone is a reference for neurosurgical procedures and presents, at its extremity, the anterior clinoid process (ACP) (Isolan *et al.*, 2020; Prathiba *et al.*, 2020; Singh *et al.*, 2021). The ACP is a posteromedial bony projection of the lesser wing of the sphenoid bone and the

lateral wall of the optic canal, having three fixations: one medial, to the sphenoid plane, one laterally, on the lesser wing of the sphenoid bone and one inferomedial, forming the optic strut (Chaddad-Neto *et al.*, 2020). Additionally, it is possible to divide the ACP into four distinct areas - the medial, lateral, superior, and posterior triangle (Xu *et al.*, 2020).

The medial clinoid process (MCP) is a small and variable bony structure in humans, with distinct dimensions and located anterolaterally to the sella turcica and at the transition from the cavernous part of the ICA (medial to the

¹ Department of Basic Life Sciences, Federal University of Juiz de Fora, Minas Gerais, Brazil.

² Faculty of Medicine, Federal University of Juiz de Fora, Minas Gerais, Brazil.

³ Faculty of Odontology, Federal University of Juiz de Fora, Minas Gerais, Brazil.

⁴ Faculty of Medicine, Federal University of Minas Gerais, Minas Gerais, Brazil.

⁵ School of Medicine, São Leopoldo Mandic, São Paulo, Brazil.

⁶ São Leopoldo Mandic Institute and Research Center, Brazil.

anterior syphon knee) to the paraclinoid part of the ICA (Sharma *et al.*, 2019).

The posterior clinoid process (PCP) is situated posteriorly to the roof of the cavernous sinus, on the superior and lateral faces of the dorsum of the sella turcica (Isolan *et al.*). These clinoid processes are connected by ligaments under folds of the cranial dura mater and are subject to ossification with formation of foramina - caroticoclinoid and interclinoid (Fig. 1).

In the sphenoid bone, in addition to the intracranial ligaments, the petrosphenoid, the caroticoclinoid (CL) and the interclinoid, there are variant and atavistic extracranial ligamentous formations that are also subject to ossification - the pterygospinous ligament and the pterygoalar ligament (de Oliveira *et al.*, 2021).

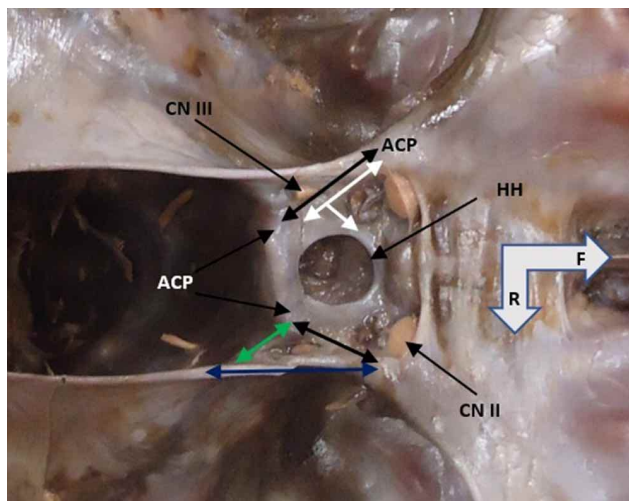


Fig. 1. The interface between the anterior and middle cranial fossa and their dura mater topographies. The bilateral double black arrows indicate the interclinoid folds, related in depth to the interclinoid ligaments, the green arrow is overlapping the posterior petroclinoid fold and the underlying petrosphenoidal ligament, the blue arrow is overlapping the anterior petroclinoid fold and its ligament, the white arrow is overlapping, through the dura mater, to the caroticoclinoid ligament. ICA (internal carotid artery), HH (hypophyseal hiatus), ACP (anterior clinoid process), PCP (posterior clinoid process), CN II (II cranial nerve pair), CN III (III cranial nerve pair). The triangular configuration between the anterior and posterior petroclinoid folds and the interclinoid fold is the oculomotor nerve trigone. F (frontal) and R (right).

The objective of this study is to indicate the incidence of the caroticoclinoid foramen (CF) - or caroticoclinoid canal (CC) - and the interclinoid foramen (IF) in the collection of dried human skulls from the Federal University of Juiz de Fora - Governador Valadares campus, as well as their morphometric characteristics and the principal clinical and surgical repercussions attributed to these variations.

MATERIAL AND METHOD

We analyzed 38 skulls from the shared collection of the Human Anatomy laboratory of the Federal University of Juiz de Fora, Governador Valadares campus (UFJF-GV) throughout 2019. Analyses were conducted under ambient light, with unaided vision and with the use of morphometric techniques by using a digital pachymeter (Western Pro), resolution 0.1 mm, Rhosse® stainless steel millimeter ruler and JON® stainless steel dry point compass. All were evaluated by direct cranioscopy and by a unique examiner from the CF and IF perspective, considering the microregional integrity of the paraclinoid region and the typical structural conformation of a natural and complete (closed) foramen - incomplete forms were not considered in this study. None of the specimens were identified as to sex and/or age.

The literature search was performed in the Medical Literature Analysis and Retrieval System Online (Medline / Pubmed) databases. We used the descriptors "caroticoclinoid", "caroticoclinoid and surgery", "anterior clinoid process and anatomic variation", "sphenoid bone and surgery", "caroticoclinoid canal", "caroticoclinoid foramen" and "caroticoclinoid ligament". The descriptors "surgery", "sphenoid bone" and "anatomic variation" were indexed in Medical Subject Heading Terms (MeSH), while the others were inserted due to relevance to the study. Studies in the temporal space from 2017 to 2021, available in digital media and in the English language, beyond that a historical reference were included.

RESULTS

From the analysis of 38 skulls in the collection, all mesocephalic, it was observed that 11 (28.95 %) presented at least one of the two formations - the CF (or CC) and the IF, complete, simultaneous in some finds (3 occurrences in a total of 16 formations) and with variable conformations as to diameters, lengths and areas. Thus, the CF, typically formed by a osseous bridge between the anterior and middle clinoid processes (Fig. 2), was found in 6 skulls (8 foramina) with the following distributions: in 2 skulls the canal occurred bilaterally, in one skull the occurrence was on the left, and in the next three skulls the occurrences were on the right laterality. Therefore, the incidence of CF on the right side was 62.5 %, considering the total of the 8 unilateral and bilateral formations. In relation to right unilateral variation, the occurrence was 50 % in the 6 skulls (Table I). Here we did not consider the CF formations associated with IF (3 findings).

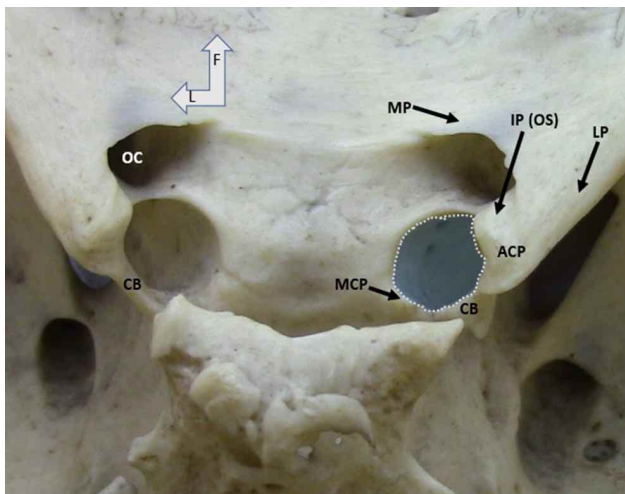


Fig. 2. Right unilateral occurrence of the complete caroticoclinoid bone bar (CB) with the blue oval circle. MCP (middle clinoid process), ACP (anterior clinoid process) and their fixations: IP/OS (inferior pillar / optic strut), LP (lateral pillar), MP (medial pillar). OC (optic canal). F (frontal) and L (left).

Table I. Absolute (FI) and relative (RF) frequencies according to the presence or absence of the CF in skulls from the collection of the authors. ACP - anterior clinoid process, MCP - middle clinoid process.

Caroticoclinoid foramen (CF)	Absolute Frequency (FI)	Relative Frequency (RF)
Bilateral	2 ACP/MCP	33.33 %
Unilateral left	1 ACP/MCP	16.66 %
Unilateral right	3 ACP/MCP	50 %
Total	6 skulls (8 foramina)	100.00 %

The T diameter (transverse) of each of the foramen was measured from the internal margin of the anterior clinoid process to the base of the middle clinoid process (Fig. 3), with an average of 4.91 mm; the foramina on the right had an average of 4.84 mm, and the foramina on the left had an average of 5.03 mm (Table III).

As for the AP (anteroposterior) diameter, the measurement was made from the central portion of the inferior margin of the optic canal to the internal margin of the bone bar between the anterior and middle clinoid processes (Fig. 3), with an average of 5.82 mm, and the right foramina had an average of 5.68 mm, and the left foramina had an average of 6.07 mm (Table III).

The resulting area of the CFs was, by Radinsky's formula ($\pi \times w \times h / 4$), on average, 22.5 mm² with the right-located foramina averaging 21.6 mm² and the left-located foramina 24.1 mm². As for the IF (Fig. 4), the

findings occurred in 5 skulls with the following distributions: 3 skulls with bilateral formations (in two the bone bridges occurred bilaterally between the three clinoid processes, and, in the third skull, the bridge extended between the anterior and posterior clinoid processes) - thus, an association between the IF and the CF (not treated morphometrically). In one of the skulls, the IF occurred on the left, between the three clinoid processes, and in the fifth skull, the osseous bridge connected the ACP to the PCP (Table II).

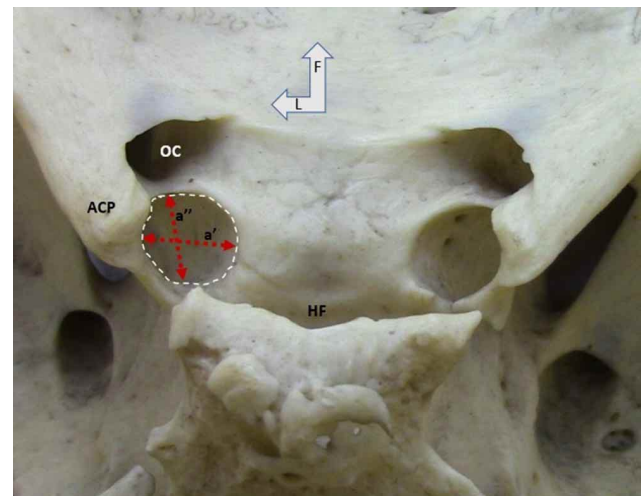


Fig. 3. Complete right caroticoclinoid foramen with the representations of the measures a' (transverse diameter) and a'' (AP - anteroposterior diameter). ACP (anterior clinoid process), HF (hypophyseal fossa), OC (optic canal). F (frontal) and L (left).

Table II. Absolute (FI) and relative (RF) frequencies according to the presence or absence of IF in skulls from the collection of the authors. ACP - anterior clinoid process, MCP - middle clinoid process, and PCP - posterior clinoid process.

Interclinoid	Absolute Frequency (FI)	Relative
Bilateral	2 ACP/MCP/PCP + 1	60 %
Unilateral left	1 ACP/MCP/PCP	20 %
Unilateral right	1 ACP/PCP	20 %
Total	5 skulls (8 foramina/bone bars)	100.00 %

The incidence of IF for the right and left antimeres, considering the formations in the 5 skulls (8 foramina), was 50 %, and in 60 % of these skulls the incidence was bilateral. The average length of the osseous bridge from the ACP to the PCP was 7.7 mm, as indicated in Figure 3 and Table IV. The standard deviation (SD) of the AP diameter, T diameter, and CF area were 0.53 mm, 0.42 mm, and 3.43 mm², respectively, while the SD of the ACP / PCP bone bar length was 0.51 mm (Table III).

Table III. Morphometrics of the variant skulls for CF (caroticoclinoid foramen); 01 (skull 01), 02 (skull 02), 03 (skull 03), 04 (skull 04), 05 (skull 05) and 06 (skull 06). SD (standard deviation). Area: Radinsky formula ($\pi \times w \times h / 4$).

Caroticoclinoid foramen (CF)	Location	Diameter AP	Diameter T	Area
CF01	right	5.7 mm	5.4 mm	24.2 mm ²
CF01	left	5.1 mm	4.6 mm	18.4 mm ²
CF02	right	5.6 mm	5.1 mm	22.4 mm ²
CF02	left	6.4 mm	5.4 mm	27.1 mm ²
CF03	left	6.7 mm	5.1 mm	26.8 mm ²
CF04	right	5.4 mm	4.7 mm	19.9 mm ²
CF05	right	6.1 mm	4.8 mm	23.0 mm ²
CF06	right	5.6 mm	4.2 mm	18.5 mm ²
6 skulls / 8 foramina	5 rights and 3 lefts	Average: 5.82 mm (R = 5.68 and L = 6.07) SD = 0.53mm	Average: 4.91 mm (R = 4.84 and L = 5.03) SD = 0.42mm	Average: 22.5 mm ² (R = 21.6 mm ² and L = 24.1 mm ²) SD = 3.43mm ²

Table IV. Morphometrics of the variant skulls for the IF (Interclinoid foramen). 01 (skull 01), 02 (skull 02), 03 (skull 03), 04 (skull 04) and 05 (skull 05). ACP - anterior clinoid process and PCP - posterior clinoid process. SD (standard deviation).

Interclinoid Forame (IF)	Location	Bone bar Length
FI01	right	8.0 mm
FI01	left	7.5 mm
FI02	right	7.5 mm
FI02	left	7.7 mm
FI03	left	8.5 mm
FI03	right	8.0 mm
FI04	right	6.75 mm
FI05	left	7.7mm
5 skulls / 8 foramina	4 rights and 4 lefts	Average: 7.7 mm SD = 0.51 mm

DISCUSSION

The development of the sphenoid bone occurs from the endochondral ossification of the sphenoid body during the first trimester, a process regulated by matrix Gla proteins and osteopontin. The physiological understanding of this mechanism has still not been elucidated, in view of the complexity and high variability of the genetic control of these ossification centers (Skandalakis *et al.*, 2019).

The caroticoclinoid ligament (CL), which extends from the ACP to the MCP, when identified in human skulls, is frequently ossified, and, as a result of this anatomical variation between the clinoid processes, there is the formation of the CF (Jha *et al.*, 2017; Zhao *et al.*, 2020).

The CF varies in incidence and morphology and constitutes the anterior part of the cavernous sinus roof. The first mention in the literature about the CF was published in 1855 by Friedrich Gustav Jakob Henle, a German pathologist and anatomist, and it is generally categorized as "complete" or "incomplete" (Henle, 1855; Skandalakis *et al.*).

The IF occurs by ossification of the interclinoid ligament, existing between the ACP and PCP and occasionally between the MCP and PCP (JaiSankar *et al.*, 2019; Bayrak *et al.*, 2019; Touska *et al.*, 2019). Although age has been pointed out as the factor responsible for the ossification of the CL, predominantly in individuals more than 50 years old, CF has also been found in embryos and

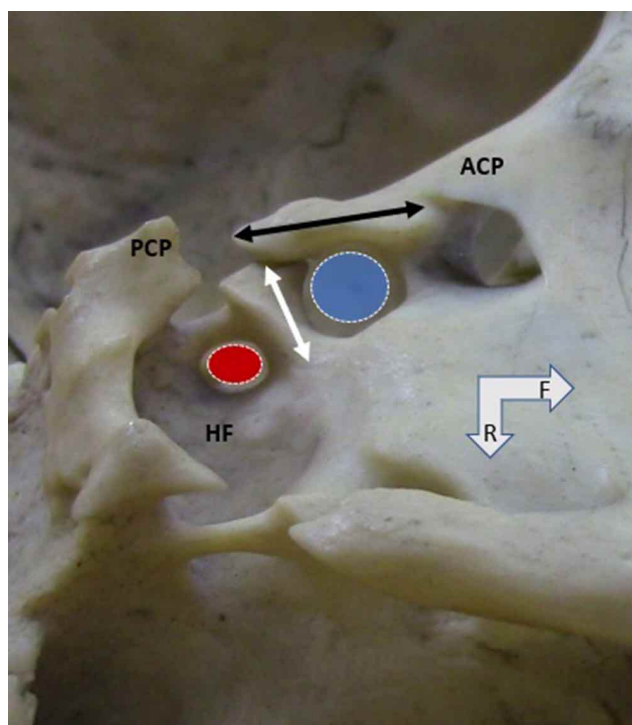


Fig. 4. Left unilateral interclinoid foramen involving the anterior (ACP), middle, and posterior clinoid processes (PCP). Double black arrow positioned on the interclinoid bone bar and double white arrow on the caroticoclinoid bone bar. Blue oval circle at the caroticoclinoid foramen and red oval circle at the interclinoid foramen. F (frontal) and R (right).

newborns, revealing that the formation of this structure is not completely age-dependent (Skandalakis *et al.*).

The anterior clinoidectomy is the ideal procedure for the management of pathologies that present in the paraclinoid region, especially because of the greater exposure and visualization of the surgical area and the decreased retraction of the brain that the removal of the ACP provides. Some of the conditions that require ACP removal are: paraclinoid aneurysms in both the ICA and the ophthalmic artery, cavernous sinus meningiomas, giant pituitary adenomas, and aneurysms at the apex of the basilar artery and the posterior communicating artery (Beger *et al.*; Chaddad-Neto *et al.*; Xu *et al.*; Skandalakis *et al.*).

As for the middle clinoidectomy, it can be requested in craniopharyngiomas, meningiomas, and pituitary adenomas (Skandalakis *et al.*). The posterior clinoidectomy, however, is required to remove barriers that may obstruct access, via endoscopy, to the prepontine and interpeduncular cistern lesions (Rejane-Heim *et al.*, 2021). Nevertheless, anterior clinoidectomy is associated with several surgical risks, such as visual disturbances, oculomotor nerve palsy, opening of the cavernous sinus and hemorrhages from ICA injuries, rupture of the ophthalmic artery, fistulous communications from the sinuses to the cerebrospinal fluid, and the potentially fatal course of meningitis (Prathiba *et al.*; Chaddad-Neto *et al.*; Jha *et al.*). Among these complications, optic nerve lesion is the most common. In this sense, the presence of these bone rings implies a medial fixation of the ACP, complicating anterior clinoidectomy and increasing the risk of injury to adjacent structures (Prathiba *et al.*; Jaisankar *et al.*; Skandalakis *et al.*; Touska *et al.*). As for ICA pathologies, the presence of CF impairs mobilization of the cavernous segment and can compress it, possessing considerable clinical significance (Efthymiou *et al.*, 2018; Prathiba *et al.*). In addition, there is a necessity for other maneuvers to access aneurysms in the ICA when the CF and IF are present, which increases the risk of a vascular rupture. Other repercussions of these variations include difficulties in removing central tumors, identification of the MCP - commonly used as an anatomical reference during nasal endoscopies to access the hypophysis gland - and diagnostic difficulties by professionals unaccustomed to ligament ossifications when conducting angiographies (Touska *et al.*).

Therefore, knowledge and anatomical study of the CF and IF are essential for surgical planning. The conventional and two-dimensional CT scans may not detect the presence of CF, so coronal and three-dimensional thin-section reconstructions are necessary, especially on axial sections at the level of the upper parasellar region. Thus, the

surgeon should be attentive even if the canal is not detected in these exams and, if it is identified, should prioritize the anterior intradural compared to extradural clinoidectomy, because it offers better visualization and lesser risk of injury to the ICA (Skandalakis *et al.*; Jean, 2019). Besides surgical obstacles, the presence of the canal can compress or tension the ICA, with possible alteration in cerebral blood circulation (Singh). In addition, the IF may be a potential cause of trigeminal neuralgia (Bayrak *et al.*).

The present study demonstrated an incidence of ligamentary ossifications between the clinoid processes of 28.95 % (11:38) in the skulls evaluated, disregarding the age and the sex, and of the 11 skulls, the CF formation occurred in 54.54 % (6:11) and the IF in 45.45 % (5:11). Touska *et al.* evaluated 240 skulls using Computed Tomography (CT) and identified the CF in 17.5 % of them (42:240), of which 25 (59.5 %) were bilateral, and of these 60 % (15:25) were complete, 24 % (6:25) were mixed - complete on one side and incomplete on the other, and 16 % (4:25) were incomplete, and of the unilateral ones (17:42), 52.9 % (9:17) were complete and 47.1 % (8:17) were incomplete.

In addition, 53 (22.1 %) of the 240 skulls presented the IF, with 24 (45.3 %) being bilateral, of which 29.2 % (7:24) were complete, 12.5 % (3:24) mixed and 58.3 % (14:24) incomplete, and 29 (54.7 %) being unilateral, with 20.7 % (6:29) of them complete and 79.3 % (23:29) incomplete. Both formations, CF and IF, have been found in skulls of all ages. The author found an average thickness and length of 1.8 mm (SD = 0.8 mm) and 25.3 mm (SD = 4.4 mm) in CFs and 1.8 mm (SD = 0.5 mm) and 75.2 mm (SD = 22 mm) in IFs, respectively. The thickness measurements were not recorded in this study in the CF or the IF, but the average length of the osseous bridge from the ACP to the PCP (bone bar of the IF) was 7.7 mm (SD = 0.51 mm).

Jaisankar *et al.*, identified the CF in 29 (58 %) of the 50 skulls evaluated, although none of them presented complete conformation, with 16 of them (32 %/55.2 % - 16:50/16:29) unilateral and 13 (26 %/44.8 % - 13:50/13:29) bilateral. On the other hand, the author did not locate the IF in the skulls in question. As for the left CFs, the average vertical length and transverse length were 5.237 mm (SD = 1.121 mm) and 6.393 mm (SD = 2.159 mm), respectively, in the male skulls and 5.226 mm (SD = 0.630 mm) and 5.862 mm (SD = 1.599 mm) in the female skulls. On the right side, the CF presented average vertical length and transverse length of 4.435 mm (SD = 1.001 mm) and 4.669 mm (SD = 1.660 mm) in male skulls, respectively, and 4.719 mm (SD = 0.959 mm) and 4.193 mm (SD = 1.706 mm) in female skulls.

In the present study, only complete foramina were considered, there was no distinction between female and male skulls and ages were not considered either. Thus, the incidence of CF on the right side was 62.5 % (5 of 8 formations in total - uni and bilateral). The right unilateral variation was 50 % (3 of 6 skulls). We did not consider CF formations associated with IF formations (3 findings). The left unilateral variation occurred isolated in 1:6 skulls (16.66 %) and, when associated with bilateral findings, the incidence was 50 % (3 of 6 skulls). The T-diameter averaged 4.91 mm, with right positioned foramina averaging 4.84 mm and left positioned foramina averaging 5.03 mm with SD = 0.42 mm. As for the AP (anteroposterior) diameter, we obtained an average of 5.82 mm, with the foramina positioned on the right having an average of 5.68 mm, and the foramina positioned on the left having an average of 6.07 mm, with SD = 0.53 mm.

The area of the CFs averaged 22.5 mm². with the right foramina averaging 21.6 mm² and the left foramina 24.1 mm² and SD = 3.43 mm². Bayrak *et al.*, studied 573 patients, 246 (42.9 %) women and 327 (57.1 %) men, via cone beam computed tomography to detect the presence of intracranial ligamentous ossifications, and reported 28 (4.88 %) IF findings, 16 (2.79 %/57.14 % - 16:573/16:28) of them being unilateral and 12 bilateral (2.09 %/42.86 % - 12:573/12:28). In addition, there were 22 (3.83 %) CFs, of which 6 (1.04 %/27.3 % - 6:573/6:22) were unilateral and 16 (2.79 %/72.7 % - 16:573/16:22) were bilateral.

In all, the authors identified 50 (8.72 %) foramina in the skulls evaluated and reported that there was no statistical difference according to age, sex or side where the canal was observed. On the other hand, Skandalakis *et al.*, in a meta-analysis and systematic review study of 26 works about CF, reported an overall prevalence of 32.6 % (95 % confidence interval [CI], 26.6 % and 38.8 %), being the prevalence of bilateral 41.1 % (95 % CI, 31.9 % and 50.5 %), of these 46.8 % (95 % CI, 39.4 % and 54.3 %) were complete or contact type, and unilateral 23.6 % (95 % CI, 19.7 % and 27.6 %), of these 46.0 % (95 % CI, 38.8 % and 53.2 %) were complete or contact type. Differently from the study by Bayrak *et al.*, the authors noted a statistically significant right dominance in unilateral CFs (odds ratio for right vs. left, 1.11; P ≈ 0.050).

In the work of Bansode *et al.* (2017), it was reported that, of the 35 skulls studied, only 7 (20 %) presented the CF. In these skulls, 2 (5.7 %/28.6 % - 2:35/2:7) had the complete bilateral CF, 2 (5.7 %/28.6 % - 2:35/2:7) complete right unilateral, 2 (5.7 %/28.6 % - 2:35/2:7) incomplete, in right unilateral and 1 (2.8 %/14.3 % - 1:35/1:7) incomplete left unilateral.

The incidence of ossification of the caroticoclinoid ligament was consequently 12.8 % (9:70), with 8.57 %/66.7 % (6:70/6:9) complete and 4.28 %/33.3 % (3:70/3:9) incomplete. Similarly to Skandalakis *et al.*, who identified right dominance with respect to the unilateral presence of the CF. According to Efthymiou *et al.*, of the 76 adult human skulls analyzed, 56 (74 %) of them had the CF. The bilateral occurrence was 51.3 %/69.6 % (39:76/39:56) and only 17 (22.3 %/30.4 % - 17:76/17:56) skulls had the CF unilaterally, with limited right dominance of 53 % (9:17). Independent of sex or age, the CF was incomplete in 69.6 % (39) of the findings, complete in 19.6 % (11), and of contact in 10.7 % (6).

The average transverse diameter of CFs was 5.500 mm (SD = 0.700 mm) on the left side and 5.400 mm (SD = 0.800 mm) on the right. Jha *et al.*, conducted a study on CF in 108 adult human skulls. The authors observed that CF was present in 24 (22.22 %). Of these, 15 (62.5 %) were unilateral - with left dominance, what differs from the other studies, and only 9 (37.5 %) were bilateral. The incomplete CF type was more prevalent, present in 14 %/62.5 % (15:108/15:24) of the skulls, against 8.3 %/37.5 % (9:108/9:24) complete. Prathiba *et al.*, studied, in 100 dry human skulls, the presence of the CF and CL. Of these, only 12 (12 %) presented ossified CL and CF, and 7 %/58.3 % (7:100/7:12) were on the left side and 5 %/41.7 % (5:100/5:12) on the right side. This study also evaluated the anteroposterior, transverse CF diameters. As a result, the average anteroposterior and transverse diameters were 5.35 mm (SD = 0.3 mm) and 5.09 mm (SD = 0.16 mm), respectively, on the right side, and 4.49 mm (SD = 0.28 mm) and 5.41 mm (SD = 0.17 mm), on the left side. The maximum anteroposterior diameter on the right side was 5.83 mm, being greater than on the left side, with 4.54 mm. The maximum transverse diameter on the right side was 5.30 mm, showing to be smaller than the left side with 5.57 mm. Table V summarizes recent works, including the present study, as regards the incidences of caroticoclinoid (CF) and interclinoid (IF) foramina.

CONCLUSION

The incidence of ligament ossifications - CF and IF, in the present study, differs from the findings of other publications, which is expected in view of the different human groups investigated. However, studies demonstrate a considerable prevalence of CF and IF and the necessity of detailed knowledge of their possible morphologies and morphometry in order to prevent surgical complications. Thus, studies are still needed to completely understand these variations and their clinical and epidemiological relevance.

Table V. Recent studies on anatomical findings of the CF (caroticoclinoid) and IF (interclinoid) foramen. * The study by Touska *et al.* (2019) was conducted in 62.5 % white British/European, 18.3 % black British/African and Caribbean, 11.3 % Indian and 7.9 % other ethnic groups. ** Meta-analysis study.

Author	Population	Year	Specimens	Findings
Touska <i>et al.</i>	British *	2019	240	42 skulls (17.5%) presented CF and 53 (22.1%) the IF.
Jaisankar <i>et al.</i>	Indian	2019	50	29 skulls (58%) presented CF and none the IF.
Bayrak <i>et al.</i>	Turkish	2019	573	22 skulls (3.83%) presented CF and 28 (4.88%) the IF.
Skandalakis <i>et al.</i>	Non-specified **	2019	Meta-analysis of 26 studies	CF prevalence in 32.6% (95% confidence interval [CI], 26.6% and 38.8%).
Bansode <i>et al.</i>	Indian	2017	35	In 35 skulls only 7 (20%) presented the CF.
Jha <i>et al.</i>	Indian	2017	108	24 skulls presented CF with a prevalence of 22.22% (108 skulls in total).
Efthymiou <i>et al.</i>	Greek	2018	76	In 76 skulls studied, CF was present in 56 (74%).
Prathiba <i>et al.</i>	Indian	2020	100	Analyzed 100 skulls, 12 showed CF with a prevalence of 12%.
Present study	Brazilian	2021	38	Of the total of 11 skulls (28.95%) 6 showed the CF and the other 5 the IF.

DE OLIVEIRA, K. M.; DE ALMEIDA, V. L.; BENEVENUTO, G. C.; DE FARIA, G. M.; SILVA, A. C. C.; COSTA, T. C. F.; DE OLIVEIRA, D. G.; BUENO, L. B.; RODRIGUES, P. L.; PEIXOTO, M. T. C.; GOMES, T. C.; OLIVEIRA, M. F. S.; GONÇALVES, G. R. & GRECCO, L. H. Análisis morfométricos del foramen caroticoclinoido e interclinoido: Un estudio en cráneos secos brasileños. *Int. J. Morphol.*, 39(5):1345-1352, 2021.

RESUMEN: El foramen caroticoclinoido (FC) y el foramen interclinoido (IC) son formaciones variables de la fosa craneal media, que resultan de osificaciones idiopáticas y posiblemente atávicas de los ligamentos caroticoclinoido e interclinoido, respectivamente. Estos forámenes están íntimamente asociados topográficamente en diversos grados, dependiendo de sus conformaciones, con los elementos neurovasculares de la región paraclinoidoidea y tienen importancia clínica y quirúrgica. Así, este estudio, realizado a partir de 38 cráneos secos pertenecientes a la colección compartida de la Universidad Federal de Juiz de Fora, campus Governador Valadares, reveló 11 cráneos (28,95 %) con una de las dos formaciones completas: el FC o el IC, y en 6 cráneos el FC se presentó uni o bilateralmente. Como resultado, el 50 % de estos cráneos presentaba el FC exclusivamente a la derecha (o el 62,5 % del total de forámenes variantes), con un diámetro transversal medio de 4,91 mm y un diámetro anteroposterior medio de 5,8 mm y un área promedio de 22,5 mm². En cuanto a la FI, los hallazgos se presentaban en 5 cráneos con distribuciones variables entre los procesos clinoides y lateralidades. La longitud media de los puentes óseos en el FI fue de 7,7 mm. En conclusión, el conocimiento anatómico detallado de los forámenes caroticoclinoido e interclinoido resulta fundamental para la práctica de procedimientos neuroquirúrgicos, ya que presentan relaciones íntimas en un lugar de alta complejidad estructural.

PALABRAS CLAVE: Caroticoclinoido e cirugía; Foramen caroticoclinoido e ligamento caroticoclinoido.

REFERENCES

- Bansode, S. A.; Devadas, P. & Vinila, B. H. S. Study on the incidence of the carotico-clinoid foramen in the south indian dry adults skulls: a cross-sectional study. *Int. J. Anat. Res.*, 5:4051-5, 2017.
- Bayrak, S.; Bulut, D. G.; Çakmak, E. S., K. & Orhan, K. Cone beam computed tomographic evaluation of intracranial physiologic calcifications. *J. Craniofac. Surg.*, 30(2):510-3, 2019.
- Beger, O.; Hamzaoglu, V.; Özalp, H.; Taghipour, P.; Çakir, S.; Akbulut, S.,; Vayisoglu, Y.; Bagdatoglu, C.; Öztürk, A. H. & Talas, D. Ü. Anatomy of the anterior clinoid process in human fetuses. *J. Craniofac. Surg.*, 31(5):1469-73, 2020.
- Chaddad-Neto, F.; da Costa, M. D. S.; Santos, B.; Caramanti, R. L.; Costa, B. L.; Doria-Netto, H. L. & Figueiredo, E. G. Reproducibility of a new classification of the anterior clinoid process of the sphenoid bone. *Surg. Neurol. Int.*, 11:281, 2020.
- de Oliveira, K. M.; de-Almeida, V. L.; López, C. A. C.; Brandão, G. T.; Trancoso, M. G. B.; Oliveira, M. F. S.; Morais, I. C. L.; Soares, D. C. B. & Costa, L. C. M. The pterygospinous foramen (Civinini) and the pterygoalar (crotaphitico-buccinatorius). Laboratory Findings. *Int. J. Morphol.*, 39(1):198-204, 2021.
- Efthymiou, E.; Thanopoulou, V.; Kozompoli, D.; Kanellopoulou, V.; Fratzoglou, M.; Mytilinaios, D.; Piagkou, M. & Johnson, E. O. Incidence and morphology of caroticoclinoid foramina in Greek dry human skulls. *Acta Neurochir (Wien)*, 160(10):1979-87, 2018.
- Henle, G. J. *Handbuch der systematischen Anatomie des Menschen*. Braunschweig, Friedrich Vieweg und Sohn, 1855. pp.97-112.
- Isolan, G. R.; Braga, F. L. S.; Campero, A.; Landeiro, J. A.; de Araújo, R. M. L.; Adjer, P.; Sakaya, G. R.; Rabelo, N. N.; da Silva Brito, J.; Teixeira, M. J.; *et al.* Microsurgical and endoscopic anatomy of the cavernous sinus. *Arq. Bras. Neurocir.*, 39(2):83-94, 2020.
- JaiSankar, A. I.; Lakshmanan, G. & Thenmozhi, M. S. Occurrence of caroticoclinoid foramen and inter clinoid bar in dry human skulls and their clinical significance. *Drug Invent. Today*, 11(5):1021-6, 2019.
- Jean, W. C. How I do it: extradural clinoidectomy. *Acta Neurochir. (Wien)*, 161(12):2583-6, 2019.
- Jha, S.; Singh, S.; Bansal, R.; Chauhan, P.; Shah, M. P. & Shah, A. Nonmetric analysis of caroticoclinoid foramen in foothills of Himalayas: Its clinicoanatomic perspective. *Morphologie*, 101(332):47-51, 2017.
- Prathiba, K.; Kumari, M. K. L.; Sreekanth, C. & Srivani, D. A Study on Ossified Carotico-Clinoid Ligament in Human Skulls in Rayalaseema Zone. *IOSR J. Dent. Med. Sci.*, 19(1):30-3, 2020.

- Rejane-Heim, T. C.; Silveira-Bertazzo, G.; Carrau, R. L. & Prevedello, D. M. Surgical anatomy and nuances of the expanded endonasal transdorsum sellae and posterior clinoidectomy approach to the interpeduncular and prepontine cisterns: a stepwise cadaveric dissection of various pituitary gland transpositions. *Acta Neurochir.*, 163(2):407-13, 2021.
- Sharma, A.; Rieth, G. E.; Tanenbaum, J. E.; Williams, J. S.; Ota, N.; Chakravarthi, S.; Manjila, S.; Kassam, A. & Yapicilar, B. A morphometric survey of the parasellar region in more than 2700 skulls: emphasis on the middle clinoid process variants and implications in endoscopic and microsurgical approaches. *J. Neurosurg.*, 129(1):60-70, 2019.
- Singh, R. Carotico-clinoid foramen and associated clinical significance: comprehensive review. *Cureus*, 13(1):e12828, 2021.
- Skandalakis, G. P.; Koutsarnakis, C.; Pantazis, N.; Kalyvas, A.; Komaitis, S.; Lani, E.; Drosos, E.; Kalamatianos, T.; Hadjipanayis, C. G.; Natsis, K.; *et al.* The carotico-clinoid bar: A systematic review and meta-analysis of its prevalence and potential implications in cerebrovascular and skull base surgery. *World Neurosurg.*, 124:267-76, 2019.
- Touska, P.; Hasso, S.; Oztek, A.; Chinaka, F. & Connor, S. E. J. Skull base ligamentous mineralisation: evaluation using computed tomography and a review of the clinical relevance. *Insights Imaging*, 10:55, 2019.
- Xu, T.; Yan, Y.; Evins, A. I.; Gong, Z.; Jiang, L.; Sun, H.; Cai, L.; Wang, H.; Li, W.; Lu, Y.; *et al.* Anterior clinoidal meningiomas: meningeal anatomical considerations and surgical implications. *Front. Oncol.*, 10:634, 2020.
- Zhao, X.; Labib, M. A.; Avci, E.; Preul, M. C.; Baskaya, M. K.; Little, A. S. & Nakaji, P. Navigating a carotico-clinoid foramen and an interclinoid bridge in the endonasal endoscopic approach: an anatomical and technical note. *J. Neurol. Surg. B Skull Base*, 2020. DOI: <https://www.doi.org/10.1055/s-0040-1715470>

Corresponding author:
Kennedy Martinez de Oliveira.
Federal University of Juiz de Fora
Minas Gerais
BRAZIL

Department of Basic Life Sciences
Federal University of Juiz de Fora
São Paulo Street 745
Governador Valadares
CEP 35010-180.
Minas Gerais
BRAZIL

E-mail: kennedy.martinez@gmail.com

Received: 23-04-2021

Accepted: 11-07-2021