

Violet LED in Bleaching Non-Vital Teeth: a Case Series

LED Violeta no Clareamento de Dentes Não Vitais: uma Série de Casos

LED Violeta en el Blanqueamiento de Dientes no Vitales: una Serie de Casos

Sávio Morato de Lacerda **GONTIJO**

Department of Oral Surgery, Pathology and Clinical Dentistry, Faculty of Dentistry, Federal University of Minas Gerais (UFMG),
Belo Horizonte, Minas Gerais, Brazil
<https://orcid.org/0000-0002-7803-4345>

Fernanda Novais **ARANTES**

Department of Oral Surgery, Pathology and Clinical Dentistry, Faculty of Dentistry, Federal University of Minas Gerais (UFMG),
Belo Horizonte, Minas Gerais, Brazil
<https://orcid.org/0000-0001-5563-4914>

Ivan Doche **BARREIROS**

Department of Oral Surgery, Pathology and Clinical Dentistry, Faculty of Dentistry, Federal University of Minas Gerais (UFMG),
Belo Horizonte, Minas Gerais, Brazil
<https://orcid.org/0000-0003-4335-7846>

Juvenil Alves Neves Diniz **FERREIRA**

Department of Oral Surgery, Pathology and Clinical Dentistry, Faculty of Dentistry, Federal University of Minas Gerais (UFMG),
Belo Horizonte, Minas Gerais, Brazil
<https://orcid.org/0000-0002-4436-4776>

João Batista **NOVAES JÚNIOR**

Department of Oral Surgery, Pathology and Clinical Dentistry, Faculty of Dentistry, Federal University of Minas Gerais (UFMG),
Belo Horizonte, Minas Gerais, Brazil
<https://orcid.org/0000-0003-0502-1989>

Francisca Daniele Jardimino **SILAMI**

Department of Oral Surgery, Pathology and Clinical Dentistry, Faculty of Dentistry, Federal University of Minas Gerais (UFMG),
Belo Horizonte, Minas Gerais, Brazil
<https://orcid.org/0000-0003-4212-5322>

Abstract

Objective: The main of this study was to clinically evaluate the effectiveness of violet LED in bleaching non-vital teeth. Case series: three clinical cases were selected (1, 2 and 3), which showed changes in the colour of specific teeth to shades A2, C4 and B3, respectively. Bleaching was performed over three sessions (one session/week). Each session consisted of 20 applications of violet LED for 60 s, with a 30 s interval between them. After bleaching using violet LED, 35% hydrogen peroxide was applied for 15 min in clinical cases 2 and 3, with continuous irradiation with the violet LED in the last 5 min. The dental bleaching using violet LED resulted in teeth with shades A1, C3 and C2 in clinical cases 1, 2 and 3, respectively. The application of 35% hydrogen peroxide with the violet LED further changed the teeth to shades A2 and C1 in clinical cases 2 and 3, respectively. **Conclusions:** the protocol used in this case series showed that whitening with a violet LED alone should be restricted to cases requiring small colour changes.

Descriptors: Hydrogen Peroxide; Tooth Bleaching; Violet LED.

Resumo

Objetivo: O principal objetivo deste estudo foi avaliar clinicamente a eficácia do LED violeta no clareamento de dentes não vitais. Série de casos: foram selecionados três casos clínicos (1, 2 e 3), os quais mostraram alterações na coloração de dentes específicos para as tonalidades A2, C4 e B3, respectivamente. O clareamento dental foi realizado em três sessões (uma sessão/semana). Cada sessão constou de 20 aplicações de LED violeta por 60 s, com intervalo de 30 s entre elas. Após o clareamento com o LED violeta, foi aplicado peróxido de hidrogênio a 35% por 15 min nos casos clínicos 2 e 3, com irradiação contínua com o LED violeta nos últimos 5 min. O clareamento dental com LED violeta resultou em dentes nas cores A1, C3 e C2 nos casos clínicos 1, 2 e 3, respectivamente. A aplicação de peróxido de hidrogênio 35% com o LED violeta alterou ainda mais a coloração dos dentes, A2 e C1, nos casos clínicos 2 e 3, respectivamente. **Conclusão:** o protocolo utilizado nesta série de casos mostrou que o clareamento com apenas LED violeta deve ser restrito aos casos que requerem pequenas alterações de cor.

Descritores: Peróxido de Hidrogênio; Clareamento Dental; LED Violeta.

Resumen

Objetivo: el objetivo principal de este estudio fue evaluar clinicamente la eficacia del LED violeta en el blanqueamiento de dientes no vitales. Serie de casos: se seleccionaron tres casos clínicos (1, 2 y 3), que mostraron cambios en el color de dientes específicos para los tonos A2, C4 y B3, respectivamente. El blanqueamiento dental se realizó en tres sesiones (una sesión/semana). Cada sesión consistió en 20 aplicaciones de LED violeta durante 60 s, con un intervalo de 30 s entre ellas. Después de blanquear con el LED violeta, se aplicó peróxido de hidrógeno al 35% durante 15 min en los casos clínicos 2 y 3, con irradación continua con el LED violeta en los últimos 5 min. El blanqueamiento dental con LED violeta dio como resultado dientes en los colores A1, C3 y C2 en los casos clínicos 1, 2 y 3, respectivamente. La aplicación de peróxido de hidrógeno al 35% con el LED violeta alteró aún más el color de los dientes, A2 y C1, en los casos clínicos 2 y 3, respectivamente. **Conclusión:** el protocolo utilizado en esta serie de casos mostró que la iluminación con solo un LED violeta debe restringirse a los casos que requieren cambios de color menores.

Descriptores: Peróxido de Hidrógeno; Blanqueamiento Dental; LED Violeta.

INTRODUCTION

The desire for white teeth and harmonic smiles has become a frequent request in dental offices¹⁻⁴. The presence of one or more teeth of different shades can cause great psychological and social discomfort in patients.

Changes in the coloration of a specific tooth may be due to pulp haemorrhage, pulp

necrosis, inadequate endodontic treatment, the presence of endodontic cement in the clinical crown, failure to remove pulp horns, dental caries and cervical resorption⁵.

In endodontically treated teeth with little loss of tooth structure, endogenous whitening is the first option for restoring colour. Non-vital tooth whitening techniques include the

inside/outside closed technique⁵, which uses hydrogen peroxide as an active ingredient, the activation of which can be accelerated by the action of violet LED^{1,2,4,6,7}.

Violet LED is an option for tooth whitening, as the emitted photons interact with the chromophore molecules present in the enamel and dentin, breaking them down into smaller molecules^{1-3,6,8,9}. This is possible because the wavelength of violet LED (405–410 nm) coincides with the absorbance peak of these molecules, promoting the whitening of the tooth structure^{1-4,6-9}. In addition, violet LED is within the electromagnetic spectrum capable of biological interaction without molecular damage^{3,7,10}.

Violet LED can also be used concurrently with bleaching gels to enhance the expected effect^{1-4,6,7,9,10}. The combination of physical and chemical methods reduces the duration of application of the bleaching gel, reducing the effects on the surface roughness and microhardness of the enamel^{1,4,7,11,12}. However, the use of violet LED for non-vital tooth whitening needs further studies. To the best of our knowledge, only one study has evaluated the association of violet LED with hydrogen peroxide in pulped teeth. In addition, this study reported a single clinical case involving the application of violet LED prior to the application of hydrogen peroxide⁴.

Thus, the objective of this cases series is to report the results of using violet LED, with or without 35% hydrogen peroxide bleaching gel, for the whitening of non-vital teeth.

CLINICAL CASES

Patients reported to the Dental Whitening Project with complaints about the discoloration of a specific tooth. After anamnesis and clinical examination, non-vital tooth bleaching with violet LED (Bright Max Whitening, MMOptics Ltda, São Carlos, SP, Brazil) was proposed with or without the use of 35% hydrogen peroxide bleaching gel (Whiteness HP, FGM, Produtos odontológicos, Joinville, SC, Brazil). After approval of the treatment plan, the patients signed an informed consent form authorizing the treatment and disclosure of the pictures.

Firstly, periapical radiography of the teeth was performed to determine whether the proposed endodontic treatment was appropriate. Subsequently, prophylaxis was performed using Robson's brush and pumice (Kerr Corporation, Orange, CA, USA), and this was followed by shade selection (Vitapan Classical® Shade Guide, Bad Säckingen, Germany).

After shade selection, rubber dam isolation of canine to canine was performed,

followed by removal of composite resin restorations with a spherical diamond bur (1013) and cleaning of the pulp chamber with an endo-Z bur (FG, Angelus, Londrina, PR, Brazil), root canal desobturation at 3 mm below the cemento-enamel junction with a Gates-Glidden drill (Kerr Corporation, Orange, CA, USA), cleaning of the cavity with 0.12% chlorhexidine (PerioGard®, São Bernardo do Campo, SP, Brazil) and sealing of the cervical region with 2 mm of glass ionomer cement (Riva Self Cure, SDI, São Paulo, SP, Brazil).

Prior to tooth whitening with violet LED, teflon tape (3M, Sumaré, SP, Brazil) was used to cover the teeth next to the tooth to be whitened. The violet LED (λ 408 nm \pm 10 nm) was applied over three sessions (one session/week). The LED device contained 4 violet LEDs and was used at a power of 1,200 mW and total irradiance of 112 mW/cm². The LED tips were positioned at a 90° angle approximately 1 cm from the teeth. Each session consisted of 20 applications of 60 s, at 30-s intervals^{2,12}. In clinical cases where the colour change was not aesthetically acceptable (clinical cases 2 and 3), violet LED and 35% hydrogen peroxide bleaching gel were applied concomitantly with the objective of improving the clinical result. The bleaching gel was applied over the clinical crown and the internal and external surfaces for 15 min and the violet LED was applied with the bleaching gel for the final 5 min. This procedure was repeated three times in each of the three sessions (one session/week) (Figure 1).

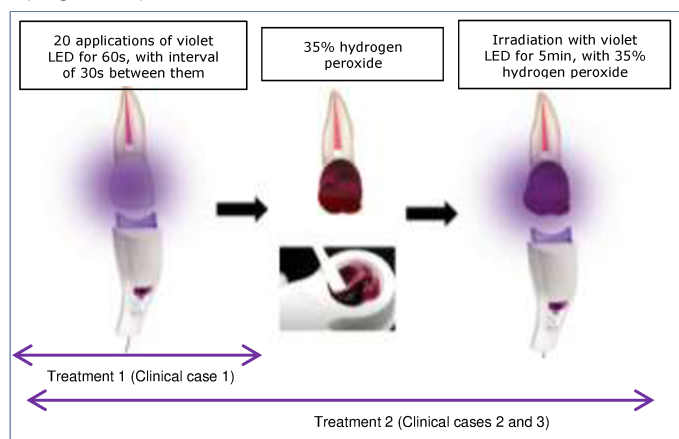


Figure 1: Whitening protocol (adapted from Almeida et al.⁴).

The bleaching gel was removed with an endodontic suctor (SSplus, Maringá, PR, Brazil) after which the tooth was washed with water. The change in colour was assessed at each session. One week after the last whitening session, the restoration was made, using the incremental technique with composite resin (Filtek® Z350 XT, 3M, Sumaré, SP, Brazil).

Treatment 1

○ Clinical case 1

A 28-year-old male, whose incisors (teeth 11 and 12) were initially shade A2 received in-office bleaching using only violet LED (protocol described above), and obtained a final shade of A1 in both teeth (Figure 2A-D).

Treatment 2

○ Clinical case 2

A 40-year-old male presented with a complaint regarding the colour of tooth 11 (shade C4). After three tooth whitening sessions using only the violet LED, the tooth shade had changed to C3, and after concomitant whitening using violet LED and 35% hydrogen peroxide bleaching gel, the final shade was A2 (Figure 2E-G).

○ Clinical case 3

A 42-year-old female complained about tooth 21 staining (shade B3). Lightening using only violet LED resulted in shade C2. To improve the clinical result, violet LED and the whitening gel were applied concomitantly, obtaining the final shade of C1 (Figure 2H-J).

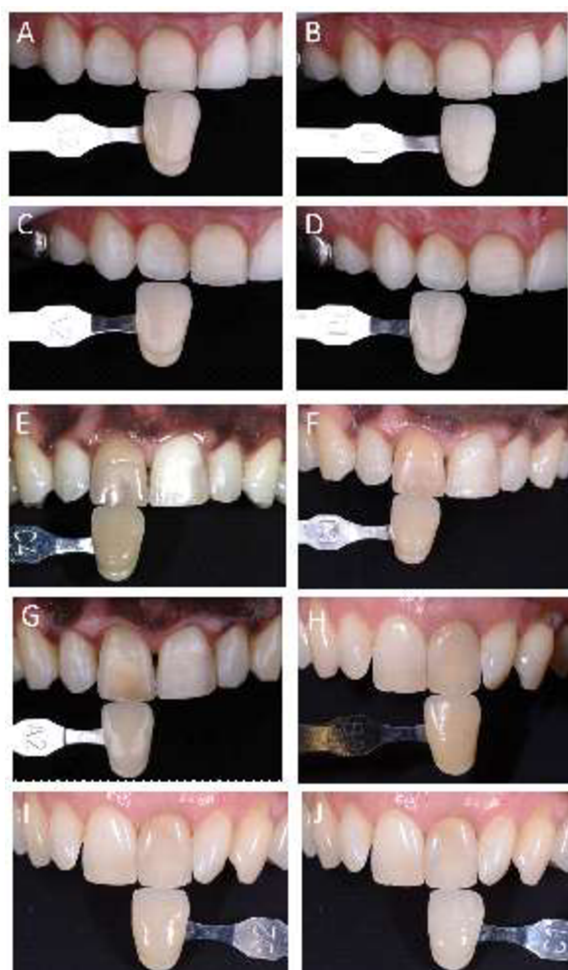


Figure 2: Clinical case 1 - (A,C) teeth 11 and 12 showing initial shade A2, and (B,D) final shade A1 after bleaching with violet LED; Clinical cases 2 and 3 - (E,H) teeth 11 and 21 showing initial shades C4 and B3, respectively, and (F,I) shades C3 and C2, respectively, after bleaching with violet LED, and (G,J) final shades A2 and C1, respectively, after bleaching with violet LED and 35% hydrogen peroxide bleaching gel.

DISCUSSION

The main aim of this study was to describe the results of three clinical cases using violet LED with or without 35% hydrogen peroxide bleaching gel for the whitening of non-vital teeth.

Bleaching of pulped teeth is a routine procedure in-office. Whitening techniques may be proposed in order to increase the effectiveness of the treatment, reduce the treatment duration and provide greater comfort to the patient⁸. Violet LED has shown limited effectiveness in teeth requiring greater colour changes, the concomitant use of a bleaching gel being required to improve the outcome^{2,7}.

Bleaching gels for use on non-vital teeth, such as hydrogen peroxide, act by catalytic action, decomposing into reactive oxygen species, which can be accelerated by violet LED^{1,2,4,6,7}. Thirty to 35% hydrogen peroxide is the most commonly used product for whitening of endodontically treated teeth, because it allows whitening in deeper regions due to its low molecular weight and high diffusion power through enamel and dentin^{4,13}.

The low penetrability of violet LED in dental tissue causes the surface molecules, which pigment the teeth, to be hit with greater energy, breaking their bonds⁷. However, the intensity of this light means that it is unable to change deeper pigmentations, as found in endodontically treated teeth¹¹, consistent with the results of the present case series, in which the violet LED was not able to promote major colour changes. In addition, violet LED has a momentary action, which stops after its removal.

Violet LED associated with bleaching gels has previously shown good clinical results^{1,4,6,7,9,10}, and likewise we found that the combination of 35% hydrogen peroxide gel with the violet LED produced a greater change in colour. This effectiveness can be attributed to the photochemical effect, which excites and vibrates the hydrogen peroxide molecules, increasing the release of reactive oxygen species and breaking down the chemical substances, which, in most cases, is not achieved only with the use of violet LED^{2,7,11}. Therefore, in patients requiring major colour changes, the combination of a physical method (light) with a chemical (whitening gel) is indicated⁷. The use of only violet LED should be restricted to small colour changes^{7,12}.

This study only evaluated the colour change subjectively (shade scale), as this is the assessment that is done routinely in-office. However, an objective assessment (e.g.,

Easysshade®) could be introduced to clinical studies.

FINAL CONSIDERATIONS

The bleaching of non-vital teeth using only violet LED should be restricted to small changes in colour. When a more extreme colour change is required, violet LED should be combined with a whitening gel (e.g., 35% hydrogen peroxide).

REFERENCES

1. Brugnare AP, Nammour S, Rodrigues JA, Mayer-Santos E, De Freitas PM, Brugnara A et al. Clinical Evaluation of In-Office Dental Bleaching Using a Violet Light-Emitted Diode. Photobiomodul Photomed Laser Surg. 2020; 38(2):98-104.
2. De Oliveira Gallinari M, Fagundes TC, Da Silva LMAV, De Almeida Souza MMB, De Souza Barboza AC, Briso ALF. A new approach for dental bleaching using violet light with or without the use of whitening gel: Study of bleaching effectiveness. Oper Dent. 2019; 44(5):521-29.
3. Santos AECG Dos, Bussadori SK, Pinto MM, Pantano Junior DA, Brugnara A, Zanin FAA et al. Evaluation of in-office tooth whitening treatment with violet LED: Protocol for a randomised controlled clinical trial. BMJ Open. 2018;8(9):1-9.
4. De Almeida ENM, Bessegato JF, dos Santos DDL, de Souza Rastelli AN, Bagnato VS. Violet LED for non-vital tooth bleaching as a new approach. Photodiagnosis Photodyn Ther. 2019;28:234-37.
5. Greenwall-Cohen J, Greenwall LH. The single discoloured tooth: vital and non-vital bleaching techniques. Br Dent J. 2019;226(11):839-49.
6. Gallinari M de O, Cintra LTA, Souza MB de A, Barboza ACS, Esteves LMB, Fagundes TC et al. Clinical analysis of color change and tooth sensitivity to violet LED during bleaching treatment: A case series with split-mouth design. Photodiagnosis Photodyn Ther. 2019; 27:59-65.
7. Kury M, Wada EE, Silva DP da, Tabchoury CPM, Giannini M, Cavalli V. Effect of violet LED light on in-office bleaching protocols: a randomized controlled clinical trial. J Appl Oral Sci. 2020;28:e20190720.
8. Lago ADN, Ferreira WDR, Furtado GS. Dental bleaching with the use of violet light only: Reality or Future? Photodiagnosis Photodyn Ther. 2017;17:124-26.
9. Gallinari M de O, Cintra LTA, Barboza ACS, da Silva LMAV, de Alcantara S, dos Santos PH, et al. Evaluation of the color change and tooth sensitivity in treatments that associate violet LED with carbamide peroxide 10 %: A randomized clinical trial of a split-mouth design. Photodiagnosis Photodyn Ther. 2020;30.
10. Rastelli AN de S, Dias HB, Carrera ET, de Barros ACP, dos Santos DDL, Panhóca VH et al. Violet LED with low concentration carbamide peroxide for dental bleaching: A case report. Photodiagnosis Photodyn Ther. 2018;23:270-72.
11. Klaric E, Rakic M, Marcius M, Ristic M, Sever I, Tarle Z. Optical effects of experimental light-activated bleaching procedures. Photomed Laser Surg. 2014;32(3):160-67.
12. Kury M, Perches C, da Silva DP, André CB, Tabchoury CPM, Giannini M et al. Color change, diffusion of hydrogen peroxide, and enamel morphology after in-office bleaching with violet light or nonthermal atmospheric plasma: An in vitro study. J Esthet Restor Dent. 2020;32(1):102-12.
13. Bartlett DW. Bleaching Discoloured Teeth. Dent Update 2001;28(1):14-8.

CONFLICTS OF INTERESTS

The authors declare no conflicts of interests.

CORRESPONDING AUTHOR

Sávio Morato de Lacerda Gontijo

Department of Oral Surgery, Pathology and Clinical Dentistry,
Faculty of Dentistry,
Federal University of Minas Gerais (UFMG),
Av. Presidente Antônio Carlos 6627,
31270-901 Belo Horizonte - MG, Brazil
Tel: +55 31-3409-2427, Fax: +55 31-3409-2427
E-mail: savio.morato@yahoo.com.br

Received 02/12/2021

Accepted 06/01/2022