

Doxorubicin nephrotoxicity in cats (*Felis catus*) with malignant mammary neoplasms

[Nefrotoxicidade da doxorubicina em gatas (*Felis catus*) com neoplasias mamárias malignas]

M.M. Nogueira¹ , G.E. Lavallo¹ , A.F.M. Botelho² , J.C.C. Veado¹ ,
G.D. Cassali³ , P.R. Paes¹ , M.M. Melo^{1*} 

¹Escola de Veterinária, Universidade Federal de Minas Gerais, Belo Horizonte, MG, Brasil

²Universidade Federal de Goiás, Goiânia, GO, Brasil

³Instituto de Ciências Biológicas, Universidade Federal de Minas Gerais, Belo Horizonte, MG, Brasil

ABSTRACT

The aim of the study was to investigate the nephrotoxicity of doxorubicin in cats with malignant neoplasms of the mammary gland. All selected cats did not present comorbidities such as nephropathies and/or cardiomyopathies, confirmed by physical and laboratory tests, underwent radical mastectomy associated with regional lymph node excision and were treated with a protocol based on doxorubicin. Renal markers of urea, creatinine, symmetrical dimethylarginine were evaluated during all the treatment, and two months after the end. Abdominal ultrasound, urinalysis and biochemical analysis of protein, urinary creatinine and urinary GGT were performed in the beginning and two months after the end of the treatment, to evaluate possible renal alterations. Six cats did not present renal alterations in any exams performed during the study. Two cats presented azotemia during this study, and one of them stopped the treatment early, because of the intense azotemia. Clinical imaging and laboratory monitoring of patients throughout the treatment is essential, including the measurement of analytes that detect kidney changes early. Thus, it is emphasized that doxorubicin is a safe drug for use in non-nephropathic cats.

Keywords: mammary cancer, chemotherapy, toxicity, feline

RESUMO

O objetivo do estudo foi investigar a nefrotoxicidade da doxorubicina em gatas com neoplasias malignas da glândula mamária. Todas as gatas selecionadas não apresentaram comorbidades como nefropatias e/ou cardiomiopatias, comprovadas por exames físicos e laboratoriais, foram submetidas à mastectomia radical associada à exérese de linfonodos regionais e tratadas com protocolo baseado em doxorubicina. Os marcadores renais ureia, creatinina, dimetilarginina simétrica foram avaliados durante todo o tratamento e dois meses após o término. Ultrassonografia abdominal, urinálise e análise bioquímica de proteínas, creatinina urinária e GGT urinária foram realizadas no início e dois meses após o término do tratamento, para avaliar possíveis alterações renais. Seis gatas não apresentaram alterações renais em nenhum dos exames realizados durante o estudo. Duas gatas apresentaram azotemia durante este estudo, e uma delas interrompeu o tratamento precocemente, devido à intensa azotemia. A individualidade de cada paciente deve ser sempre considerada, pois são muitas as variáveis. O monitoramento clínico, com exames complementares, tais como bioquímicos séricos e de imagem dos pacientes durante todo o tratamento, é essencial, especialmente a mensuração de analitos que detectam alterações renais precocemente. Diante disso, ressalta-se que a doxorubicina é um medicamento seguro para utilização em gatas não nefropatas.

Palavras-chave: câncer de mama, quimioterapia, toxicidade, felino

*Corresponding author: mariliamm@ufmg.br

Submitted: July 29, 2022. Accepted: January 27, 2023.

INTRODUCTION

Feline mammary carcinomas (FMC) behave aggressively in cats (Zappulli *et al.*, 2015), and correspond to the third most frequent type of neoplasia diagnosed in this species (12 to 17%), after cutaneous and hematopoietic tumors (Viste *et al.*, 2002).

Early aggressive surgery is the main treatment in FMC (Cunha *et al.*, 2016). This should be performed in conjunction with other therapies, such as chemotherapy (Campos *et al.*, 2015).

Chemotherapy protocols proposed by the literature, for the treatment of FMC, consist of the use of three to four applications of doxorubicin (DOX), an anti-tumor antibiotic, non-specific cell cycle. However, side effects due to the use of DOX in cats, such as anorexia, alopecia, myelosuppression, weight loss, vomiting, diarrhea and kidney injury have been previously described (O'Keefe *et al.*, 1993; Reiman *et al.*, 2008).

Considering the importance of FMC and the potential toxicity of DOX, it is imperative to evaluate clinical, image and laboratory parameters of cats with this tumor undergoing treatment with DOX. Therefore, we aimed to investigate, describe and characterize the nephrotoxic potential of DOX in felines using serum renal biomarkers, urinalysis and imaging exams.

MATERIAL AND METHODS

All procedures were performed under the appropriate guidelines and with the approval of the Ethics Committee for Animal Experimentation of the Federal University of Minas Gerais (CEUA/UFMG), protocol number 184/2020. Informed consent (verbal and written) was obtained from the owner or legal custodian of all animals described in this work for all procedures undertaken.

A clinical study was carried out with eight mixed breed queens diagnosed with FMC. Inclusion criteria included cats diagnosed with mammary cancer, undergoing radical mastectomy as a surgical treatment, associated with the excision of regional lymph nodes. Cats with comorbidities were excluded, such as nephropathies and/or

cardiomyopathies (confirmed by physical and laboratory exams, using the following serum biomarkers: troponin I, symmetric dimethylarginine, creatinine, urea, in addition to urinary protein/creatinine), and imaging exams, abdominal ultrasound and echocardiogram.

The cats underwent radical mastectomy as a surgical treatment, associated with the excision of regional lymph nodes, with histopathological diagnosis of the nodules (Cassali *et al.*, 2018). According to the results of staging and histopathology, therapeutic supplementation with DOX-based chemotherapy was required in all animals studied.

Four applications of DOX (Fauldoxo®) were performed, performed every 21 days, at a dose of 1.0mg/kg, via slow IV, with an average duration of 20 minutes. Venous access was performed with the aid of a 24g size venous catheter, coupled to a macro droplet equipment and fluid based on 0.9% sodium chloride. The analyzes were performed in each chemotherapy session and at the end of the experiment (two months after the last application of DOX). All cats that are alive are still being accompanied by the team of the experiment.

Immediately before each session, all cats received IV drugs: ondansetron (1,0mg/kg; Emedron 1% - Agener União®) and omeprazole (1,0mg/kg; Oprazon®), to control possible vomits and protect the gastrointestinal tract. From the first chemotherapy session, all cats received the nutritional supplement composed of essential fatty acids, with a high concentration of DHA (Oxcell 500 Avert® - composition 6mg EPA + 30mg DHA), daily, until the end of the experiment.

Blood samples were collected from cephalic vein in tubes with 10% EDTA for hematologic analysis and without anticoagulant to obtain serum (biochemical analyzes), at time zero (day one, first session), on the day of each other session (days 21, 42 and 63) and two months after the end of treatment (day 123), totalizing five sample collections.

Complete blood count was performed in an automatic blood cell analyzer (PocH-100iV - Sysmex®) and the differential leukocyte count, evaluation of erythrocyte morphology, and

evaluation of platelet numbers were performed in stained blood film with Wright stain. To evaluate the nephrotoxicity, serum biochemical analyzes of urea and creatinine were conducted using Cobas Mira Plus® device, with BioClin® reagents. Serum symmetrical dimethylarginine (SDMA), which was measured using Catalyst SDMA tests on the IDEXX® Catalyst One biochemical analyzer.

Abdominal ultrasonography was performed after trichotomy of the ventral abdominal region, with the animals in the supine position, accomplished by the same veterinarian. The device used was the GE R7 0 Logiq E Vet, with the aid of the 7-10MHz multifrequency 12L transducer, with a frequency of 8 and 10MHz. The aspect of the kidneys was evaluated in terms of size, echogenicity, presence of changes in the parenchyma and morphology.

Urine samples were collected through ultrasound-guided cystocentesis, on the day of the first session and two months after treatment, and packed in sterile flasks for urinalysis, using refractometry and optical microscope, and biochemical analysis of protein, urinary creatinine and urinary GGT in the Cobas equipment Mira Plus®.

A block design was performed considering the moments of evaluation, with parametric ANOVA-Tukey analyzes and non-parametric Kruskal-Wallis and Dunn analyzes. The normality test used was Kolmogorov-Smirnov. Biochemical markers were analyzed, with a

significance level of 5%, and the software used was Graph Pad Prism 8.

RESULTS

In this preliminary study, eight cats, mixed breed (SRD), aged between seven and 16 years were studied. Of these cats, five completed all chemotherapy sessions (four applications of DOX, performed every 21 days), and four even completed exams at the end time (two months after the last DOX application).

Upon initial clinical examination, all cats were stable, with normal body temperature, normohydrated, active, with no changes in pulmonary and cardiac auscultation, with normal abdominal palpation. All cats were submitted to unilateral radical mastectomy, associated with the excision of regional lymph nodes, as an initial treatment for FMC. Of the eight cats, four (50%) had more than one affected mammary gland, and six (75%) cats had lymph nodes with macro metastasis.

In the initial time, all the cats had kidneys with normal appearance and size at abdominal ultrasound. At the final time (two months after the end of treatment), the four cats who completed the therapeutic protocol (1,6,7 and 8), underwent a new abdominal ultrasound. Three of them (animals 1, 6 and 7) did not show changes in kidney topography. The older cat (animal 8), presented a slight loss of renal cortical-medullary definition, associated with a slight increase in the echogenicity of the cortical region (Figures 1 A and B).

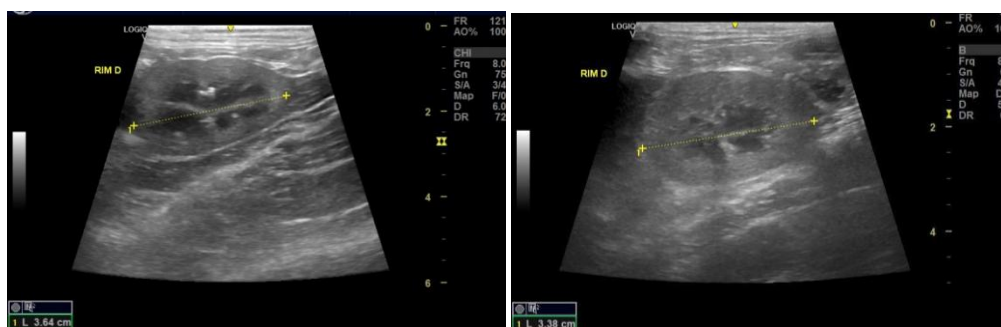

Figure 1 (A and B), Abdominal ultrasound of animal 8 in initial (A) and the final time (B) of dox based protocol, presenting slight loss of renal cortical-medullary definition, associated with a slight increase in the echogenicity of the cortical region, suggesting the onset of nephropathy. Ultrasound device: GE R7-Logiq E Veterinary.

Biochemical analyzes (Figure 2) were performed at the beginning of the protocol, on the day of each session and two months after the end of the experiment. The measured analytes did not show differences between the times ($p < 0.05$). One (12.5%) of the cats presented azotemia during the protocol and stopped it. One (25%) of the four cats who were evaluated at the final time presented azotemia.

The number of erythrocytes, hematocrit, hemoglobin, and RBC indices remained normal at all times, and there were no statistical differences between the times studied. The leukogram remained within the normal range for the feline species throughout the treatment.

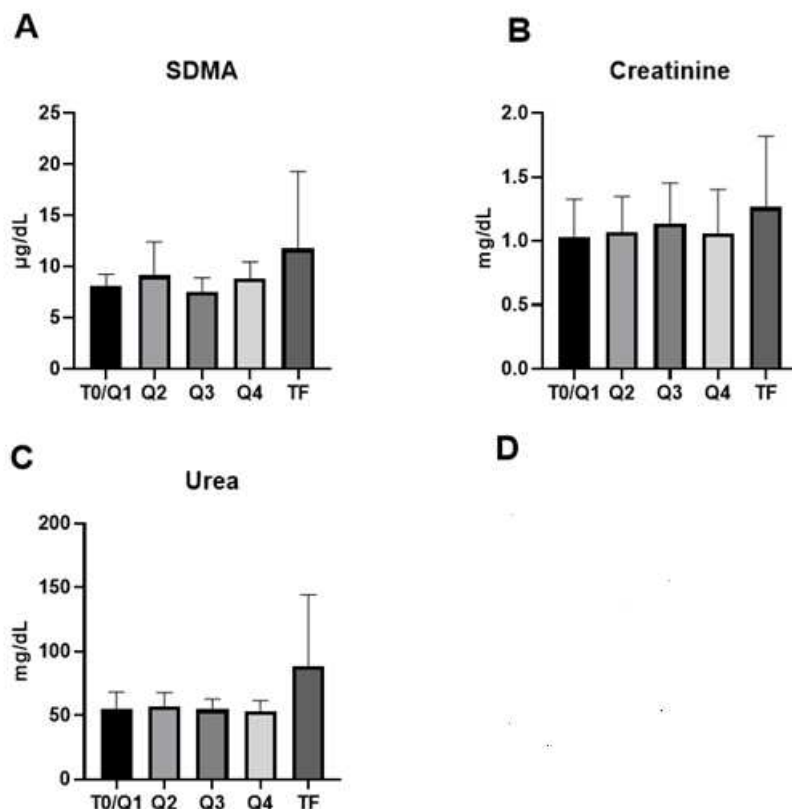


Figure 2 (A, B and C). Mean values and standard deviation of the serum biomarkers of renal in cats at the initial time (T0 / Q1), on the day of each chemotherapy session (Q2, Q2, Q4- every 21 days) and two months (TF) after the end of the base protocol doxorubicin. The number of animals evaluated was: T0 / Q1: 8; Q2: 7; Q3: 6; Q4: 5; and TF: 4. Parameters evaluated were the serum concentration of symmetrical dimethylarginine (SDMA) (A), creatinine (CREA) (B), urea (URE) (C). Parametric data (SDMA and CREA) were evaluated by ANOVA and Tukey's post-test. Nonparametric data (URE) were evaluated by Kruskal-Wallis and Dunn ($p < 0.05$).

Four animals died (2, 3, 4 and 5). The death of animal 4 occurred after the first chemotherapy session, due to causes not associated with FMC. This feline presented urinary obstruction due to adhesion from the ureter to the nylon clamp. Despite having been performed an emergency surgery, this animal did not resist and due to systemic alterations, it died quickly (24 hours).

Animal 2, after the second session, presented vomiting, lack of appetite and moderate dehydration. Further tests were performed, and azotemia was noted. The animal had serum urea concentration of 77.28mg/dL and creatinine of 3.42mg/dL (at time zero, before DOX treatment, urea and creatinine concentration showed values of 74.25mg/dL and 1.31mg/d, respectively). After hydration and application of antiemetics

(maropitant 1.0mg/kg SC SID, ondansetron 1.0mg/kg IV TID), urea levels dropped to 71.0mg/dL, and creatinine to 1.95mg/dL. Chemotherapy treatment was interrupted, and after one month, another abdominal ultrasound was performed, which revealed diffuse hyperechogenicity of the cortical region of both kidneys, suggesting bilateral nephropathy. After 12 months, the cat was admitted to the veterinary hospital with creatinine of 15.27mg/dL, urea of 620.95mg/dL, and died on the second day of hospitalization. The necropsy was not authorized by the tutors. After the second chemotherapy session, this animal did not receive any other type of cancer treatment, and until the moment of death, it did not show disease progression. Therefore, it is important to mention that the death was not due to mammary cancer, but probably to chronic kidney disease.

Animal 3, between the third and fourth sessions, presented dyspnea and tachypnea, and therefore, at that time, chest radiographs were taken. In these, radiopaque spots were observed in the topography of pulmonary vessels, suggestive of metastasis. This feline, despite having completed the chemotherapy protocol, died after a month, and the exams were not carried out at the end of the period.

Animal 5 presented discreet radiopaque points in the topography of vessels pulmonary lesions, initially suggesting pulmonary metastasis. It is noteworthy that this cat, eight months before the date of surgery, already had mammary nodules. A cytology was performed, which suggested a glandular epithelial proliferative process. This animal followed the chemotherapy protocol, and destabilized after the third session, presenting pleural effusion and dyspnea. After symptomatic treatment, the X-ray was repeated, revealing worsening of the pulmonary metastatic condition. The cat died before the fourth session.

At the initial time, all the studied cats had SDMA within the reference limits for the species (0-14µg/dL). The values for all times are described in Figure 2. Animal 2 previously described, which presented intense azotemia after the second session, presented an increase in serum SDMA (16µg/dL) at this time.

Animal 8, at the end of the protocol, presented SDMA with a moderate increase (23µg/dL),

indicating renal dysfunction. Urea and creatinine, in the same period, was also above normal values - urea 40-60mg/dL, and creatinine 0.8-1.6mg/dL (Hall *et al.*, 2014).

Urinalysis was performed at the beginning of treatment, and two months after the end. No changes were found in the analyzes performed, and all cats maintained normal urinary density in both measurements, which would be the most important parameter, considering the possible nephrotoxicity caused by DOX. At the same time, exams such as protein/urinary creatinine (RPCu) and urinary GGT were also realized, without abnormalities.

DISCUSSION

Most cats included in the study were over 10 years old. They are considered senior by previous reports (Quimby *et al.*, 2021), and represent an important portion of animals diagnosed with cancer. All cats were diagnosed with malignant mammary neoplasms, with aggressive subtypes (Cassali *et al.*, 2018), and 75% of the cats of this study presented lymph nodes with macro metastasis (cell deposits greater than 2.0mm), as described by Greene *et al.* (2002). The staging of the cats was compatible with the need for complementary therapy with the DOX-based protocol (McNeill *et al.*, 2009; Petrucci *et al.*, 2021).

Regarding the blood profile, the findings suggest that protocols of four sessions of DOX at a dose of 1mg/kg are safe for cats, without hematological toxicity. The importance of performing blood counts throughout the treatment is highlighted, because side effects may occur, although uncommon.

To evaluate nephrotoxicity, laboratory and imaging tests were performed. Abdominal ultrasound was performed at the beginning and after the end of the chemotherapy protocol, to study renal morphology. Chronic kidney disease (CKD), common in elderly cats, results in small, irregularly outlined kidneys which show normal or increased echogenicity of the cortex and medulla, decreased corticomedullary distinction and poor visualization of the internal architecture (Debruyne *et al.*, 2012).

Azotemia in felines is defined by increased serum concentrations of urea, that is, values above 60mg/dL and creatinine, above 1.6mg/dL (Hall *et al.*, 2014). Although the occurrence of azotemia is associated with the use of DOX in cats (Kopečný *et al.*, 2020), between the first chemotherapy session and the last measurement at the end time, azotemia only occurred in two (25%) cats (animals 2 and 8), animal 8 who presented alterations in abdominal ultrasound. Three (75%) of the four cats who were evaluated at the final time did not have azotemia. The fact that azotemia was reported in only two cats is expected. In a retrospective study with 60 cats subjected to different DOX applications, no clinical signs or increase in urea and creatinine were observed. This suggests that therapeutic doses of DOX accompanied by renoprotection with fluid therapy does not cause nephrotoxicity (Reiman *et al.*, 2008). However, animal 2 developed both kidney damage and clinical signs. According to O' Keefe *et al.* (1993), reported a study with six cats submitted to 30mg/m² of DOX (approximately 6.24mg / kg every 21 days, up to a cumulative dose of 300mg/m² - 10 applications). With this high dose, all cats showed anorexia and weight loss after the fifth application of the drug. Changes in renal function, characterized by azotemia and progressive decrease in urinary density, were observed in 33% of the cats, and no abdominal ultrasound was cited. All of them presented evidence of chronic kidney disease at necropsy.

Among 70 cats who received doxorubicin-based treatment in one study, 29% of them experienced acute kidney injury during treatment (Kopečný *et al.*, 2020). In our study, animal 2, presented intense azotemia and stopped the protocol after the second session. It is important to emphasize that individuality must always be considered, since despite this animal, as well as the other seven cats studied, having shown normality in the initial exams, including early markers such as SDMA, it presented renal side effects after the onset doxorubicin-based protocol, which culminated in death the following year. SDMA is an accurate biomarker used to study the glomerular filtration rate (GFR). It is a more sensitive marker than creatinine, assessing changes in renal filtration function earlier, showing an increase in values when about 25 to 40% of the nephrons are compromised (Hall *et al.*, 2014).

However, it was mentioned that 33% of the cats fit into stage 1 of chronic kidney disease, as proposed by the International Society of Renal Interest (IRIS), and 9% in stage 2 (IRIS, 2019). Of the cats that showed an increase in serum creatinine, 34% had values greater than or equal to 0.3mg/dL, and 29% of the cats had acute kidney injury during treatment (Kopečný *et al.*, 2020).

The animal 8 was 16 years old, and at the end (two months after the last chemotherapy session), had SDMA (23µg/dL), urea (171.66mg/dL) and creatinine (1.98mg/dL) above normal values, and changes in abdominal ultrasound. The change in renal function, observed by the serum markers urea, creatinine, SDMA, and by abdominal ultrasound, indicates that this animal was in stage 2 of IRIS chronic kidney disease in felines (IRIS, 2019). The onset of the pathology may have occurred by a predisposition due the DOX treatment, or naturally and individually, since chronic kidney disease is the most diagnosed metabolic pathology in cats, especially the elderly (Brown *et al.*, 2016). In a study with 86 cats, a prevalence of 50% of chronic kidney disease was found, with a considerable increase among cats over 15 years old (Marino *et al.*, 2014). This feline, despite his high age, histopathological diagnoses elucidating severe histological types and macro metastasis in regional lymph nodes, grade III FMC staging, and high Ki-67 (53%) did not progress to lung metastasis or present new mammary neoplasms, remaining clinically well throughout the study.

The other three cats that completed the protocol in the final time maintained the renal biochemical profile, urinary analysis, and abdominal ultrasound without alterations.

It is important to note that after the IRIS staging for chronic kidney disease in felines (IRIS, 2019), the eight cats studied did not show changes compatible with the initial CKD, and only the animal 8, presented the final CKD, demonstrating that the dose and frequency DOX used is safe for non-nephropathic patients, who are not into CKD stages of IRIS. In the study by Kopečný *et al.* (2020), of the 70 cats that received treatment based on DOX (dose not mentioned), 33% of the cats fit in stage 1 of chronic kidney disease of IRIS and 9% in stage

2. Of the cats that had increased creatinine, 34% had values greater than or equal to 0.3mg/dL, and 29% of the cats had acute kidney injury during treatment. This fact is probably due to the altered renal function of patients at the beginning of treatment, demonstrating the importance of conducting a complete study of renal function (combining urinary tests, early markers, and abdominal ultrasound) before the start of treatment.

Urine tests are important renal markers. Proteinuria, identified by the result of the urinary protein/creatinine ratio above 0.4 in cats, is a factor that influences the progression of chronic kidney disease in cats, worsening the prognosis (Chakrabarti *et al.*, 2012). RPCu is part of the under-staging of chronic kidney disease by IRIS, with RPCu below 0.2 is considered normal, between 0.2 and 0.4 borderline, and above 0.4 proteinuria (IRIS, 2019). All cats, at the initial moment, had normal RPCu, as well as the four cats that made such an analysis after the end of the experiment. GGT were also measured and remained unchanged in all analyzes performed.

CONCLUSIONS

Doxorubicin may contribute to increased renal enzymes in cats. At the correct dose and with clinical and laboratory follow-up, doxorubicin is indicated as a treatment protocol for cats with mammary tumors.

REFERENCES

- BROWN, C.A.; ELLIOTT, J.; SCHMIEDT, C.W. *et al.* Chronic kidney disease in aged cats. *Vet. Pathol.*, v.53, p.309-326, 2016.
- CAMPOS, C.B.; DAMASCENO, K.A.; GAMBA, C.O. *et al.* Evaluation of prognostic factors and survival rates in malignant feline mammary gland neoplasms. *J. Feline Med. Surg.*, v.18, p.1003-1012, 2015.
- CASSALI, G.D.; CAMPOS, C.B.; BERTAGNOLI, A.C. *et al.* Consensus for the diagnosis, prognosis and treatment of feline mammary tumors. *Braz. J. Vet. Res. Anim. Sci.*, v.55, p.1-17, 2018.
- CHAKRABARTI, S.; SYME, H.M.; ELLIOTT, J. Clinicopathological variables predicting progression of azotemia in cats with chronic kidney disease. *J. Vet. Intern. Med.*, v.26, p.275-281, 2012.
- CUNHA, S.; CORGOZINHO, K.; JUSTEN, H. *et al.* Survival and disease-free interval of cats with mammary carcinoma treated with chain mastectomy. *Acta Sci. Vet.*, v.44, p.1349, 2016.
- DEBRUYN, K.; HAERS, H.; COMBES, A. *et al.* Ultrasonography of the feline kidney: technique, anatomy and changes associated with disease. *J. Feline Med. Surg.*, v.14, p.794-803, 2012.
- GREENE, F.L.; PAGE, D.L.; FLEMING, I.D.; *et al.* AJCC Cancer Staging Manual, 6ed, Springer, p.223-240, 2002.
- HALL, J.; YERRAMILI, M.; OBARE, E. Comparison of serum concentrations of symmetric dimethylarginine and creatinine as kidney function biomarkers in cats with chronic kidney disease. *J. Vet. Intern. Med.*, v.28, p.1676-1683, 2014.
- IRIS staging of CKD (IRIS); Diretrizes. International Renal Interest Society, 2019. Available in: http://www.iris-kidney.com/pdf/IRIS_Staging_of_CKD_modified_2019.pdf. Accessed in: 18 Jul. 2022.
- KOPECNY, L.; PALM, C.; SKORUPSKI, K. *et al.* Risk factors associated with progressive increases in serum creatinine concentrations in cats with cancer receiving doxorubicin. *J. Vet. Intern. Med.*, v.34, p.2048-2055, 2020.
- MARINO, C.; LASCELLES, B.; VADEN, S. *et al.* Prevalence and classification of chronic kidney disease in cats randomly selected from four age groups and in cats recruited for degenerative joint disease studies. *J. Feline Med. Surg.*, v.16, p.465-472, 2014.
- McNEILL, C.J.; SORENMO, K.U.; SHOFER, F.S. *et al.* Evaluation of adjuvant doxorubicin-based chemotherapy for the treatment of feline mammary carcinoma. *J. Vet. Intern. Med.*, v.23, p.123-129, 2009.
- O'KEEFE, D.A.; SISSON, D.D.; GELBERG, H.B. *et al.* Systemic toxicity associated with doxorubicin administration in cats. *J. Vet. Intern. Med.*, v.7, p.309-317, 1993.

PETRUCCI, G.N.; HENRIQUES, J.; LOBO, L. *et al.* Adjuvant doxorubicin vs metronomic cyclophosphamide and meloxicam vs surgery alone for cats with mammary carcinomas: A retrospective study of 137 cases. *Surg. Oncol.*, v.19, Nesp., p.714-723, 2021.

QUIMBY, J.; GOWLAND, S.; CARNEY, H. *et al.* AAHA/AAFP feline life stage guidelines. *J. Feline Med. Surg.*, v.23, p.211-233, 2021.

REIMAN, R.A.; MAULDIN, G.E.; MAULDIN, G.N. A comparison of toxicity of two dosing schemes for doxorubicin in the cat. *J. Feline Med. Surg.*, v.10, p.324-331, 2008.

VISTE, J.R.; MYERS, S.L.; SINGH, B. *et al.* Feline mammary adenocarcinoma: tumor size as a prognostic indicator. *Can. Vet. J.*, v.43, p.33-37, 2002

ZAPPULLI, V.; RASOTTO, R.; CALIARI, D. *et al.* Prognostic evaluation of feline mammary carcinomas a review of the literature. *Vet. Pathol.*, v.52, p.46-60, 2015.