

Correction of malocclusion in individuals with osteogenesis imperfecta: a systematic review

Correção de má oclusão em indivíduos com osteogênese imperfeita: uma revisão sistemática

Corrección de la maloclusión en individuos con osteogénesis imperfecta: una revisión sistemática

Received: 09/14/2022 | Revised: 09/26/2022 | Accepted: 09/27/2022 | Published: 10/06/2022

Heloisa Vieira Prado

ORCID: <https://orcid.org/0000-0002-9061-5644>
Federal University of Minas Gerais, Brazil
E-mail: heloisaprado92@hotmail.com

Flavia Rabello

ORCID: <https://orcid.org/0000-0001-8812-4208>
Federal University of Minas Gerais, Brazil
E-mail: flavia.rbh@gmail.com

Natália Cristina Ruy Carneiro

ORCID: <https://orcid.org/0000-0002-3028-7095>
Federal University of Minas Gerais, Brazil
E-mail: nataliacrcarneiro@hotmail.com

Suélen Alves Teixeira Debossan

ORCID: <https://orcid.org/0000-0002-1529-9311>
Federal University of Minas Gerais, Brazil
E-mail: su.alvesteixeira@gmail.com

Lucas Guimarães Abreu

ORCID: <https://orcid.org/0000-0003-2258-8071>
Federal University of Minas Gerais, Brazil
E-mail: lucasgabreu01@gmail.com

Ana Cristina Borges-Oliveira

ORCID: <https://orcid.org/0000-0003-3364-4024>
Federal University of Minas Gerais, Brazil
E-mail: anacboliveira7@gmail.com

Abstract

The aim of the study was to verify the viability of the correction of malocclusion in individuals with osteogenesis imperfecta (OI). A systematic review was developed using PubMed, Web of Science, Scopus, Lilacs, Ovid, Google Scholar and OpenGrey databases. The review was registered in PROSPERO (CRD42018114217). Data extraction was conducted by two researchers. Studies describing orthodontic treatment, orthognathic surgery or orthodontic treatment combined with orthognathic surgery for the correction of malocclusion in individuals with OI were eligible. The methodological quality of the articles was appraised using the case report assessment tool proposed by the Joanna Briggs Institute. The results were synthesized qualitatively. The 22 case reports included in the present review involved a total of 28 clinical cases. Malocclusion was considered severe in 11 cases, with records of negative overjet between nine and 26mm. Orthodontic treatment was performed in four cases, orthognathic surgery was performed in five cases and orthodontic treatment combined with orthognathic surgery was performed in 19 cases. All treated cases had favorable clinical results. Overall, the methodological quality of the articles included was satisfactory. Based on the analyzed cases, which reported only cases with successful results, treatment for malocclusion is viable in individuals with OI. When duly indicated, treatment can be performed with orthodontic treatment, orthognathic surgery or a combination of both, providing satisfactory esthetic and functional results with adequate stability.

Keywords: Rare diseases; Osteogenesis imperfecta; Malocclusion; Craniofacial abnormalities.

Resumo

O objetivo do estudo foi verificar a viabilidade da correção da má oclusão em indivíduos com osteogênese imperfeita (OI). Foi desenvolvida uma revisão sistemática com busca nas bases *PubMed*, *Web of Science*, *Scopus*, *Lilacs*, *Ovid*, *Google Scholar* e *OpenGrey*. A revisão foi registrada no PROSPERO (CRD42018114217). A extração de dados foi realizada por dois pesquisadores. Foram elegíveis estudos que descrevessem tratamento ortodôntico, cirurgia ortognática ou tratamento ortodôntico combinado com cirurgia ortognática para correção de má oclusão em indivíduos com OI. A qualidade metodológica dos artigos foi avaliada por meio do instrumento de avaliação de relato de caso do Joanna Briggs Institute. Os resultados foram sintetizados qualitativamente. Os 22 relatos de casos incluídos na presente revisão envolveram um total de 28 casos clínicos. A má oclusão foi considerada grave em 11 casos, com registros de *overjet* negativo entre nove e 26mm. O tratamento ortodôntico foi realizado em quatro casos, a

cirurgia ortognática foi realizada em cinco casos e o tratamento ortodôntico combinado com a cirurgia ortognática foi realizado em 19 casos. Todos os casos tratados tiveram resultados clínicos favoráveis. No geral, a qualidade metodológica dos artigos incluídos foi satisfatória. Com base nos casos analisados, que relataram apenas casos com resultados bem-sucedidos, o tratamento da má oclusão é viável em indivíduos com OI. Quando devidamente indicado, o tratamento pode ser realizado com tratamento ortodôntico, cirurgia ortognática ou a combinação de ambos, proporcionando resultados estéticos e funcionais satisfatórios com estabilidade adequada.

Palavras-chave: Doenças raras; Osteogênese imperfeita; Má oclusão; Anormalidades craniofaciais.

Resumen

El objetivo del estudio fue verificar la factibilidad de corregir la maloclusión en individuos con osteogénesis imperfecta (OI). Se desarrolló una revisión sistemática utilizando las bases de datos PubMed, Web of Science, Scopus, Lilacs, Ovid, Google Scholar y OpenGrey. La revisión fue registrada en PROSPERO (CRD42018114217). La extracción de datos fue realizada por dos investigadores. Fueron elegibles los estudios que describían el tratamiento de ortodoncia, la cirugía ortognática o el tratamiento de ortodoncia combinado con cirugía ortognática para corregir la maloclusión en pacientes con OI. La calidad metodológica de los artículos se evaluó mediante el instrumento de evaluación de informes de casos del Instituto Joanna Briggs. Los resultados fueron sintetizados cualitativamente. Los 22 informes de casos incluidos en la presente revisión involucraron un total de 28 casos clínicos. La maloclusión se consideró grave en 11 casos, con registros de overjet negativos entre 9 y 26 mm. Se realizó tratamiento de ortodoncia en cuatro casos, cirugía ortognática en cinco casos y tratamiento de ortodoncia combinado con cirugía ortognática en 19 casos. Todos los casos tratados tuvieron resultados clínicos favorables. En general, la calidad metodológica de los artículos incluidos fue satisfactoria. Con base en los casos analizados, que informaron solo casos con resultados exitosos, el tratamiento de la maloclusión es factible en personas con OI. Cuando está devidamente indicado, el tratamiento se puede realizar con tratamiento de ortodoncia, cirugía ortognática o una combinación de ambos, brindando resultados estéticos y funcionales satisfactorios con una adecuada estabilidad.

Palabras clave: Enfermedades raras; Osteogénesis imperfecta; Maloclusión; Anomalías craneofaciales.

1. Introduction

Osteogenesis imperfecta (OI), also known as brittle bone disease, is a rare genetic disease that affects 1:15,000 to 1:20,000 live births (Subramanian & Viswanathan, 2022). In most cases, OI is of an autosomal dominant origin, with the altered synthesis of type I collagen due to mutations in the COL1A1 and COL1A2 genes (Alharbi, 2015; Andersson et al., 2017; Subramanian & Viswanathan, 2022; Valadares et al., 2014). The disease is characterized by osteopenia and frail bones, with the possibility of multiple fractures and progressive bone deformities. Joint hyperlaxity, low stature, bluish sclera and hearing loss have also been reported (Alharbi, 2015; Andersson et al., 2017; Gorlin, et al., 2001; Rauch & Glorieux, 2004).

The Sillence classification is based on clinical characteristics, radiological findings and the inheritance pattern and classifies the disease into four types. Type I OI is the mildest and most common form, with few or no fractures and bone deformities. Type II is lethal in the prenatal period. Type III is the severe form, with the occurrence of multiple fractures and progressive deformities. Type IV is a moderate form of the disease, with broad clinical variability (Alharbi, 2015; Deguchi et al., 2021; Valadares et al., 2014; Van Dijk & Sillence, 2014). A redefinition of the Sillence classification performed by the Nosology Group of the International Skeletal Dysplasia Society included type V, which is a moderate form of the disease characterized by the formation of hyperplastic calluses (Valadares et al., 2014).

OI is associated with diverse dental and craniofacial abnormalities, the most prevalent of which are a triangular face, dentinogenesis imperfecta and malocclusion (Abukabbos & Al-Sineedim 2013; Chang, et al., 2007; Huber, 2007; O'Connell & Marini, 1999; Rousseau & Retrouvey, 2018). Abnormal bone growth and head size can lead to maxillary hypoplasia, mandibular prognathism or both, which predisposes the individual to Angle class III malocclusion. Occlusal problems are also found, such as open bite and anterior and/or posterior crossbite (Chang et al., 2017; Kindelan, Tobin, et al., 2003; Rizkallah et al., 2013; Okawa et al., 2017; Rousseau & Retrouvey, 2018). These occlusal disorders can compromise chewing function, speech and facial esthetics, exerting a negative impact on social aspects and quality of life (Nguyen et al., 2017; Vanz et al., 2018).

Orthodontic intervention and/or orthognathic surgery for the correction of malocclusion in individuals with OI may be feasible (Harstfield, et al., 2006; Kindelan et al., 2003), but the treatment might be difficult due to the greater risk of fractures among these individuals (Huber, 2007). There is no cure for OI, but bisphosphonates are administered to inhibit the osteoclasts and consequently reduce the incidence of fractures. Bisphosphonates, however, may impair orthodontic movement.

There are no defined treatment protocols for correcting malocclusion in individuals with OI. Awareness of information on this issue may be helpful in improving the clinical practice of oral health practitioners who devote their time to provide care to these individuals. Therefore, the aim of the present study was to perform a systematic review to verify the viability of the correction of malocclusion in individuals with OI, synthesizing the information of the literature on orthodontic treatment, orthognathic surgery or a combination of both.

2. Methodology

2.1 Protocol and registration

The present systematic review was performed following the PRISMA - Preferred Reporting Items for Systematic Reviews and Meta-Analyses (Page et al., 2021). The protocol was registered in the International Prospective Register of Systematic Reviews (PROSPERO) under number CRD42018114217.

2.2 Eligibility criteria

Studies describing orthodontic treatment, orthognathic surgery or orthodontic treatment combined with orthognathic surgery for the correction of malocclusion in individuals with OI were eligible. No restrictions were imposed regarding language or year of publication. Abstracts presented at conferences, literature reviews and case reports that did not describe these treatment modalities for individuals with OI were excluded.

The question that guided this systematic review was: Is it viable to correct malocclusion in individuals with OI?

P (Patients) = Individuals with OI (any type, any sex, any age)

I (Intervention) = Orthodontic treatment, orthognathic surgery or a combination.

C (Comparison) = No comparison.

O (Outcome) = Correction of the malocclusion (primary outcome). Adverse effects (secondary outcome).

2.3 Databases and search strategy

Searches were performed in six electronic databases: Medline via PubMed (National Library of Medicine), Ovid (Wolters Kluwer), Web of Science (Clarivate Analytics), Scopus (Elsevier), LILACS, and Embase, from databases' date of inception until April/ 2021. Indexed terms (MeSH) and synonyms were used for the search in PubMed (Charts 1) and adjustments were made to the search strategy for the other databases, depending on the characteristics of each database.

Charts 1. Search strategy employed in PubMed.

Database	Search Strategy
PubMed	orthodontic OR malocclusion OR orthognathic surgery OR dentofacial orthopedics AND “osteogenesis imperfecta” OR “Lobstein disease” OR “brittle bone disease” OR “glass bone disease” OR “fragilitas ossium” OR “collagen disease” OR “Adair-Dighton disease” OR “Adair-Dighton syndrome” OR “Aplasia periostalis” OR “Blegvad- Haxthausen syndrome” OR “Blue sclera syndrome” OR “Blue sclerotics and brittle bones” OR “Blue scleras and fragilitas osseum” OR “Brittle bones and blue sclerae” OR “Dark sclerotics and fragilitas osseum” OR “Periostal dysplasias” OR “Periostal dystrophia” OR “Eddowes disease” OR “Eddowes disease syndrome” OR “Ekman syndrome” OR “Ekman-Lobstein syndrome” OR “Fetal rickets” OR “Fragile bones” OR “Fragilitas ossium heriditaria tarda” OR “Fragilitas vitrea osseum” OR “Hereditary fibrous osteodysplasia” OR “Heriditary hypoplasia of the mesenchyme” OR “Lobstein's disease” OR “Molities osseum” OR “Osseous fragility” OR “Osteogenesis imperfecta congenita” OR “Osteogenesis imperfecta tarda” OR “Osteomyopathia” OR “Osteoporosis foetalis” OR “Osteitis parenchymatosa chronica” OR “Porak-Durante disease” OR “Rachitis congenita” OR “Spurway syndrome” OR “ Spurway-Eddowes syndrome” OR “Triad of Van der Hoeve” OR “Van der Hoeve syndrome” OR “Van der Hoeve-De Kleyn syndrome” OR “Vrolik's disease OR Vrolik's disease syndrome”

Source: Authors.

In Charts 1 is displayed the search strategy employed for in PubMed. Indexed terms (MeSH) and synonyms referring to malocclusion and osteogenesis imperfecta were used.

Hand searches were also performed of the reference lists of the studies included in the review and searches were performed in Google Scholar and OpenGrey, limited to the first 200 references in each database Haddaway, et al., 2015). Manual searches in the reference lists of included articles were also carried out. Duplicates were identified using the EndNote program (End Note®, Clarivate Analytics, Philadelphia, USA) and removed.

2.4 Selection of studies

Papers were selected by two independent reviewers (F.R. and H.V.P.) in two stages. Titles and abstracts were analyzed in the first stage and a high level of agreement was found between the two reviewers regarding the inclusion/exclusion of references (Kappa value: 0.908). In the second stage, references preselected based on the title and abstract were submitted to full-text analysis and those that met the eligibility criteria were included in the present review. Divergences of opinion between the reviewers were discussed with a third reviewer (S.A.T.) until a consensus was reached.

2.5 Data extraction

Two reviewers (F.R. and H.V.P.) extracted the following data from the articles included in the present review: authors, year of publication, type of OI, sex, age, medications used by the patients, characteristics of the occlusion, orthodontic treatment, surgical procedures, complications during and after surgery, follow-up period and outcomes.

2.6 Appraisal of methodological quality

The methodological quality of the studies included in the present review was appraised using the case report assessment tool proposed by the Joanna Briggs Institute. The items of interest were clarity in the description of the demographic characteristics, medical history, clinical status, results, treatment procedure, post-intervention clinical status, adverse events and recommendations furnished for the case. Each parameter was classified as "yes" (adequate description of item, indicating low risk of bias), "no" (inadequate description of item, indicating high risk of bias), "unclear" (unclear description of item) or "not applicable" (when the item did not apply to the case report) (Joanna Briggs Institute, 2017).

2.7 Synthesis of results

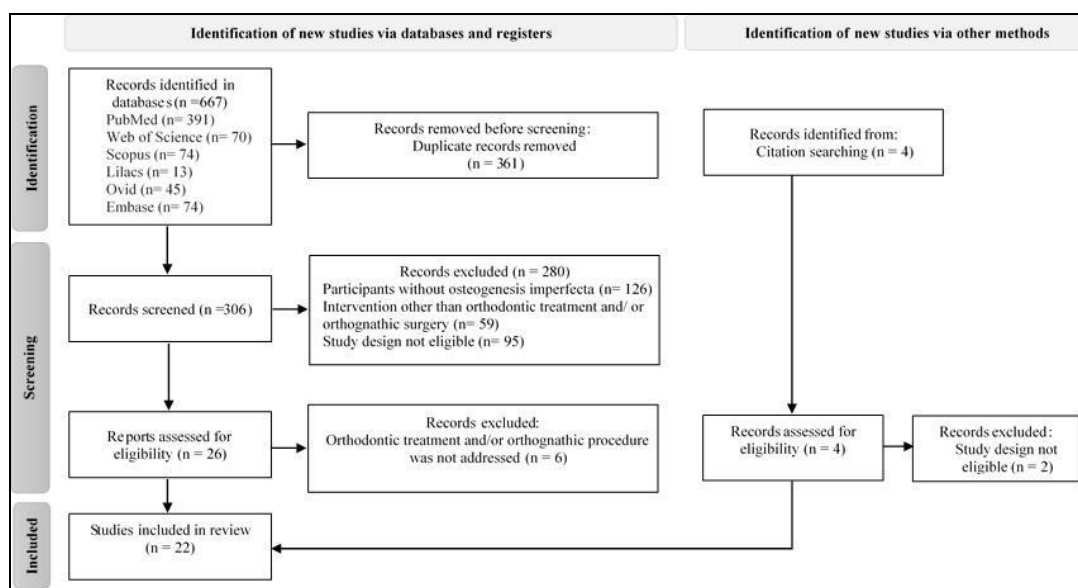
The results were synthesized qualitatively. Characteristics of the procedures and results were described for orthodontic treatment, orthognathic surgery and orthodontic treatment combined with orthognathic surgery.

3. Results

3.1 Selection of articles

The flowchart displayed in Figure 1 illustrates the article selection process.

Figure 1. Flowchart of the study selection process.



Source: Authors.

The flowchart (Figure 1) shows that the searches of the databases led to the retrieval of 667 publications. Searches in Google Scholar and OpenGrey did not yield any additional references. Four records had been identified in the reference lists of included articles. In addition, the flowchart (Figure 1) shows that after the selection process involving the analysis of the titles/abstracts and full texts, 22 case reports met the established eligibility criteria and were included in the present systematic review (Aizenbud, et al., 2008; Asai, et al., 2018; Bell & White, 2000; Binger, et al., 2006; Cole, et al., 1982; Freedus, et al., 1976; Friedrich, et al., 2019; Harstfield et al., 2006; Ierardo et al., 2015; Kim, et al., 2020; Kindelan et al., 2003; Kunkel, et al., 2019; Lewis & Stoker, 1987; López-Arcas et al., 2009; Morton, 1987; Ormiston & Tideman, 1995; Prince & Simpson, 2000; Rodrigo, 1995; Rosén, et al., 2011; Shimizu et al., 2005; Tashima et al., 2011; Whitestone & Chapnick, 1986).

3.2 Characteristics of articles included in review

The 22 articles reported 28 clinical cases. The articles were published between 1976 and 2020. Twenty-one were published in English and one was published in Japanese. The age of the patients with OI ranged from seven to 40 years. Sixteen patients were male and 12 were female. Regarding type of OI, 15 patients had type I (Aizenbud et al., 2008; Asai et al., 2018; Bell & White, 2000; Cole et al., 1982; Friedrich et al., 2019; Harstfield et al., 2006; Kim et al., 2020; Prince & Simpson, 2000; Rodrigo, 1995; Rosén et al., 2011; Shimizu et al., 2005; Tashima et al., 2011; Whitestone & Chapnick, 1986), two had type III (Lewis & Stoker, 1987; Ormiston & Tideman, 1995) and four had type IV (Harstfield et al., 2006; López-Arcas et al.,

2009; Kunkel et al., 2019; Rosén et al., 2011). The type of OI was not reported in seven cases (Binger et al., 2006; Freedus et al., 1976; Ierardo et al., 2015; Kindelan et al., 2003; Morton, 1987).

3.3 Results of studies included per treatment modality

3.3.1 Orthodontic treatment

Orthodontic treatment was performed in four cases (Harstfield et al., 2006; Ierardo et al., 2015). One case was a 12-year-old male adolescent with type I OI. The use of bisphosphonate was not reported. The patient had Angle class I occlusion, class I left and class II right molar relationship, diminished facial height and an augmented occlusal plane. The malocclusion was corrected with the use of a fixed appliance with progressive arches and posterior retainment using the Hawley retainer (Harstfield et al., 2006). In the other three cases (Ierardo et al., 2015), the type of OI and whether the patients took bisphosphonate were not reported. One case was a seven-year-old male child with Angle class I occlusion, class I right and class II left molar and canine relationship, inter-arch transverse discrepancy of 3.5 mm, unilateral posterior crossbite and left mandibular deviation. Rapid maxillary expansion was performed with six months of follow-up to observe the correction of the malocclusion. The other two cases were both male adolescents. The 15-year-old was diagnosed with Angle class III malocclusion, transverse inter-arch discrepancy of -3.5 mm, constriction of the maxillary arch, bilateral posterior crossbite and open bite. The 14-year-old had class III malocclusion, transverse inter-arch discrepancy of 4 mm and anterior crossbite. In both cases, the correction of the malocclusion was performed with rapid maxillary expansion for six months, followed by the use of the Delaire orthopedic face mask for 18 months (Ierardo et al., 2015).

3.3.2 Orthognathic surgery

Orthognathic surgery was performed in five cases and none of the articles reported an orthodontic intervention or the use of bisphosphonate (Binger et al., 2006; Freedus et al., 1976; Kunkel et al., 2019; Ormiston & Tideman, 1995; Rodrigo, 1995). One case was a 22-year-old woman with a late diagnosis of OI. The patient had Angle class III malocclusion and bilateral posterior crossbite, which was corrected using bilateral sagittal split osteotomy, with a seven-week period of maxillomandibular fixation. Dental prostheses were fabricated for oral rehabilitation (Freedus et al., 1976). In two case reports, retrusion of the maxilla was corrected with Le Fort I osteotomy. Osteotomy was also performed for the correction of mandibular protrusion, but the technique was not specified (Ormiston & Tideman, 1995; Rodrigo, 1995). One of these cases was a 23-year-old female patient with type I OI and a diagnosis of maxillary hypoplasia and mandibular prognathism (Rodrigo, 1995). The other case was a 23-year-old woman with type III OI and a diagnosis of class III malocclusion and open bite of 6 mm (Ormiston & Tideman, 1995).

Two cases were patients diagnosed with severe malocclusion (Binger et al., 2006; Kunkel et al., 2019). One was a 14-year-old male with type IV OI and a diagnosis of Angle class III malocclusion with severe maxillary hypoplasia and negative overjet of 20 mm (Kunkel et al., 2019). Osteogenic distraction was performed with rigid external device using the standard protocol and a posterior reverse traction device. The other case was a 32-year-old woman with a late diagnosis of OI. The patient had Angle class III malocclusion, severe maxillary hypoplasia and severe atrophy of the mandibular alveolar ridge in the frontal region. The correction of the malocclusion was performed with a Zurich pediatric maxillary distractor, bilateral lifting of the maxillary sinuses and an increase in the alveolar ridge of the mandible using autogenous bone from the iliac crest. Implant-supported dental prostheses were fabricated for oral rehabilitation (Binger et al., 2006).

3.3.3 Orthodontic treatment combined with orthognathic surgery

In 19 cases, the patients were diagnosed with Angle class III malocclusion, all of whom were submitted to orthodontic treatment combined with orthognathic surgery for the correction of the malocclusion (Aizenbud et al., 2008; Asai et al., 2018; Bell & White, 2000; Cole et al., 1982; Friedrich et al., 2019; Harstfield et al., 2006; Kim et al., 2020; Kindelan et al., 2003; Lewis & Stoker, 1987; López-Arcas et al., 2009; Morton, 1987; Rosén et al., 2011; Prince & Simpson, 2000; Shimizu et al., 2005; Tashima et al., 2011; Whitestone & Chapnick, 1986). Three patients took bisphosphonate at the onset of treatment (Asai et al., 2018; Friedrich et al., 2019; Rosén et al., 2011) and one of these patients also took calcitriol (Rosén et al., 2011). Seven patients had a diagnosis of type I OI and were between 19 and 40 years of age; five were men (Bell & White, 2000; Cole et al., 1982; Friedrich et al., 2019; Prince & Simpson, 2000; Shimizu et al., 2005; Tashima et al., 2011; Whitestone & Chapnick, 1986) and two were women (Rosén et al., 2011; Kim et al., 2020). One patient had type III OI (Lewis & Stoker, 1987) and two had type IV (Harstfield et al., 2006; López-Arcas et al., 2009), one of whom was 26 years of age (Harstfield et al., 2006). One of the reports failed to describe the type of OI (Morton, 1987).

Anterior open bite was diagnosed in ten patients ranging in age from 12 to 24 years (Cole et al., 1982; Friedrich et al., 2019; Kim et al., 2020; Lewis & Stoker, 1987; López-Arcas et al., 2009; Morton, 1987; Prince & Simpson, 2000; Tashima et al., 2011; Whitestone & Chapnick, 1986). Five patients exhibited class III malocclusion and posterior crossbite (Bell & White, 2000; Harstfield et al., 2006; Shimizu et al., 2005; Rosén et al., 2011). Two patients (both 17 years of age) were diagnosed with anterior open bite and bilateral posterior crossbite (Aizenbud et al., 2008; Kindelan et al., 2003). In one of these cases, the type of OI was not described (Kindelan et al., 2003) and the other case had type I (Aizenbud et al., 2008). Malocclusion was considered severe in nine cases, with records of negative overjet ranging from nine to 26 mm (Asai et al., 2018; Kindelan et al., 2003; Lewis & Stoker, 1987; López-Arcas et al., 2009; Prince & Simpson, 2000; Rosén et al., 2011; Shimizu et al., 2005; Tashima et al., 2011).

In 11 patients, alignment and leveling of the teeth was performed prior to orthognathic surgery (Aizenbud et al., 2008; Asai et al., 2018; Bell & White, 2000; Kim et al., 2020; Kindelan et al., 2003; Lewis & Stoker, 1987; Morton, 1987; Rosén et al., 2011; Shimizu et al., 2005). Decompensation of the incisors was performed in two of these cases (Aizenbud et al., 2008; Kindelan et al., 2003) and expansion of the maxillary arch was performed in one case (Aizenbud et al., 2008).

Three patients required tooth extractions (Cole et al., 1982; Friedrich et al., 2019; Tashima et al., 2011). In one case, orthodontic treatment was not reported, but the illustrations referring to the presurgical period showed the presence of a fixed appliance (Whitestone & Chapnick, 1986).

The period of orthodontic treatment for adjustment of the occlusion after surgery was reported in 13 cases and ranged from three weeks to 18 months (Aizenbud et al., 2008; Asai et al., 2018; Bell & White, 2000; Harstfield et al., 2006; Kim et al., 2020; Kindelan et al., 2003; Lewis & Stoker, 1987; López-Arcas et al., 2009; Prince & Simpson, 2000; Rosén et al., 2011; Shimizu et al., 2005). Two patients used elastics for intercuspatation of the teeth and the finalization of treatment (Friedrich et al., 2019; Prince & Simpson, 2000). In two other cases, retention was used after the conclusion of treatment (Harstfield et al., 2006; Kindelan et al., 2003).

During the surgical step, maxillary osteotomy was performed on the Le Fort I plane to advance the maxilla in 15 patients (Aizenbud et al., 2008; Asai et al., 2018; Bell & White, 2000; Cole et al., 1982; Friedrich et al., 2019; Harstfield et al., 2006; Kim et al., 2020; Kindelan et al., 2003; López-Arcas et al., 2009; Morton, 1987; Prince & Simpson, 2000; Rosén et al., 2011; Tashima et al., 2011). Bilateral sagittal split osteotomy was performed in nine cases for the retrusion of the protracted mandible (Harstfield et al., 2006; Kim et al., 2020; Lewis & Stoker, 1987; López-Arcas et al., 2009; Prince & Simpson, 2000; Shimizu et al., 2005; Tashima et al., 2011). Seven patients were submitted to bilateral vertical ramus osteotomy (Aizenbud et al., 2008; Asai et al., 2018; Cole et al., 1982; Friedrich et al., 2019; Rosén et al., 2011; Whitestone & Chapnick, 1986). The

type of osteotomy performed on the mandible was not specified in two cases (Kindelan et al., 2003; Kindelan et al., 2003). Genioplasty was performed to augment the chin in three patients (Friedrich et al., 2019; Harstfield et al., 2006; Morton, 1987). In 14 cases, the maxillomandibular fixation time ranged from two to six weeks (Aizenbud et al., 2008; Cole et al., 1982; Freedus et al., 1976; Kim et al., 2020; López-Arcas et al., 2009; Prince & Simpson, 2000; Rosén et al., 2011; Shimizu et al., 2005; Tashima et al., 2011; Whitestone & Chapnick, 1986).

In 11 cases, considerable blood loss during surgery was reported (Asai et al., 2018; Bell & White, 2000; Cole et al., 1982; Kim et al., 2020; Lewis & Stoker, 1987; Shimizu et al., 2005; Rosén et al., 2011; Tashima et al., 2011). Two patients had continuous hemorrhage and required blood and/or plasma transfusion (Asai et al., 2018; Morton, 1987). Postoperative complications were reported in six cases: negative-pressure pulmonary edema (Asai et al., 2018), detachment of the fixation screw from the mandibular bone (Shimizu et al., 2005), bleeding in the scar tissue of the maxilla (Rosén et al., 2011), facial edema and hematomas (Morton, 1987). Pneumonia, profuse epistaxis, seizures and respiratory arrest were reported in one patient (Cole et al., 1982). Subconjunctival hemorrhage, ecchymosis and abnormal edema were reported in another case (Kim et al., 2020).

In most cases, improvements occurred in facial esthetics and/or stability of the occlusion (Aizenbud et al., 2008; Asai et al., 2018; Bell & White, 2000; Binger et al., 2006; Cole et al., 1982; Freedus et al., 1976; Friedrich et al., 2019; Harstfield et al., 2006; Kim et al., 2020; Kindelan et al., 2003; Kunkel et al., 2019; Lewis & Stoker, 1987; López-Arcas et al., 2009; Prince & Simpson, 2000; Rosén et al., 2011; Shimizu et al., 2005). In the reports that described the follow-up time of the patients, the period ranged from six months to nine years (Aizenbud et al., 2008; Asai et al., 2018; Bell & White, 2000; Binger et al., 2006; Cole et al., 1982; Freedus et al., 1976; Friedrich et al., 2019; Harstfield et al., 2006; Kim et al., 2020; Kindelan et al., 2003; Kunkel et al., 2019; Lewis & Stoker, 1987; López-Arcas et al., 2009; Rosén et al., 2011; Shimizu et al., 2005). In one of the cases, the patient did not appear for the follow-up appointments, but returned after six years seeking treatment for relapse of the malocclusion (Tashima et al., 2011). In four cases, the follow-up of the patients was not mentioned (Rodrigo, 1995; Morton, 1987; Ormiston & Tideman, 1995; Whitestone & Chapnick, 1986).

3.4 Methodological quality of case reports

The results of the methodological quality appraisal are displays in Charts 2.

Charts 2. Critical assessment of the methodological quality of the included case reports.

Author(s), year of publication	Q 1	Q 2	Q 3	Q 4	Q 5	Q 6	Q 7	Q 8
Freedus & Chaaf, 1976	Yes	Yes	Yes	Unclear	Yes	Unclear	Yes	Yes
Cole et al., 1982	Yes	Yes	Yes	Yes	Yes	Yes	Yes	Yes
Whitestone & Chapnick, 1986	Yes	Yes	Yes	No	Unclear	No	Yes	Yes
Lewis & Stocker, 1987	Yes	Yes	Yes	Yes	Yes	Yes	Yes	Yes
Morton et al., 1987	Unclear	Yes	Yes	Yes	Yes	Yes	Yes	Yes
Rodrigo, 1995	Yes	Yes	Yes	No	Unclear	No	Yes	Yes
Ormiston & Tideman, 1995	Yes	Yes	Yes	Unclear	Unclear	No	Yes	Yes
Bell & Branco, 2000	Yes	Yes	Yes	Yes	Yes	Yes	Yes	Yes
Prince & Simpson, 2000	Yes	Yes	Yes	Yes	Yes	Yes	Yes	Yes
Kindelan et al., 2003	Unclear	Yes	Yes	Yes	Yes	Yes	Yes	Yes
Shimizu et al., 2005	Yes	Yes	Yes	Yes	Yes	Yes	Yes	Yes
Hartsfield et al., 2006	Yes	Yes	Yes	Yes	Yes	Yes	Yes	Yes
Binger et al., 2006	Yes	Yes	Yes	Yes	Yes	Yes	Yes	Yes
Aizenbud et al., 2008	Yes	Yes	Yes	Yes	Yes	Yes	Yes	Yes
Lopez-Arcas et al., 2009	Yes	Yes	Yes	Yes	Yes	Yes	Yes	Yes
Rosén et al., 2011	Yes	Yes	Yes	Yes	Yes	Yes	Yes	Yes
Tashima et al., 2011	Yes	Yes	Yes	Yes	Yes	Yes	Yes	Yes
Ierardo et al., 2015	Unclear	Yes	Yes	Yes	Yes	Yes	Yes	Yes
Asai et al., 2018	Yes	Yes	Yes	Yes	Yes	Yes	Yes	Yes
Kunkel et al., 2019	Yes	Yes	Yes	Yes	Yes	Yes	Yes	Yes
Friendich et al., 2019	Yes	Yes	Yes	Yes	Yes	Yes	Yes	Yes
Kim et al., 2020	Yes	Yes	Yes	Yes	Yes	Yes	Yes	Yes

Question 1. Patient's demographic characteristics clearly described? Question 2. Patient's history clearly described? Question 3. Description of the current clinical condition of the patient? Question 4. Results clearly described? Question 5. Treatment procedure(s) clearly described? Question 6. The post-intervention clinical condition clearly described? Question 7. Identification of adverse events or unanticipated events? Question 8. Case report provide takeaway lessons? Source: Authors

In Chart 2 is possible to visualize that the methodological quality of the articles was satisfactory. All 22 articles clearly described the patient history and current clinical status. Adverse and unforeseen events were also described during care for the patients with OI, along with treatment recommendations (Aizenbud et al., 2008; Asai et al., 2018; Bell & White, 2000; Binger et al., 2006; Cole et al., 1982; Freedus et al., 1976; Friedrich et al., 2019; Ierardo et al., 2015; Harstfield et al., 2006; Kim et al., 2020; Kindelan et al., 2003; Kunkel et al., 2019; Lewis & Stoker, 1987; López-Arcas et al., 2009; Rodrigo, 1995; Rosén et al., 2011; Morton, 1987; Ormiston & Tideman, 1995; Shimizu et al., 2005; Tashima et al., 2011; Whitestone & Chapnick, 1986). Three studies were unclear regarding the demographic characteristics of the cases (Ierardo et al., 2015; Kindelan et al., 2003; Morton, 1987) and the description of the procedures (Rodrigo, 1995; Whitestone & Chapnick, 1986; Ormiston & Tideman, 1995). In two articles, there was no information on the results of treatment (Whitestone & Chapnick, 1986; Ormiston & Tideman, 1995). In another study, the results were described unclearly (Freedus et al., 1976).

4. Discussion

According to previous studies, the prevalence of malocclusion is high among individuals diagnosed with OI and the frequency and severity vary significantly among the different types of the disease (Hidalgo-Perea & Green, 2021; Rizkallah et al., 2013; Retrouvey et al., 2019; Prado et al., 2022). Besides the systemic clinical consequences caused by OI, the high prevalence of malocclusion can affect the functioning of the stomatognathic system in this portion of the population. Problems involving speech, respiration, chewing and facial esthetics exert a negative impact on the quality of life of these individuals (Sun, et al., 2017).

A recent systematic review found that class III malocclusion with anterior crossbite is the more frequently found in individuals with OI compared to individuals without this disease (Prado et al., 2022). The growth of all craniofacial bones is affected by OI due to defects in intramembranous or endochondral ossification. The maxilla is hypoplastic due to the compromised bone remodeling mechanisms as well as the sliding and movement of this bone. Inadequate bone remodeling and sliding compromise the movement of the maxilla in the anterior and inferior directions. A primary growth defect in the base of the skull also causes deficiency in the movement of the maxilla in these directions. Another cause of maxillary growth deficiency is the early calcification of the fibrous connective tissue or premature fusion of the sutures of the middle third of the face (Waltimo-Sirén et al., 2005). The vertical underdevelopment of dental-alveolar structures and the condylar process results in the counterclockwise rotation of the mandible. The combination of these conditions causes Angle class III malocclusion and a negative sagittal relationship between the maxilla and mandible (Rizkallah et al., 2013; Waltimo-Sirén et al., 2005). Class III malocclusion is generally much milder in individuals with type I OI (Friedrich et al., 2019).

Although the identification of the type of malocclusion in OI is well established in the scientific literature, there continues to be a gap in knowledge regarding the orthodontic/orthopedic therapeutic approach. As a rare disease with bone involvement and therapy involving the use of bisphosphonates, it is necessary for dentists to have deeper knowledge regarding the conduction of dental treatment for these individuals. Bisphosphonates inhibit osteoclastic activity and diminish microcirculation, consequently diminishing bone resorption (Lotwala, et al., 2012; Rinchuse, et al., 2017). Therefore, these drugs can compromise the orthodontic movement of the teeth, which depends on the process of bone resorption and apposition (Friedrich et al., 2019; Krieger, et al., 2013; Lotwala et al., 2012).

The 22 articles included in the present systematic review (Aizenbud et al., 2008; Asai et al., 2018; Bell & White, 2000; Binger et al., 2006; Cole et al., 1982; Freedus et al., 1976; Friedrich et al., 2019; Harstfield et al., 2006; Ierardo et al., 2015; Kim et al., 2020; Kindelan et al., 2003; Kunkel et al., 2019; Lewis & Stoker, 1987; López-Arcas et al., 2009; Morton, 1987; Ormiston & Tideman, 1995; Prince & Simpson, 2000; Rodrigo, 1995; Rosén et al., 2011; Shimizu et al., 2005; Tashima et al., 2011; Whitestone & Chapnick, 1986) reported cases with variable characteristics and heterogenous procedures, demonstrating the viability of orthodontic treatment and/or orthognathic surgery for individuals with OI. Orthodontic/orthopedic treatment can lead to satisfactory results for the correction of milder malocclusions (Retrouvey et al., 2019). In children and adolescents with OI, transverse maxillary deficiency, which is very common, can be corrected with rapid maxillary expansion (Ierardo et al., 2015; Suri & Taneja, 2008). In cases of a negative sagittal relationship between the maxilla and mandible due to maxillary deficiency, the protraction of this bone base (often combined with rapid maxillary expansion) is the most indicated treatment for patients in the growing phase (Vaughn, et al., 2005). Devices such as orthopedic face masks can be used as extraoral anchorage for maxillary protraction (Tortop, et al., 2007; Vaughn et al., 2005). Thus, the interceptive orthopedic approach is a treatment modality for dental-skeletal abnormalities in patients with OI still in the growing phase (Harstfield et al., 2006; Ierardo et al., 2015).

Osteonecrosis related to the use of bisphosphonates is a possible adverse event that requires special attention during orthopedic treatment, which involves bone movement and the opening of maxillary sutures. However, few studies have evaluated the influence of medication with bisphosphonates on orthodontic therapy in patients with OI. According to Friedrich (2019), it is possible to perform orthopedic/orthodontic treatment on patients taking bisphosphonates, but the application of larger forces and longer periods of time between return appointments are needed. Ierardo et al. (2013) described three clinical cases of children/adolescents with OI in the initial and late mixed dentition phases. The cases had an indication for treatment with rapid maxillary expansion due to class III malocclusion and unilateral posterior crossbite. The patients took intravenous bisphosphonates. Among the individuals with class III malocclusion, the Delaire face mask was used after rapid maxillary expansion, with the application of orthopedic forces similar to those in the standard protocol for typical patients. In the cases

presented, the decision was made to discontinue the use of bisphosphonates during the active phase of rapid maxillary expansion, which is a common consensus among the medical team of the patients. The medication was reinstated after six months (approximately at the end of the passive retention phase of the expander). According to the authors, the medication was suspended to facilitate the opening of the median palatine suture. No complications were found after one year of follow-up.

In adults, orthodontic treatment can be performed with fixed appliances, which enable significant dental movement and permit compensation for skeletal discrepancies that are not very severe. The occurrence of dentinogenesis imperfecta and bulbous crowns, which are typical findings in individuals with OI, are characteristics that should be observed when planning for the placement of the orthodontic accessories. Such dental abnormalities can hinder the bonding of the bands and brackets as well as the maintenance of these components on the tooth structure when the appliance is activated and orthodontic forces are applied (Harstfield et al., 2006). On molars with fractures and accentuated wear due to dentinogenesis imperfecta, stainless steel crowns may be an option for the temporary reestablishment of the tooth anatomy, maintaining the vertical dimension of occlusion and facilitating the bonding of the orthodontic accessory on these teeth. When treatment is concluded, the removal of the orthodontic accessories should be performed cautiously to avoid further damage to the teeth (Harstfield et al., 2006; Kindelan et al., 2003). Individuals with OI also have short tooth roots. The control of short roots submitted to orthodontic forces should be performed with radiographs throughout treatment.

In adults with severe skeletal discrepancies, the isolated use of a fixed appliance is insufficient for the treatment of malocclusion. Thus, the combination of orthodontic treatment and orthognathic surgery is often required for the correction of these accentuated deficiencies (Starch-Jensen & Blæhr, 2016; Suri & Taneja, 2008). The sequence of treatment normally involves alignment and leveling of the teeth and decompensation with fixed appliances. The individual is subsequently submitted to orthognathic surgery (while still wearing the appliances) for the correction of the skeletal discrepancy. Finally, small dental movements are performed with fixed appliances and intermaxillary elastics for intercuspatation of the teeth, adjustments to the occlusion and the finalization of the case.

Orthognathic surgery may be restricted to the maxilla or mandible. However, intervention in both bone bases may be necessary. Le Fort I osteotomy is the most widely used surgical procedure to promote the advancement of a deficient maxilla (Starch-Jensen & Blæhr, 2016). For severe skeletal discrepancies, osteogenic distraction is a therapeutic possibility that can also be used for the correction of deformities in the middle third of the face (Kunkel et al., 2019; McCarthy et al., 2001).

According to Binger (2006) and Kunkel et al. (2019), osteogenic distraction is an alternative to conventional Le Fort I orthognathic surgery in patients with OI, as this technique involves a lower risk of an atypical fracture because it does not require a bone fracture procedure during its execution (Binger et al., 2006; Kunkel et al., 2019). In the case reported by Binger (2006), osteogenic distraction was performed on a 32-year-old patient with OI using a Zurich pediatric maxillary distractor. Kunkel et al. (2019) reported the use of a rigid external distractor in a 14-year-old patient with type IV OI using the standard protocol of the method. In both studies, there were no reports of any complications at the end of the follow-up period. Another important point to consider is the fact that the use of external appliances enables better control of the distraction (Efunkoya et al., 2014; Kunkel et al., 2019).

Sagittal split osteotomy and vertical ramus osteotomy were the most frequent surgical procedures for the correction of mandibular prognathism. Each technique has its indications and limitations (Kawase-Koga et al., 2016; Ghali & Sikes, 2000; Verweij, et al., 2016). It should be stressed that individuals with OI have very thin, porous cortical bone (Aizenbud et al., 2008; Bell & White, 2000; Cole et al., 1982; Ormiston & Tideman, 1995), which reduces the resistance to the osteotome, hindering the cleavage of the bone (Bell & White, 2000). Moreover, bone frailty can hinder rigid maxillomandibular fixation and prolong the fixation time (Harstfield et al., 2006; Tashima et al., 2011).

Resistance to external forces or fractures depends on the quantity and quality of bone tissue. Thus, individuals with OI are at increased risk for the occurrence of fractures. The incidence of fractures is greater in childhood, with a tendency toward a reduction after puberty (Harrington, et al., 2014; Bachrach & Ward, 2009). In cases of severe skeletal impairment, care must be taken to avoid pathological fracture of the mandible due to generalized osteoporosis (Aizenbud et al., 2008). Therefore, the diagnosis should be based on a clinical examination and complementary exams, as precision in orthodontic movements and surgical procedures is crucial to achieving good results.

The systemic peculiarities of OI predisposes affected individuals to complications during and after orthognathic surgery (Asai et al., 2018; Bell & White, 2000; Cole et al., 1982; Friedrich et al., 2019; Lewis & Stoker, 1987; Ormiston & Tideman, 1995; Tashima et al., 2011). Clotting abnormalities and the frailty of the vascular wall can result in hemorrhage (Asai et al., 2018; Kindelan et al., 2003; Lewis & Stoker, 1987; Rodrigo, 1995; Ormiston & Tideman, 1995; Tashima et al., 2011). Metabolic defects are manifested in various ways in these individuals, with a tendency toward hyperthermia under anesthesia and an increased risk for malignant hyperthermia (Aizenbud et al., 2008; Bell & White, 2000; Cole et al., 1982; Harstfield et al., 2006; Kindelan et al., 2003; Rosén et al., 2011). Thoracic deformity can hinder intubation (Kindelan et al., 2003; Rodrigo, 1995). Bone healing can be compromised due to the use of bisphosphonates as well as the occurrence of osteonecrosis (Kawase-Koga et al., 2016; Kim et al., 2020). Thus, orthodontic treatment should be planned rigorously for individuals with OI who will also need orthognathic surgery due to severe malocclusion.

The present systematic review has limitations that should be considered. Only case reports with successful results were included. Case reports have a low level of scientific evidence. However, a rare disease does not enable the execution of a study with a representative sample. In such situations, case reports provide important information for clinical practice.

The majority of case reports included in the present systematic review described the cases and relevant details clearly, demonstrating that interceptive orthodontics is a viable treatment option for children and adolescents with OI and can avoid the need for the surgical correction of severe malocclusion in adulthood. In adults, orthodontic treatment with a fixed appliance (combined or not with orthognathic surgery) is a viable option for the reestablishment of the balance of the craniofacial complex as well as improvements in facial esthetics and stabilization of the occlusion. The extreme phenotypic variability of these patients makes each case unique, requiring individualized care and potentially variable results. The synthesis of these reports with satisfactory results is relevant, as it shows that the correction of malocclusion in individuals with OI is possible, despite the systemic complexities that this population exhibits.

5. Conclusion

The cases analyzed showed that the treatment of malocclusion is viable for individuals with OI. When duly indicated, treatment can be performed with orthodontic treatment, orthognathic surgery or a combination of both, providing satisfactory esthetic and functional results with adequate stability.

Studies with greater scientific evidence regarding intervention on malocclusion in individuals with OI should be conducted.

Acknowledgments

This study was financed in part by the *Fundação de Amparo à Pesquisa do Estado de Minas Gerais- Brasil* (FAPEMIG); *Coordenação de Aperfeiçoamento de Pessoal de Nível Superior - Brasil* (CAPES) - Finance Code 001; *Conselho Nacional de Desenvolvimento Científico e Tecnológico- Brasil* (CNPq); and *Pró-Reitoria de Pesquisa da Universidade*

Federal de Minas Gerais (PRPq/UFGM). Lucas Guimarães Abreu is a recipient of a fellowship from CNPq for his research merit (404710/2018-2 and 310797/2019-5).

Conflict of interest

All authors declare that they have no conflict of interest.

References

- Abukabbos, H., & Al-Sineedi, F. (2013). Clinical manifestations and dental management of dentinogenesis imperfecta associated with osteogenesis imperfecta: Case report. *The Saudi Dental Journal*, 25(4), 159–165.
- Aizenbud, D., Peled, M., & Figueroa, A. A. (2008). A combined orthodontic and surgical approach in osteogenesis imperfecta and severe Class III malocclusion: case report. *Journal of oral and maxillofacial surgery*, 66(5), 1045-1053.
- Alharbi, S. A. (2015). A Systematic overview of Osteogenesis Imperfecta. *Molecular Biology*, 4(150), 10.4172/2168-9547.1000150.
- Andersson, K., Dahllöf, G., Lindahl, K., Kindmark, A., Grigelioniene, G., Eva Åström, E., & Malmgren, B. (2017). Mutations in COL1A1 and COL1A2 and dental aberrations in children and adolescents with osteogenesis imperfecta—a retrospective cohort study. *PLoS One*, 12(5), e0176466.
- Asai, K., Sonobe, J., Yamashita, K., & Bessho K. (2018). Negative pressure pulmonary edema after orthognathic surgery for osteogenesis imperfecta. *Journal of Oral and Maxillofacial Surgery, Medicine, and Pathology*, 30(4), 342-345.
- Bachrach, L. K., & Ward, L. M. (2009). Clinical Review 1: Bisphosphonate Use in Childhood Osteoporosis. *Journal of clinical endocrinology & metabolism*, 94(2), 400-409.
- Bell, R. B., & White, R. P. (2000). Osteogenesis imperfecta and orthognathic surgery: case report with long-term follow-up. *The International journal of adult orthodontics and orthognathic surgery*, 15(3), 171-178.
- Binger, T., Rücker, M., & Spitzer W. J. (2006). Dentofacial rehabilitation by osteodistraction, augmentation and implantation despite osteogenesis imperfecta. *International journal of oral and maxillofacial surgery*, 35(6), 559-562.
- Chang, P. C., Lin, S. Y., & Hsu, K. H. (2007). The craniofacial characteristics of osteogenesis imperfecta patients. *The European Journal of Orthodontics*, 29(3), 232-237.
- Cole, N. L., Goldberg, M. H., Loftus, M., & Kwok, V. (1982). Surgical management of patients with osteogenesis imperfecta. *Journal of Oral and Maxillofacial Surgery*, 40(9), 578-584.
- Deguchi, M., Tsuji, S., Katsura, D., Kasahara, K., Kimura, F. & Murakami T. (2021). Current Overview of Osteogenesis Imperfecta. *Medicina (Kaunas)*, 57(5), 464. 10.3390/medicina57050464.
- Efunkoya, A. A., Bamgbose, B. O., Adebola, R. A., Adeoye, J. B. & Akpasa, I. O. (2014). Maxillomandibular distraction osteogenesis. *Journal of Craniofacial Surgery*, 25(5), 1787-1792.
- Freedus, M. S., Schaaf, N. G., & Ziter, W. D. (1976). Orthognathic surgery in osteogenesis imperfecta. *Journal of oral surgery*, 34(9), 830-834.
- Friedrich, R. E., Scheuer, H. A., & Hölzje, W. (2019). The effect of bisphosphonate medication on orthodontics and orthognathic surgery in patients with osteogenesis imperfecta. *GMS Interdisciplinary plastic and reconstructive surgery DGPW*, 8(6). 10.3205/iprs000132
- Ghali, G. E., & Sikes, J. W. (2000). Intraoral vertical ramus osteotomy as the preferred treatment for mandibular prognathism. *Journal of Oral and Maxillofacial Surgery*, 58(3), 313-315.
- Gorlin, R. J., Cohen, M. M., & Hennekam, R. C. M. (2001). *Syndromes affecting bone: The Osteogenesis Imperfecta*. New York, EUA: Oxford University Press.
- Haddaway, N. R., Collins, A. M., Coughlin, D., & Kirk S. (2015). The role of Google Scholar in evidence reviews and its applicability to grey literature searching. *PLoS one*, 10(9), e0138237.
- Harrington, J., Sochett, E., & Howard, A. (2014). Update on the evaluation and treatment of osteogenesis imperfecta. *Pediatric clinics of North America*, 61(6), 1243-1257.
- Harstfield, J. R., Hohlt, W. F., & Roberts, W. E. (2006). Orthodontic treatment and orthognathic surgery for patients with osteogenesis imperfect. *Seminars in Orthodontics*, 12(4), 254-271.
- Hidalgo-Perea, S., & Green, D. W. Osteogenesis imperfecta: treatment and surgical management. (2021). *Current opinion in pediatrics*, 33(1), 74-78. 10.1097/MOP.0000000000000968.
- Huber, M. A. (2007). Osteogenesis imperfecta. *Oral surgery, oral medicine, oral pathology, oral radiology, and endodontics*, 103, 314-320.
- Ierardo, G., Calcagnile, F., Luzzi, V., Ladniak, B., Bossu, M., Celli, M., & Polimeni, A. (2015). Osteogenesis imperfecta and rapid maxillary expansion: Report of 3 patients. *American Journal of Orthodontics and Dentofacial Orthopedics*, 148(1), 130-137.

Joanna Briggs Institute. (2017). *Joanna Briggs Institute Reviewers' Manual*. Australia: The Joanna Briggs Institute.

Kawase-Koga, Y., Mori, Y., Fujii, Y., Kanno, Y., Chikazu, D., Susami, T., & Takato, T. (2016). Complications after intraoral vertical ramus osteotomy: relationship to the shape of the osteotomy line. *International journal of oral and maxillofacial surgery*, 45(2), 200-204.

Kim, D. Y., Baik, U., & Jeon, J. H. (2020). Osteogenesis imperfecta and combined orthodontics and orthognathic surgery: a case report on two siblings. *Journal of the Korean Association of Oral Maxillofacial Surgeons*, 46(1), 70-77.

Kindelan, J., Tobin, M., Roberts-Harry, D., & Loukota, R.A. (2003). Orthodontic and orthognathic management of a patient with osteogenesis imperfecta and dentinogenesis imperfecta: a case report. *Journal of Orthodontics*, 30(4), 291-296.

Krieger, E., Jacobs, C., Walter, C., & Wehrbein H. (2013). Current state of orthodontic patients under bisphosphonate therapy. *Head & face medicine*, 9(1), 10.

Kunkel, R., Kim, E., Tuncer, F. B., Siddiqi, F., & Gociman, B. (2019). Maxillary Distraction Osteogenesis in a Patient with Osteogenesis Imperfecta. *Journal of Craniofacial Surgery*, 30(8), 2530-2532.

Lewis, M. K., & Stoker, N. G. (1987). Surgical management of the patient with osteogenesis imperfecta. *Journal of oral and maxillofacial surgery*, 45(5), 430-437.

López-Arcas, J. M., Chamorro, M., Del Castillo, J. L., Cebrián, J. L., Palacios, E., & Burgueño M. (2009). Osteogenesis imperfecta and orthognathic surgery: case report and literature review. *Journal of oral and maxillofacial surgery*, 67(5), 1128-1132.

Kunkel, R., Kim, E., Tuncer, F. B., Siddiqi, F., & Gociman, B. (2019). Maxillary Distraction Osteogenesis in a Patient with Osteogenesis Imperfecta. *Journal of Craniofacial Surgery*, 30(8), 2530-2532.

Lewis, M. K., & Stoker, N. G. (1987). Surgical management of the patient with osteogenesis imperfecta. *Journal of oral and maxillofacial surgery*, 45(5), 430-437.

López-Arcas, J. M., Chamorro, M., Del Castillo, J. L., Cebrián, J. L., Palacios, E., & Burgueño M. (2009). Osteogenesis imperfecta and orthognathic surgery: case report and literature review. *Journal of oral and maxillofacial surgery*, 67(5), 1128-1132.

Lotwala, R. B., Greenlee, G. M., Ott, S. M., Hall, S. H., & Huang, G. J. (2012). Bisphosphonates as a risk factor for adverse orthodontic outcomes: a retrospective cohort study. *American journal of orthodontics and dentofacial orthopedics*, 142(5), 625-634.

McCarthy, J. G., Stelnicki, E. J., Mehrara, B. J., & Longaker, M. T. (2001). Distraction osteogenesis of the craniofacial skeleton. *Plastic and Reconstructive Surgery*, 107(7), 1812-1827.

Morton, E. (1987). Excessive bleeding after surgery in osteogenesis imperfecta. *Journal of Oral and Maxillofacial Surgery*, 25, 507-511.

Nguyen, M. S., Binh, H. D., Nguyen, K. M., Maasalu, K., Kõks, S., Märtsen, A., & Jagomägi, T. (2017). Occlusal features and need for orthodontic treatment in persons with osteogenesis imperfecta. *Clinical and experimental dental research*, 3(1), 19-24. doi: 10.1002/cre2.53.

O'Connell, A. C., & Marini, J. C. (1999). Evaluation of oral problems in an osteogenesis imperfecta population. *Oral surgery, oral medicine, oral pathology, oral radiology, and endodontics*, 87, 189-196.

Okawa, R., Kubota, T., Kitaoka, T., Kokomoto, K., Ozono, K., & Nakano, K. (2017). Oral manifestations of Japanese patients with osteogenesis imperfecta. *Pediatric Dental Journal*, 27(2), 73-78.

Ormiston, I. W., & Tideman, H. (1995). Orthognathic surgery in osteogenesis imperfecta: a case report with management considerations. *Journal of cranio maxillo-facial surgery*, 23(4), 261-265.

Page, M. J., McKenzie, J. M., Bossuyt P. M., Boutron, I., Hoffmann, T. V., Mulrow, C. D., & Moher, D. (2021). The PRISMA 2020 statement: an updated guideline for reporting systematic reviews. *BMJ: British medical journal / British Medical Association*, 372(71).

Prado, H. V., Teixeira, S. A., Rabello, F., Vargas-Ferreira, F., Borges-Oliveira, A. C., & Abreu, L. G. (2022). Malocclusion in individuals with osteogenesis imperfecta: A systematic review and meta-analysis. *Oral Diseases*, 28(2), 314-325.

Prince, S. E., & Simpson, M. T. (2000). Osteogenesis imperfecta. *British Journal of Oral & Maxillofacial Surgery*, 4(38), 399-400.

Rauch, F., & Glorieux, F. H. (2004). Osteogenesis imperfecta. *The Lancet*, 363(9418), 1377-1385.

Retrouvey, J. M., Taqi, D., Tamimi, F., Dagdeviren, D., Glorieux, F. H., Lee, B., & Esposito, P. (2019). Oro-dental and cranio-facial characteristics of osteogenesis imperfecta type V. *European journal of medical genetics*, 62(12), 103606.

Rinchuse, D. J., Sosovicka, M. F., Robison, J. M., & Pendleton R. (2017). Orthodontic treatment of patients using bisphosphonates: a report of 2 cases. *American Journal of Orthodontics Dentofacial Orthopedics*, 131(3), 321-326.

Rizkallah, J., Schwartz, S., Rauch, F., Glorieux, F., Vu, D. D., Muller, K., & Retrouvey, J. M. (2013). Evaluation of the severity of malocclusions in children affected by osteogenesis imperfecta with the peer assessment rating and discrepancy indexes. *American Journal of Orthodontics and Dentofacial Orthopedics*, 143(3), 336-341.

Rodrigo, C. (1995). Anesthesia for maxillary and mandibular osteotomies in osteogenesis imperfecta. *Anesthesia Progress*, 42(1), 17-20.

Rosén, M., Moding, M., & Larson O. (2011). Orthognathic bimaxillary surgery in two patients with osteogenesis imperfecta and a review of the literature. *International Journal of oral and maxillofacial surgery*, 40(8), 866-873.

Rousseau, M., & Retrouvey, J. M. (2018). Osteogenesis imperfecta: potential therapeutic approaches. *Peer J*, 6, e5464.

Subramanian, S., & Viswanathan, V. K. (2022). *Osteogenesis Imperfecta*. Treasure Island, EUA: StatPearls [Internet]. <https://www.ncbi.nlm.nih.gov/books/NBK536957/>

Shimizu, T., Takahashi, K., Murakami, K. I., Takafuji, H., Yokoe, Y., Iizuka, T., & Bessho, K. (2005). A case of sagittal splitting ramus osteotomy in osteogenesis imperfecta with mandibular prognathism. *Jpn Journal Jaw Deformities*, 15(3), 133-9.

Starch-Jensen, T., & Blæhr, T. L. (2016). Transverse expansion and stability after segmental Le fort I osteotomy versus surgically assisted rapid maxillary expansion: a systematic review. *Journal of oral & maxillofacial research*, 7(4).

Sun, L., Wong, H. M., & Mcgrath, C. P. (2017). Relationship between the severity of malocclusion and oral health related quality of life: A systematic review and meta-analysis. *Oral Health and Preventive Dentistry*, 15(6), 503-517.

Suri, L., & Taneja P. (2008). Surgically assisted rapid palatal expansion: A literature review. *American Journal of Orthodontics and Dentofacial Orthopedics*, 133(2), 290-302.

Tashima, H., Wattanawong, K., Ho, C. T., Wen-Ching-Ko, E., Nguyen, A., & Lo, L. J. (2011). Orthognathic surgery considerations for patients with undiagnosed type I osteogenesis imperfecta. *Journal of oral and maxillofacial surgery*, 69(8), 2233-2241.

Tortop, T., Keykubat, A., & Yuksel S. (2007). Facemask therapy with and without expansion. *American Journal of Orthodontics and Dentofacial Orthopedics*, 132(4), 467-474.

Valadares, E. R., Carneiro, T. B., Santos, P. M., Oliveira, A. C., & Zabel, B. (2014). What is new in genetics and osteogenesis imperfecta classification? *Jornal de pediatria*, 90(6), 536-541.

Van Dijk, F. S., & Sillence, D. O. (2014). Osteogenesis imperfecta: clinical diagnosis, nomenclature and severity assessment. *American journal of medical genetics. Part A*, 164(6), 1470-1480.

Vanz, A. P., Van de Sande, L. J., Pinheiro, B., Zambrano, M., Brizola, E., Rocha, N. S., & Félix, M. T. (2018). Health-related quality of life of children and adolescents with osteogenesis imperfecta: a cross-sectional study using PedsQL™. *BMC Pediatrics*, 18(1), 95.

Vaughn, G. A., Mason, B., Moon, H. B., & Turley, P. K. (2005). The effects of maxillary protraction therapy with or without rapid palatal expansion: A prospective, randomized clinical trial. *American Journal of Orthodontics and Dentofacial Orthopedics*, 128(3), 299-309.

Verweij, J. P., Houppermans, P. N., Gooris, P., Mensink, G., & Van Merkesteyn J. R. (2016). Risk factors for common complications associated with bilateral sagittal split osteotomy: A literature review and meta-analysis. *Journal of Cranio-Maxillofacial Surgery*, 44(9), 1170-1180.

Waltimo-Sirén, J., Kolkka, M., Pynnönen, S., Kuurila, K., Kaitila, I., & Kovero, O. (2005). Craniofacial features in osteogenesis imperfecta: a cephalometric study. *American Journal of Medical Genetics Part A*, 133(2), 142-150.

Whitestone, B. W., & Chapnick, P. (1986). Correction of mandibular prognathism in osteogenesis imperfecta tarda. A case report. *Journal Canadian Dental Association*, 52(10), 853-856.