

A Systematic Review of Pulp Revascularization Using a Triple Antibiotic Paste

Aline Maria do Couto, BDS, MSc¹ • Marcela Carvalho Espaladori, BDS, MSc² • Anamaria Pessoa Pereira Leite, BDS, MSc, PhD³ • Carolina Castro Martins, BDS, MSc, PhD⁴ • Maria Cássia Ferreira de Aguiar, BDS, MSc, PhD⁵ • Lucas Guimarães Abreu, BDS, MSc, PhD⁶

Abstract: Purpose: The purpose of this systematic review was to summarize the clinical and radiographic results of pulp revascularization procedures employing a triple antibiotic paste in teeth with incomplete root formation. **Methods:** Electronic searches were conducted in February 2017 using PubMed, Medline, Web of Science, Scopus, The Cochrane Library, ProQuest, Lilacs and The Brazilian Library of Dentistry, UK National Institute for Health and Care Excellence, U.S. National Institutes of Health, Clinical Trials, and Google. The search was updated in March 2019. Clinical trials in English, Portuguese, and Spanish, without any restrictions regarding the year of publication, were included. The quality of the studies was analyzed using the Cochrane Collaboration tool. **Results:** The search retrieved 1,768 references, and eight studies were included for a qualitative analysis. In these eight studies, the risk of bias across the Cochrane tool's domains varied from low to unclear. The included studies demonstrated that the clinical and radiographic success of pulp revascularization using calcium hydroxide or triple antibiotic paste appears to resolve symptoms and periapical healing. **Conclusions:** Triple antibiotic paste is effective in the pulp revascularization therapy of teeth with incomplete root formation. Absence of symptoms and the achievement of periapical integrity have been observed. (*Pediatr Dent* 2019;41(5):341-53) Received November 12, 2018 | Last Revision July 19, 2019 | Accepted July 22, 2019

KEYWORDS: PULP REVASCULARIZATION, TRIPLE ANTIBIOTIC PASTE, TEETH WITH INCOMPLETE ROOT FORMATION, SYSTEMATIC REVIEW

The conventional treatment for teeth with incomplete root formation affected by pulp necrosis and periapical periodontitis is the long-term application of calcium hydroxide or the use of mineral trioxide aggregate (MTA), aiming to induce apexification.¹ The American Association of Endodontists (AAE)² has defined this therapy as “a method to induce a calcified barrier in a root with an open apex or the continued apical development of an incompletely formed root in teeth with necrotic pulp.” Despite the fact that this technique stimulates apical barrier formation, the teeth are more susceptible to root fractures due to the thin dentin walls.³

In recent years, regenerative endodontic procedures have emerged as a promising alternative to apexification, due in particular to advantages like root development and reinforcement—which prevents root fractures by increasing root length and thickening the dentin wall.⁴ The regenerative endodontic treatment of nonvital infected teeth may take place in two ways: (1) using tissue engineering technology, which is characterized by the active regeneration of the dentin-pulp complex

in order to implant or regenerate the pulp⁵; and (2) pulp revascularization, a procedure “in which a new tissue is expected to be formed from the tissue present in the teeth, allowing for the continuation of the development of the root.”⁵

After performing the disinfection protocol, the conventional technique used in pulp revascularization procedures consists of carrying out a mechanical irritation at the apex to initiate bleeding in the root canal, resulting in a blood clot at the level of the cemento-enamel junction.⁶ Undoubtedly, this technique of inducing bleeding is the most commonly reported in the literature.^{4,7-13} Other techniques consist of the use of platelet-rich plasma (PRP),^{8,12,13} PRP and collagen,⁴ and platelet-rich fibrin (PRF).^{4,11,13} Adopting these techniques, bleeding is induced to form an intracanal blood clot. Use of an injectable scaffold impregnated with basic fibroblast growth factor (bFGF)⁷, a sterile collagen sponge,¹¹ or poly (lactic-co-glycolic acid) (PLGA)¹¹ has also been described.

To enable revascularization, the infection must be eliminated and the microbial ecosystem removed effectively,¹⁴ which is a challenge for achieving long-term success in regenerative therapy.¹⁵ However, the choice of intracanal medication for these procedures remains controversial. Since 2018, the AAE has recommended the use of triple and double antibiotic pastes in low concentrations or calcium hydroxide.¹⁶ Triple and double antibiotic pastes in different compositions have been largely cited in the literature.^{4,7-13} Calcium hydroxide in different pulp revascularization procedures has also been reported,¹⁷⁻²⁰ including calcium hydroxide associated with two percent chlorhexidine gel.⁹

The antibacterial efficacy of triple antibiotic paste²¹ and calcium hydroxide²² has been demonstrated in the literature. Although these medications have their biocompatibility attested in animals,²³ triple antibiotic paste may hinder the survival of stem cells of the apical papilla (of a cell line of human provenance, cultured in vitro), whereas calcium hydroxide may promote the survival and proliferation of these cells.²⁴

Drs. ¹do Couto and ²Espaladori are PhD candidates, and ³Dr. de Aguiar is a full professor, Department of Oral Pathology and Surgery; and Drs. ⁴Martins and ⁵Abreu are professors, Department of Pediatric Dentistry and Orthodontics; all in the School of Dentistry, Universidade Federal de Minas Gerais, Belo Horizonte, Minas Gerais, Brazil. ⁶Dr. Leite is a professor, Department of Dentistry Clinic, School of Dentistry, Federal University of Juiz de Fora, Minas Gerais, Brazil.

Correspond with Dr. Couto at alinemariacouto@hotmail.com

HOW TO CITE:

do Couto AM, Espaladori MC, Leite APP, Martins CC, de Aguiar MCF, Abreu LG. A Systematic Review of Pulp Revascularization Using a Triple Antibiotic Paste. *Pediatr Dent* 2019;41(5):341-53.

OPEN ACCESS DISCLAIMER on page 353

Considering the current importance of pulp revascularization for the treatment of teeth with incomplete root formation, in particular in pediatric patients, the purpose of this systematic review was to summarize the clinical and radiographic results of studies on pulp revascularization procedures employing triple antibiotic paste in teeth with incomplete root formation.

Methods

Protocol and registration. This systematic review was described according to the guidelines of the preferred reporting items for systematic review and meta-analysis checklist (PRISMA)²⁵ and registered in PROSPERO under the number CRD42018093629.

Eligibility criteria. This study aimed to include randomized clinical trials that compared triple antibiotic paste (in any

combination or concentration) with calcium hydroxide for revascularization as an intracanal medication for pulp revascularization in anterior or posterior teeth with incomplete root formation. Randomized studies evaluating only triple antibiotic paste were also considered for inclusion, provided they had other comparison groups (independent of medication).

The clinical question to be answered aimed to summarize the clinical and radiographic results of pulp revascularization procedures employing triple antibiotic paste in teeth with incomplete root formation (PICO question: P [population]—patients with teeth with incomplete root formation; I [intervention]—triple antibiotic paste; C [comparison]—calcium hydroxide for revascularization or no medication; O [outcome]—pulp revascularization).

No restrictions were imposed on the year of publication of the article. Studies in English, Portuguese, and Spanish were

Table 1. SEARCH STRATEGY FOR EACH DATABASE SEARCHED

Database	Search strategy	Results
Medline through PubMed®	immature permanent teeth OR immature teeth OR incomplete rhizogenesis AND calcium hydroxide (Mesh) OR calcium hydroxide paste OR calcium hydroxide intracanal medication OR triple antibiotic paste OR triple antibiotic paste intracanal medication AND pulp revascularization OR pulp regeneration OR regenerative endodontic procedures	324
Medline through Ovid	immature permanent teeth OR immature teeth OR incomplete rhizogenesis AND calcium hydroxide (Mesh) OR calcium hydroxide paste OR calcium hydroxide intracanal medication OR triple antibiotic paste OR triple antibiotic paste intracanal medication AND pulp revascularization OR pulp regeneration OR regenerative endodontic procedures	239
Web of Science	immature permanent teeth OR immature teeth OR incomplete rhizogenesis AND calcium hydroxide (Mesh) OR calcium hydroxide paste OR calcium hydroxide intracanal medication OR triple antibiotic paste OR triple antibiotic paste intracanal medication AND pulp revascularization OR pulp regeneration OR regenerative endodontic procedures	198
Scopus	immature permanent teeth OR immature teeth OR incomplete rhizogenesis AND calcium hydroxide (Mesh) OR calcium hydroxide paste OR calcium hydroxide intracanal medication OR triple antibiotic paste OR triple antibiotic paste intracanal medication AND pulp revascularization OR pulp regeneration OR regenerative endodontic procedures	752
The Cochrane Library	immature permanent teeth OR immature teeth OR incomplete rhizogenesis AND calcium hydroxide (Mesh) OR calcium hydroxide paste OR calcium hydroxide intracanal medication OR triple antibiotic paste OR triple antibiotic paste intracanal medication AND pulp revascularization OR pulp regeneration OR regenerative endodontic procedures	4
ProQuest	immature permanent teeth OR immature teeth OR incomplete rhizogenesis AND calcium hydroxide (Mesh) OR calcium hydroxide paste OR calcium hydroxide intracanal medication OR triple antibiotic paste OR triple antibiotic paste intracanal medication AND pulp revascularization OR pulp regeneration OR regenerative endodontic procedures	129
Lilacs and BBO - Bireme	calcium hydroxide (Mesh) OR triple antibiotic AND pulp revascularization OR pulp regeneration OR regenerative	72
UK National Institute for Health and Care Excellence (NICE)	immature permanent teeth OR immature teeth OR incomplete rhizogenesis AND calcium hydroxide (Mesh) OR calcium hydroxide paste OR calcium hydroxide intracanal medication OR triple antibiotic paste OR triple antibiotic paste intracanal medication AND pulp revascularization OR pulp regeneration OR regenerative endodontic procedures	2
U.S. National Institutes of Health	calcium hydroxide (Mesh) OR triple antibiotic paste AND pulp revascularization OR pulp regeneration OR regenerative endodontic procedures	47
Clinical Trials	calcium hydroxide (Mesh) OR triple antibiotic paste AND pulp revascularization OR pulp regeneration OR regenerative endodontic procedures	1
Google	immature permanent teeth OR immature teeth OR incomplete rhizogenesis AND calcium hydroxide (Mesh) OR calcium hydroxide paste OR calcium hydroxide intracanal medication OR triple antibiotic paste OR triple antibiotic paste intracanal medication AND pulp revascularization OR pulp regeneration OR regenerative endodontic procedures	0

included; retrospective studies, case reports or series, laboratory or in vitro studies, animal studies, studies in progress (unfinished), reviews, abstracts of scientific meetings, editorials, letters, and book chapters were excluded. Studies that did not evaluate the clinical and/or radiographic outcomes of pulp revascularization, that included teeth with developmental anomalies (e.g., dens invaginatus), or that evaluated transplanted teeth as well as avulsed and reimplanted teeth were excluded.

Sources of data and search strategy. There was no date restriction on the searches performed. Electronic searches were conducted from the databases' date of inception until February 2017 in Medline through PubMed, Medline through Ovid, Web of Science, Scopus, The Cochrane Library, and ProQuest. In addition, searches in Lilacs, the Brazilian Library of Dentistry (BBO), Virtual Health Library (Bireme, Latin America), UK National Institute for Health and Care Excellence (NICE),

and U.S. National Institutes of Health Clinical Trials were also conducted. Finally, a search in the gray literature through Google was performed. The search was updated in March 2019 in the databases Medline through PubMed, Medline through Ovid, and Web of Science. The keywords and their combinations used in the search strategies were specific to each database (Table 1). The management of retrieved references and the removal of duplicates were performed by means of the EndNote Web software.

Selection of studies. The selection process of the studies was carried out in two phases. In phase one, two independent reviewers selected articles after the evaluation of titles/abstracts. In the event of a disagreement between reviewers, a third reviewer was consulted. References whose titles/abstracts met the eligibility criteria were included. References whose titles/abstracts did not meet the inclusion criteria were

Table 2. ARTICLES EXCLUDED AFTER READING THE FULL TEXT AND REASONS FOR EXCLUSION

Reference	Reason for exclusion
Botero TM, Tang X, Gardner R, Hu JCC, Boynton JR, Holland GR. Clinical evidence for regenerative endodontic procedures: immediate versus delayed induction? <i>J Endod</i> 2017;43(9S):S75-S81.	Study in progress (not completed)
Cai WF, Li S, Xie L, Yao LL, Wang CH, Ren ZH. Influence of age on the effectiveness of revascularization in immature permanent teeth. <i>Shanghai Kou Qiang Yi Xue</i> 2017;26(5):545-8.	Chinese language
Chan EK, Desmeules M, Cielecki M, Dabbagh B, Ferraz Dos Santos B. Longitudinal cohort study of regenerative endodontic treatment for immature necrotic permanent teeth. <i>J Endod</i> 2017;43(3):395-400.	There is no comparison group
Chen MY, Chen KL, Chen CA, Tayebaty F, Rosenberg PA, Lin LM. Responses of immature permanent teeth with infected necrotic pulp tissue and apical periodontitis/abscess to revascularization procedures. <i>Int Endod J</i> 2012;45(3):294-305.	Case series study
Huang Y, Chen K, Zhang Y, Xiong H, Liu C. Effect of revascularization treatment of immature permanent teeth with endodontic infection. <i>J South Med Univ</i> 2013;33(5):776-8.	Chinese language
Kahler B, Mistry S, Moule A, et al. Revascularization outcomes: a prospective analysis of 16 consecutive cases. <i>J Endod</i> 2014;40(3):333-8.	Study with dens evaginatus (dental developmental anomaly)
Li L, Pan Y, Mei L, Li J. Clinical and radiographic outcomes in immature permanent necrotic evaginated teeth treated with regenerative endodontic procedures. <i>J Endod</i> 2017;43(2):246-51.	Study with dens evaginatus (dental developmental anomaly)
Liu X, Yao YF, Xu XY. Application of Nd:YAP laser in dental pulp revascularization. <i>Shanghai Kou Qiang Yi Xue</i> 2017;26(6):628-32.	Chinese language
Lovelace TW, Henry MA, Hargreaves KM, Diogenes A. Evaluation of the delivery of mesenchymal stem cells into the root canal space of necrotic immature teeth after clinical regenerative endodontic procedure. <i>J Endod</i> 2011;37(2):133-8.	Clinical and/or radiographic outcomes were not assessed in the study
Nagata JY, Soares AJ, Souza-Filho FJ, Zaia AA, Ferraz CC, Almeida JF, et al. Microbial evaluation of traumatized teeth treated with triple antibiotic paste or calcium hydroxide with 2 percent chlorhexidine gel in pulp revascularization. <i>J Endod</i> 2014;40(6):778-83.	Clinical and/or radiographic outcomes were not assessed in the study
Nageh M, Ahmed GM, El-Baz AA. Assessment of regaining pulp sensibility in mature necrotic teeth using a modified revascularization technique with platelet-rich fibrin: a clinical study. <i>J Endod</i> 2018;44(10):1526-33.	Study evaluating teeth with a closed apex after the use of double antibiotic paste
Neelamurthy PS, Kumar RA, Balakrishnan V, Venkatesan SM, Narayan GS, I K. Revascularization in immature and mature teeth with necrotic pulp: a clinical study. <i>J Contemp Dent Pract</i> 2018;19(11):1393-9.	There is no comparison group
Pinky C, Shashibhushan KK, Subbareddy VV. Endodontic treatment of necrosed primary teeth using two different combinations of antibacterial drugs: An in vivo study. <i>J Indian Soc Pedod Prev Dent</i> 2011;29(2):121-7.	The pulp revascularization procedure was not performed
Saoud TM, Zaazou A, Nabil A, Moussa S, Lin LM, Gibbs JL. Clinical and radiographic outcomes of traumatized immature permanent necrotic teeth after revascularization/revitalization therapy. <i>J Endod</i> 2014;40(12):1946-52.	There is no comparison group
Silujjai J, Linsuwanont P. Treatment outcomes of apexification or revascularization in nonvital immature permanent teeth: a retrospective study. <i>J Endod</i> 2017;43(2):238-45.	Retrospective study with dens evaginatus (dental developmental anomaly)

excluded. If the abstract did not contain a sufficient amount of information for an inclusion or exclusion decision, the full text of the reference was retrieved for assessment in phase two.

Phase two involved the assessment of full texts of the references by the same reviewers to determine their inclusion or exclusion. Those meeting the eligibility criteria were included. In the event of a disagreement between reviewers, a third reviewer was consulted.

Data extraction. Data extraction from selected articles was performed by two independent reviewers, who each used a customized table. The reviewers filled the table with the extracted data and then checked the information. Again, in the event of disagreements between reviewers at this stage, a third reviewer was consulted until a consensus was reached. Then, the extracted data were compiled in a single table.

The following data were extracted: authors; year of publication; country where the study was performed; number of teeth included and final sample size; age of participants (years); intracanal medication used; pulp revascularization procedure used; period of follow-up (months); statistical analysis; and main clinical and radiographic results, attesting whether pulp revascularization was successful or otherwise.

Criteria for pulp revascularization success. According to the AAE, the success of regenerative endodontic procedures, such as pulp revascularization, is achieved when the following goals are attained: "primary goal: the elimination of symptoms and the evidence of bone healing; secondary goal: increased root wall thickness and/or increased root length (desirable, but perhaps not essential); and tertiary goal: positive response to vitality tests (which, if achieved, could indicate a more organized vital pulp tissue)."¹⁶

Risk of bias within studies. The risk of bias assessment of the included studies was carried out using the Cochrane Collaboration tool.²⁶ This tool was used to assess the risk of bias in randomized clinical trials and is structured into seven domains: (1) random sequence generation; (2) allocation concealment; (3) blinding of participants and personnel; (4) blinding of outcome assessor; (5) incomplete outcome data; (6) selective reporting; and (7) other sources of bias.²⁶ For each domain, the evaluated study was awarded with one of the following outcomes: a low risk of bias; a high risk of bias; and unclear risk of bias.²⁶ Two reviewers performed the risk of bias assessment using the Cochrane tool. In the event of a disagreement between reviewers, a third reviewer was consulted.

Synthesis of results. A meta-analysis was conducted if data of the included articles were methodologically homogeneous and appropriate for pooling.

Results

Study selection. The searches across the databases retrieved 1,768 references. After the removal of 275 duplicates, 1,493 titles/abstracts were screened and 1,470 were excluded because they did not conform to PICO. Of the 23 articles selected for full text review, 15 were excluded because they did not meet the eligibility criteria and eight articles were included^{4,7-13} in this systematic review. The 15 articles excluded after full text

assessment and the reasons for exclusion are shown in Table 2. The Figure shows the flow diagram of the systematic review.

Of the selected articles, one study was a randomized clinical trial comparing triple antibiotic paste and calcium hydroxide.⁹ The other studies compared triple antibiotic paste revascularization to other types of nonvital treatment for immature teeth^{4,7,8,11-13} or to the age of the patient and apical diameter.¹⁰

Characteristics of the studies. The included studies were conducted in India,^{4,11,13} Egypt,^{7,10} Saudi Arabia,¹² Turkey,⁸ and Brazil.⁹ The language of the publication of all studies was English. All included articles were published between 2014 and 2017. The largest age group of the participants included individuals between seven and 13 years old.^{7,8,12} Some included studies had older age groups, although all teeth were immature when treated.^{4,9-11,13}

The included studies used triple antibiotic paste as intracanal medication.^{4,7-13} The composition of the paste varied from metronidazole, ciprofloxacin, and minocycline^{9,12,13} to metronidazole, ciprofloxacin, and doxycycline^{7,10} and metronidazole, ciprofloxacin, and cefaclor.⁸ Two studies did not specify the composition of triple antibiotic paste.^{4,11} One study compared triple antibiotic paste with calcium hydroxide for pulp revascularization in two distinct groups.⁹

All studies used the conventional revascularization endodontic protocol in which apical bleeding was induced to form an intracanal blood clot.^{4,7-13} Besides this apical bleeding technique, some studies included in the evaluation other techniques, such as the use of PRP,^{8,12,13} PRP and collagen,⁴ and PRF.^{4,11,13} The conventional technique of the induction of bleeding to form an intracanal blood clot, combined with an injectable

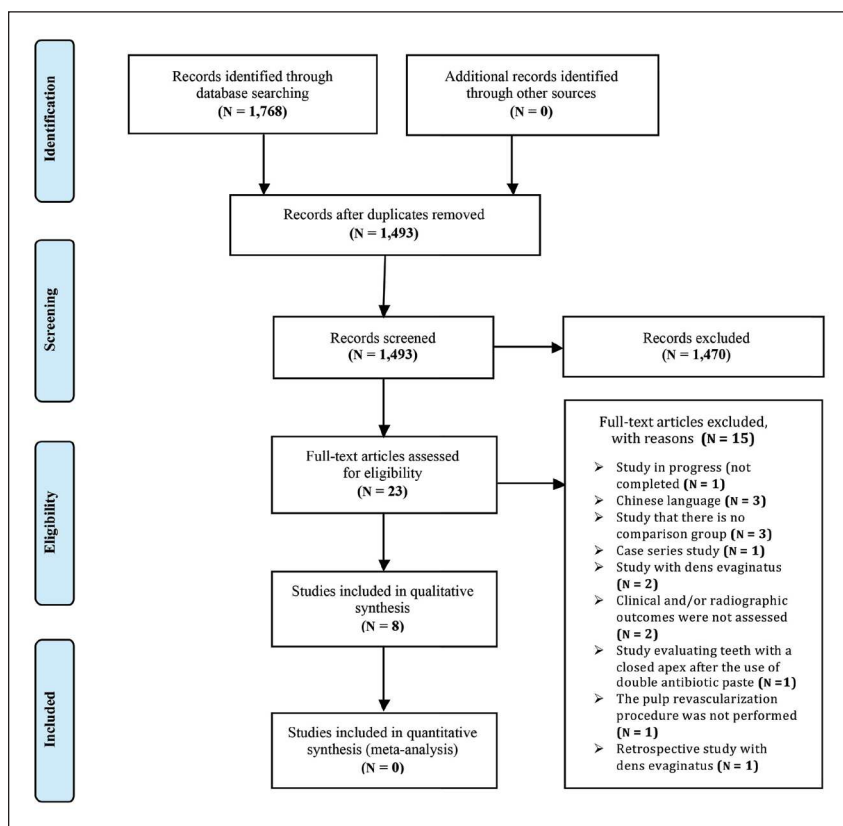


Figure. Flow diagram of the systematic review.⁵¹

scaffold impregnated with bFGF,⁷ a sterile collagen sponge,¹¹ or PLGA,¹¹ were other techniques used in the studies.

Study results: evaluation of clinical outcome. There was unanimity of the clinically satisfactory results in pulp revascularization procedures employing triple antibiotic paste as an intracanal medication. In most studies, all teeth were clinically asymptomatic in the different follow-up periods: after 1 month¹²; after 12 months¹³; and after 18 months.⁸ Some studies have shown that the patients were asymptomatic, had no sensitivity to percussion and palpation, and had a complete resolution of swelling and the sinus.^{4,11}

In the study, in which two distinct intracanal medications (triple antibiotic paste and calcium hydroxide associated with two percent chlorhexidine gel) were compared, highly satisfactory clinical results were also observed for both medications. There was a reduction in spontaneous pain, pain to percussion and palpation, sinus tract, and swelling after revascularization therapy. The reduction was significant for spontaneous pain ($P=0.01$), pain on horizontal percussion ($P=0.007$), and pain on palpation ($P=0.03$) in the group in which triple antibiotic paste was used. In the group in which calcium hydroxide associated with two percent chlorhexidine gel was used, the reduction was significant for pain on vertical percussion ($P=0.03$).⁹

The observed success rate was high in one study (94.3 percent), and there were signs and symptoms of failure in only two of the 35 cases.¹⁰ Another study showed a 90 percent success rate for conventional technique of the regenerative endodontic protocol and an 80 percent success rate for conventional technique and an injectable hydrogel scaffold impregnated with bFGF.⁷ Although the authors reported that the patients were clinically asymptomatic, a failure result was observed in two patients belonging to a group in which the PRF was used to perform the regenerative endodontic procedure.¹³

Concerning a response to the pulp vitality tests performed after different pulp revascularization procedures, in three studies, positive responses were reported. In the first, a late positive response to the pulp sensitivity test was reported in 19 cases (13 in the PRP group and six in the induced bleeding group).¹² In the second, seven teeth responded positively to the vitality test.⁸ In the third, there was a gradual change in the percentage of responses from negative to positive during the 12-month follow-up period, varying according to the pulp revascularization technique used (15 percent of the patients in the PRF group, 13.3 percent of the patients in the group with induced bleeding in the canal, and 15.8 percent of the patients in the PRP group).¹³ One study reported that no evaluated teeth regained pulpal sensitivity.⁹

Regarding crown discoloration due to the use of triple antibiotic paste, two studies reported divergent situations. In the first, no discoloration was observed regarding triple antibiotic paste containing cefaclor. However, the presence of crown discoloration caused by MTA was common, with the results considered nonesthetic in 12 of the 20 cases (60 percent).⁸ In the second, discoloration was observed in 83.3 percent of the cases (10 teeth) of the group in which triple antibiotic paste was used (ciprofloxacin, metronidazole, and minocycline). This result was also observed in 27.3 percent of the cases (three teeth) in the group in which the intracanal medication used was calcium hydroxide associated with two percent chlorhexidine gel.⁹

Study results: evaluation of the radiographic outcome. The radiographic evaluations showed satisfactory results independent

of the pulp revascularization technique used. Periapical healing was found in the majority of cases^{4,7,8,10,13} or in all the cases.¹¹ Similar results were also found in the study using two different intracanal medications (triple antibiotic paste and calcium hydroxide with two percent chlorhexidine gel). In this study, in the group in which triple antibiotic paste was used, all teeth presented with significant periapical repair ($P=0.03$). Similarly, in the group in which calcium hydroxide associated with two percent chlorhexidine gel was used, the same findings were observed, except in one tooth evaluated ($P=0.21$).⁹ The aforementioned findings agree with the study in which cone beam computed tomography was employed. This study showed a reduction in lesion size and an increase in bone density, evidencing periapical healing in all 30 cases evaluated.¹² Concerning the time required for complete periapical healing, Bezgin et al.⁸ observed that, although size one lesions (lesion in the apical region only) required a mean time of 4.2 months for complete healing, size two lesions (involving one-third to one half of the root) and size three lesions (involving more than one half of the root) required a mean time of 8.3 months. The differences between groups in the healing time, according to lesion size, were not statistically significant ($P>0.05$).

Regarding the apical closure parameter, studies that used different techniques of pulp revascularization demonstrated a reduction in the apical diameter⁷ or apical closure in most cases.¹² This reduction varied according to the technique used, with the best results reached in cases in which induction of bleeding to form an intracanal blood clot was carried out.⁴ Other authors¹¹ showed that, in the groups in which the PRF or bleeding induction were used to form an intracanal blood clot together with the use of a sterile collagen sponge, 50 percent of the cases had excellent apical closure results. Concerning the time required for apical closure, Bezgin et al.⁸ observed that, in the group in which the PRP was used, the mean time to complete the apical closure was 8.1 months; in the group in which bleeding induction was used to form an intracanal blood clot, the mean time was 9.0 months. However, the time required for complete apical closure was significantly higher in patients with acute preoperative symptoms, such as pain at night, spontaneous pain, and extreme sensitivity to percussion (10.2 months) versus patients without signs and symptoms (six months; $P<0.05$). Regarding a patient's age, one study found that the youngest age group (nine to 13 years) with an apical diameter equal to or greater than one mm presented with the greatest reduction in the apical diameter.¹⁰

The increase in root length was a parameter evaluated by all studies, highlighting the results of the study of Narang et al.,⁴ who observed excellent results in relation to root lengthening in 99 percent of the cases in which PRF was used, with a statistically significant difference observed in relation to the other groups evaluated. When the intracanal medication was considered, one study⁹ reported an increase in root length in 41.7 percent of the cases in which triple antibiotic paste was used and in 27.3 percent of the cases in which calcium hydroxide associated with two percent chlorhexidine gel was used. Regarding the different revascularization techniques adopted, Bezgin et al.⁸ observed that, in the teeth of the group in which bleeding was induced to form an intracanal blood clot, the mean root area had an increase of 12.6 percent; in the group in which PRP was used, this increase was 9.86 percent. However, the difference between groups was not statistically significant ($P>0.05$). Concerning age, the younger age group (nine to 13 years) with an apical diameter between 0.5 mm

and one mm (1.09 ± 0.5 mm) or equal to or greater than one mm (1.26 ± 1.08 mm) showed a significantly higher increase in the root length compared to the older age group (14 to 18 years) with an apical diameter between 0.5 mm and one mm (0.43 ± 0.19 mm) or equal to or greater than one mm (0.45 ± 0.30 mm).¹⁰

Another parameter evaluated by the majority of studies was the increase in root thickness. In this regard, Nagy et al.⁷ observed a progressive increase in root thickness in the groups in which regenerative endodontic protocols were performed. Corroborating with these results, Narang et al.⁴ observed excellent results of the thickening of the dentinal wall in 60 percent of the cases in the PRF group ($P=0.047$), good results in 50 percent of the cases in the group in which bleeding induction was carried out, and good results in 20 percent of the cases in the group in which PRP was used. However, a statistically significant difference between these groups was not observed. Regarding the patients' age group and the increase in the root thickness parameter, there was no significant

difference between subgroups with an apical diameter between 0.5 mm and one mm (increase of 0.50 ± 0.24 mm) and an apical diameter equal to or greater than one mm in the younger age group (nine to 13 years; increase of 0.61 ± 0.38 mm). In the group with an older age (14 to 18 years) and an apical diameter between 0.5 mm and one mm, the increase in root thickness was lower than the other groups (0.14 ± 0.11 mm).¹⁰ The characteristics of the studies and their results are described in Table 3.

Risk of bias in included studies. The risk of bias assessment of the studies, based on the Cochrane tool, is shown in Table 4. The study by Shivashankar et al.¹³ presented low risk of bias in all domains of the Cochrane tool. In the other seven included studies,^{4,7-12} this risk of bias across the domains ranged from low to unclear risk of bias.

Synthesis of results. A meta-analysis was unfeasible. The included articles were heterogeneous in terms of their methodology, and the comparisons between interventions could not be performed.

Table 3. DATA EXTRACTION FROM INCLUDED STUDIES*

Authors, year and country	No. of teeth (final sample size)	Age (years)	Intracanal medication	Pulp revascularization procedure	Period of follow-up (months)	Statistical analysis
Alagl et al., 2017, ¹² Saudi Arabia	32(30)	8-11	Triple antibiotic paste (metronidazole, ciprofloxacin and minocycline)	Control group: induction of bleeding to form an intracanal blood clot Test group: PRP	Every 3 months for 12 months	Paired <i>t</i> test and Mann-Whitney U test
Bezgin et al., 2015 ⁸ Turkey	22 (20)	7-13	Triple antibiotic paste (metronidazole, ciprofloxacin and cefaclor)	PRP group (n=11) Group BC: induction of bleeding to form an intracanal blood clot (n=11)	3, 6, 9, 12, 15, and 18	Fisher's exact test and Mann-Whitney U test
Estefan et al., 2016 ¹⁰ Egypt	40 (35)	9-18	Triple antibiotic paste (metronidazole, ciprofloxacin and doxycycline)	Induction of bleeding to form an intracanal blood clot Group Y: 9-13 years (n=20) Group O: 14-18 years (n=20) Each group was subdivided according to the apical diameter into 2 equal subgroups: Subgroup (n): apical diameter between 05 mm and 1 mm (n=10) Subgroup (w): apical diameter ≥ 1 mm (n=10)	3, 6, 9, and 12	Two-way ANOVA and Tukey's post hoc test
Nagata et al., 2014 ⁹ Brazil	23 (23)	7-17	TAP group: triple antibiotic paste (metronidazole, ciprofloxacin, and minocycline) (n=12) CHP group: calcium hydroxide and 2 percent chlorhexidine gel (n=11)	Induction of bleeding to form an intracanal blood clot	Patients in both groups were scheduled for 1, 3, 6, 9, 12, 15, and 19 months The follow-up period ranged from 9 to 19 months (mean period of 15 months)	McNemar's test and Fisher's exact test

* Abbreviations used in this Table: PRP=platelet-rich plasma; BC=induction of bleeding to form an intracanal blood clot; bFGF=basic fibroblast growth factor; PRFM=platelet-rich fibrin matrix; PRF=platelet-rich fibrin; PLGA=poly(lactic-co-glycolic acid); ANOVA=analysis of variance; PAI=periapical index.

Table 3. CONTINUED

Authors, year and country	Main clinical results	Main radiographic results
Alagl et al., 2017, ¹² Saudi Arabia	All 15 patients (30 teeth: PRP=15, blood clot=15) presented exceptional clinical and radiographic responses. After 1 month, all teeth were clinically asymptomatic with the comprehensive resolution of lesions associated with soft tissues. After 5 months, pulp sensitivity tests (cold and electric) provoked a late positive response close to that found in adjacent teeth at 23 regions. This response was observed in 19 cases (PRP=13, blood clot=6). At 12 months, resolution of signs and symptoms (pain, swelling, fistula, and/or sensitivity to percussion and palpation) was observed in all 30 teeth.	At 12 months, there was a resolution or decrease in the lesion size and an increase in bone density, showing periapical healing in all 30 teeth. Continuous root development or apical closure was observed in 22 teeth (PRP=14, blood clot=8). Statistically significant differences ($P<0.001$) were observed in the pre- and posttreatment comparison of the parameters evaluated (lesion size, bone density, and root length) in both groups (control and test). In the comparison of each parameter (lesion size, bone density, and root length) between the control group and the test group, only the mean difference in root length was statistically significant ($P<0.004$).
Bezgin et al., 2015 ⁸ Turkey	All 20 teeth were clinically asymptomatic during the 18-month follow-up period. No discoloration was observed in relation to triple antibiotic paste used, containing cefaclor; however, the presence of crown discoloration caused by MTA use was common, with the results considered non-esthetic in 12 of the 20 cases (60 percent). Seven teeth responded positively to the vitality test (PRP=5; BC=2), with no statistically significant difference between the groups ($P>0.05$).	One tooth from the BC group presented an increase of a preexisting periapical pathology and was considered radiographically unsuccessful, while the remaining 14 periapical lesions showed considerable scarring. Although lesions of size 1 require an average time of 4.2 months for complete healing, compared with 8.3 months for size 2 and 3 lesions, the differences in healing time according to lesion size were not statistically significant ($P>0.05$). Differences in healing time between the PRP and BC groups were not statistically significant, although complete healing occurred earlier in the PRP group (mean=6.4 months) than in the BC group (mean=6.8 months). Apical closure: Differences in the time required for complete apical closure were similar between both groups. In the PRP group, the mean time for complete apical closure was 8.1 months; in the BC group, it was 9 months. However, it was observed that the time required for complete apical closure was significantly higher in patients with acute preoperative symptoms, such as night pain, spontaneous pain, and extreme sensitivity to percussion (10.2 months) versus patients without signs and symptoms (6 months; $P<0.05$). Increase in root area: The teeth of the BC group showed an average increase of 12.6 percent compared to 9.86 percent in the PRP group; however, the difference between the groups was not statistically significant ($P>0.05$). Partial obliteration of the canal was observed in 8 cases (PRP=4, BC=4); however, no relationship was found between the obliteration and any of the variables (presence/size of the lesion, necrosis etiology, preoperative symptoms, and treatment group; $P>0.05$).
Estefan et al., 2016 ¹⁰ Egypt	Did not specify details. Only the clinical and radiographic examination during the follow-up period showed signs and symptoms of failure in 2 of the 35 cases, with a global success rate of 94.3 percent. One case belonged to group Y (w), and the other case belonged to group O (n).	Most of the cases demonstrated radiographic evidence of periapical healing. Increase in root length: There was no significant difference between the subgroups (n) and (w) in both age groups Y and O throughout the follow-up period. Younger age groups Y (n) and Y (w) showed a significantly greater increase (1.09 ± 0.5 and 1.26 ± 1.08 mm, respectively) in root length than in the older age groups O (n) and O (w) (0.43 ± 0.19 and 0.45 ± 0.3 mm, respectively). Increase in root thickness: There was no significant difference between the subgroups (n) and (w) in the age group Y (increase of 0.5 ± 0.24 and 0.61 ± 0.38 mm, respectively). In the O (n) group, a significantly lower increase in root thickness was observed (0.14 ± 0.11 mm). Decrease in apical diameter: group Y (w) showed the largest decrease in the apical diameter in the follow-up period, followed by group Y (n) and O (w). The O (n) group showed the smallest significant change in the apical diameter.
Nagata et al., 2014 ⁹ Brazil	In both groups, there was a reduction in spontaneous pain, pain to percussion and palpation as well as swelling after revascularization therapy. Remission of the sinus tract was also observed. The TAP group showed a significant reduction in spontaneous pain ($P=0.01$), pain on horizontal percussion ($P=0.007$), and pain on palpation ($P=0.03$). The CHP group presented a significant reduction in pain on vertical percussion ($P=0.03$). In both groups, no teeth recovered pulp sensitivity. Crown discoloration was observed in 10 teeth (83.3 percent) within the TAP group and in 3 teeth within the CHP group (27.3 percent; $P=0.002$).	All teeth in the TAP group presented significant periapical repair ($P=0.03$). The same findings were found for all teeth of the CHP group, except for 1 tooth ($P=0.21$). Apical closure was significantly observed in both groups ($P<0.05$). An increased root length was observed in 5 teeth (41.7 percent) in the TAP group and 3 teeth (27.3 percent) in the CHP group. Thickening of the lateral dentinal walls was observed in 5 teeth of each group.

Discussion

Pulp revascularization therapy with triple antibiotic paste was successful in all the studies, due to a reduction⁹ or absence of symptomatology,^{4,8,11-13} the presence of periapical healing or repair,^{4,7-13} the presence of apical closure^{4,8,9,11,12} or the reduction in apical diameter,^{7,10} the increase in root length,^{4,7-13} the increase in root thickness,^{4,7,10} or dentinal wall thickening.^{9,11,13}

Triple antibiotic paste as an intracanal medication was used in all studies. This was probably due to the large number of reports and series of cases published in the literature in which this medication has been used successfully in pulp revascularization procedures.^{6,27-30} The composition of triple antibiotic paste ranged from studies in metronidazole, ciprofloxacin, and minocycline,^{9,12,13} metronidazole, ciprofloxacin, and doxycycline,^{7,10} and metronidazole, ciprofloxacin, and cefaclor.⁸ The bactericidal efficacy of this paste in the composition of metronidazole, ciprofloxacin, and minocycline was confirmed by Hoshino et al.²¹ However, its use in a pulp revascularization procedure was first described by Banchs and Trope,⁶ who reported successful clinical and radiographic results, such as an apical closure and thickening of the dentinal walls. This pioneering study paved the way for further studies, particularly randomized clinical trials aiming to increase the scientific evidence about pulp revascularization, as well as the use of triple antibiotic paste in this procedure.

Although antibiotics used in regenerative endodontic procedures are effective against bacteria related to endodontic infections,³¹ the main disadvantage of triple antibiotic paste from a clinical point of view is the possibility of tooth discoloration. Nagata et al.⁹ observed tooth discoloration in most cases

(83.3 percent) treated with the paste. The authors indicated that the presence of minocycline could be associated with the discoloration. By contrast, in the study by Bezgin et al.,⁸ no tooth discoloration was observed in relation to triple antibiotic paste containing cefaclor. However, the authors reported the presence of discoloration caused by MTA placement, with 60 percent of the cases being considered unaesthetic (12 out of 20). Akcay et al.³² observed, through an experimental study using bovine incisors, that the highest level of discoloration occurred in teeth filled with triple antibiotic paste with minocycline. Interestingly, in their study, triple antibiotic paste with doxycycline, amoxicillin, or cefaclor resulted in clinically visible tooth discoloration. For double antibiotic paste and calcium hydroxide, visible discoloration was not observed; discoloration may be an adverse effect of regenerative endodontic procedures.³³ The AAE¹⁶ has recommended that, if triple antibiotic paste is used, it should be left below the cemento-enamel junction to avoid any discoloration. The use of alternatives, such as double antibiotic paste, calcium hydroxide and white mineral trioxide aggregate, or Biodentine has also been suggested to minimize the risk.³⁴

Another possible disadvantage of this medication is its detrimental effect on stem cell survival. In this sense, Ruparel et al.³⁵ observed, *in vitro*, that triple antibiotic paste (metronidazole, ciprofloxacin, and minocycline), double antibiotic paste (metronidazole and ciprofloxacin), and modified triple antibiotic paste (metronidazole, ciprofloxacin, and cefaclor) in concentrations used in regenerative endodontic procedures had a detrimental effect on the survival of human apical papilla stem cells. Thus, it is known that the conditioning of the dentin

Table 3. CONTINUED*

Authors, year and country	No. of teeth (final sample size)	Age (years)	Intracanal medication	Pulp revascularization procedure	Period of follow-up (months)	Statistical analysis
Nagy et al., 2014 ⁷ Egypt	24 (20)	9-13	Triple antibiotic paste (metronidazole, ciprofloxacin and doxycycline)	REG group: conventional regenerative endodontic protocol (blood clot scaffold; n=12) FGF group: conventional regenerative endodontic protocol + injectable hydrogel scaffold impregnated with bFGF (n=12)	3, 6, 12, and 18	Two-way ANOVA and Tukey's post hoc test
Narang, Mittal, Mishra, 2015 ⁴ India	15 (15)	Under 20	Triple antibiotic paste (did not specify composition)	Group II: induction of bleeding to form an intracanal blood clot (n=5) Group III: PRF or PRFM (n=5) Group IV: PRP + collagen (n=5)	6 and 18	Fisher exact test
Sharma, Mittal, 2016 ¹¹ India	16 (16)	10-25	Triple antibiotic paste (did not specify composition)	Group I: induction of bleeding to form an intracanal blood clot (n=4) Group II: PRF (n=4) Group III: induction of bleeding to form an intracanal blood clot + sterile collagen sponge (n=4) Group IV: induction of bleeding to form an intracanal blood clot + PLGA (n=4)	6 and 12	One-way ANOVA test and Z-test for proportions

* Abbreviations used in this Table: PRP=platelet-rich plasma; BC=induction of bleeding to form an intracanal blood clot; bFGF=basic fibroblast growth factor; PRFM=platelet-rich fibrin matrix; PRF=platelet-rich fibrin; PLGA= poly(lactic-co-glycolic acid); ANOVA=analysis of variance; PAI=periapical index.

Table 3. CONTINUED

Authors, year and country	Main clinical results	Main radiographic results
Nagy et al., 2014 ⁷ Egypt	Did not specify details. Only the clinical and radiographic examination during the follow-up period showed the presence of signs and symptoms of failure in 3 cases (2 cases belonged to the FGF group and 1 to the REG group). The success rates for the REG, and FGF groups were 90 percent, and 80 percent, respectively.	After 18 months, most cases showed evidence of periapical healing. The REG and FGF groups showed a progressive increase in root length and thickness and a decrease in apical diameter. Increase in root length: There was no significant difference between the REG and FGF groups, throughout the follow-up period. Regarding the effect of time, a statistically significant difference was found after 18 months for the REG group. Increase in root thickness: There was no significant difference between the REG and FGF groups. In relation to time, a statistically significant difference was observed at 18 months for both groups. Decreased apical diameter: There was no significant difference between the REG and FGF groups at 3, 6, 12, and 18 months. Periapical bone density: There was a significant improvement in bone density after 12 months in all groups. No significant difference was found among all groups throughout the follow-up period.
Narang, Mittal, Mishra, 2015 ⁴ India	Clinically, all the groups evaluated presented excellent results. The patients were asymptomatic, with no sensitivity to percussion and palpation, with the complete resolution of swelling and intraoral sinus.	Periapical healing: Of the 5 cases in each group, 98 percent of the group III cases presented excellent periapical healing ($P=0.003$); 60 percent in group II and 80 percent in group IV presented good results, with no statistically significant difference between the two groups. However, revascularization supplemented with PRP presented better results than the group with a blood clot. Apical closure: There was no statistically significant difference between groups II-IV ($P=0.417$); 66.67 percent of the cases in group II, 40 percent in group III, and 60 percent in group IV showed good apical closure. Root lengthening: 99 percent of the cases in group III had excellent results in relation to root lengthening, with a statistically significant difference in relation to the other groups ($P=0.002$); 40 percent of the cases in groups II and IV presented good results but without a difference. Dentinal wall thickening: Excellent results were observed in 60 percent of the cases in group III ($P=0.047$), good results in 50 percent of cases in group II, and in 20 percent of cases in group IV, with no statistically significant differences observed.
Sharma, Mittal, 2016 ¹¹ India	All groups presented excellent results. Patients were completely asymptomatic throughout the study period, without palpation and percussion sensitivity and with complete resolution and no reappearance of swelling and intraoral sinus.	All cases showed an improvement in terms of periapical healing, apical closure, root lengthening, and dentinal wall thickening. Periapical healing: group II presented the best results, with 75 percent of cases showing excellent periapical healing, followed by group III, which showed excellent results in 25 percent of the cases, followed by group I. The smallest healing was observed in group IV, with 75 percent of cases showing only a reasonable amount of scarring. There was a statistically significant difference between the groups ($P=0.026$). The difference between groups II and IV ($P=0.028$) and between groups III and IV ($P=0.028$) was statistically significant. Thus, group II and group III were better than group IV. Apical closure: group II and group III presented the best results, both with 50 percent of the cases showing excellent results, followed by group I, with 75 percent of cases presenting good apical closure. Group IV was the least effective, with only 50 percent of cases showing good results. There was no statistically significant difference between these groups ($P=0.197$). Root lengthening: group I presented better results, with 75 percent of the cases showing good root lengthening, followed by group IV, with 50 percent of the cases showing good results. Group III presented only 25 percent of the cases with good results. Group II presented the least effective results, with all cases showing only a reasonable amount of root lengthening. There was no statistically significant difference between these groups ($P=0.168$). Dentinal wall thickening: group III presented the best results, with 25 percent of cases presenting excellent results, followed by group II, with 75 percent of the cases showing good thickening. In group I, 50 percent of the cases showing good results. Group IV was the least effective, with only 25 percent of the cases showing good thickening. There was no statistically significant difference between these groups ($P=0.383$).

Table 3. CONTINUED*

Authors, year and country	No. of teeth (final sample size)	Age (years)	Intracanal medication	Pulp revascularization procedure	Period of follow-up (months)	Statistical analysis
Shivashankar et al., 2017 ¹³ India	60 (54)	6-28	Triple antibiotic paste (metronidazole, ciprofloxacin and minocycline)	Group A: PRF (N=20) Group B: revascularization with conventional induced bleeding technique (N=20) Group C: PRP (N=20)	3, 6, 9, and 12	Chi-square test, ANOVA test, Bonferroni test and Kappa
Main clinical results			Main radiographic results			
The clinical evaluation showed no significant difference between the groups. Clinically, none of the patients were symptomatic; 18 patients (Group A), 15 patients (Group B), and 19 patients (Group C) presented a successful clinical outcome; 2 patients from Group A presented a result of failure (PAI score=4), although they were clinically asymptomatic. Response to a vitality test at 12 months was observed in the 3 groups, with a gradual change in the percentage of negative responses to positive responses observed during the follow-up period; 15 percent of patients in Group A, 13.30 percent in Group B, and 15.8 percent in Group C presented a positive response after 12 months.			The radiographic success criteria did not present a significant difference between the groups. A total of 15 patients (Group A), 12 patients (Group B) and 19 patients (Group C) showed complete healing. 3 patients in Group A and 3 patients in Group B showed incomplete healing (PAI score=3); 2 patients from Group A were grouped as the failure Group (PAI score=4). Success criteria were divided into strict and loose, and both did not show significant differences between Groups. The mean PAI scores of Group A, Group B, and Group C were 4.35, 4.4, and 4.26, respectively. Comparison of periapical healing at 6 and 12 months: Significant changes were observed in <i>P</i> -value (0.015) favoring group C at the end of one year. Root lengthening and lateral wall thickness at the end of 12 months: There was no significant difference between the three groups.			

* Abbreviations used in this Table: PRP=platelet-rich plasma; BC=induction of bleeding to form an intracanal blood clot; bFGF=basic fibroblast growth factor; PRFM=platelet-rich fibrin matrix; PRF=platelet-rich fibrin; PLGA= poly(lactic-co-glycolic acid); ANOVA=analysis of variance; PAI=periapical index.

with antibiotic triple paste at the usual clinical concentration of approximately 1,000 mg per mL is capable of altering the dentin, making it difficult for the stem cells of the apical papilla to survive.²⁴ Althumairy et al.²⁴ suggested that this medication may induce changes in dentin, altering its physical structure or inactivating growth factors. This paste remains in the dentin, despite vigorous cleaning with irrigators. However, the toxicity to stem cells is a concentration-dependent effect that can be avoided when the concentration of the paste is one mg per mL or less.²⁴

On the other hand, calcium hydroxide, an intracanal medication commonly used in apexification procedures,³⁶⁻³⁹ has a proven antibacterial efficacy in infected root canals.²² For this reason, this medication has been used successfully in many cases of pulp revascularization reported in the literature.^{9,17,18,20,40} Moreover, its use has been advised when there is sensitivity to one of the antibiotics used in triple antibiotic pastes.⁴¹ Although Banchs and Trope⁶ stated that their high pH can cause tissue necrosis, thus destroying tissues with the potential to differentiate into a new pulp, Ruparel et al.³⁵ observed, in vitro, that calcium hydroxide, at all concentrations tested, favored the survival and proliferation of human apical papilla stem cells. Another important issue to consider is the position in which this medication is placed inside the root canal. In this regard, Bose, Nummikowski, and Hargreaves⁴² observed that in regenerative endodontic procedures, when calcium hydroxide was radiographically restricted to the coronal half of the root canal, it produced better results (an increase in dentin wall thickness) than when placed beyond the coronal half. This fact is interesting, since the undifferentiated stem cells related to the

regeneration of the pulp tissues probably originate from local tissues adjacent to the apex of the root and not the systemic circulation.⁴³

Regarding the mechanism of action of these intracanal medications, it is known that the lethal effects of calcium hydroxide on bacterial cells are possibly achieved by the release of significant amounts of hydroxyl ions which make it possible to raise the pH in the local environment, causing the denaturation of the bacterial proteins, as well as damage to DNA and microbial cytoplasmic membranes.⁴⁴ With respect to triple antibiotic paste, the mechanism of action of metronidazole is through the inactivation of DNA, preventing bacterial protein synthesis.⁴⁵ Ciprofloxacin acts by "inhibiting the activity of DNA girase, an enzyme essential for bacterial survival."⁴⁵ Minocycline acts by "blocking the binding of the transporter RNA, preventing protein synthesis."⁴⁵ In fact, because of the complexity of infections involving root canal systems, the use of a single antibiotic may not result in effective disinfection, thus, justifying the use of a combination of antibiotics, capable of reducing the probability of developing resistant bacterial strains.⁴⁶

One study included in this systematic review compared a group of individuals submitted to pulp revascularization, performed by means of the induction of bleeding to form an intracanal blood using triple antibiotic paste and a group of individuals submitted to pulp revascularization protocol, performed by means of the induction of bleeding to form an intracanal blood using calcium hydroxide associated with two percent chlorhexidine gel.⁹ This combination of calcium hydroxide and chlorhexidine aimed to increase the antimicrobial efficacy of the composition.⁹ The clinical and radiographic

Table 4. QUALITY ASSESSMENT OF THE STUDY INCLUDED BASED ON THE COCHRANE COLLABORATION TOOL

Authors	Selection bias		Performance bias	Detection bias	Attrition bias	Reporting bias	Other bias
	Random sequence generation	Allocation concealment	Blinding of participants and personnel	Blinding of outcome assessment	Incomplete outcome data	Selective reporting	Other sources of bias
Alagl et al., 2017 ¹²	●	●	●	●	●	●	●
Bezgin et al., 2015 ⁸	●	●	●	●	●	●	●
Estefan et al., 2016 ¹⁰	●	●	●	●	●	●	●
Nagata et al., 2014 ⁹	●	●	●	●	●	●	●
Nagy et al., 2014 ⁷	●	●	●	●	●	●	●
Narang, Mittal, Mishra, 2015 ⁴	●	●	●	●	●	●	●
Sharma, Mittal, 2016 ¹¹	●	●	●	●	●	●	●
Shivashankar et al., 2017 ¹³	●	●	●	●	●	●	●

● Low risk of bias. ● Unclear risk of bias. ● High risk of bias; none of the studies had "High risk of bias" for any of the assessments.

results of both groups were similar. Corroborating these results, Bose et al.,⁴² through a retrospective study, observed that both calcium hydroxide and triple antibiotic paste, used as intracanal medications in immature necrotic teeth in regenerative endodontic procedures, may help promote the functional development of the dentin-pulp complex.

Regarding the antimicrobial efficacy of these two medications, there are conflicting results in the literature. On one hand, Ghabraei et al.⁴⁷ observed, in vitro, that triple antibiotic paste was able to eradicate the biofilm of *Enterococcus faecalis* in the root canal system in seven days, while the calcium hydroxide plus two percent chlorhexidine was able to do so in three days. On the other hand, Adl et al.⁴⁸ observed the opposite situation, in which triple antibiotic paste was most effective in disinfecting the canal against this bacterium compared to calcium hydroxide mixed with sterile saline.

Finally, in observing the successful clinical and radiographic results in included studies,^{4,7-13} it is necessary to consider, besides the medication used, the revascularization technique employed. In this sense, the conventional technique characterized by the induction of bleeding to form an intracanal blood clot was the most used technique. The creation of this blood clot in the canal after disinfection basically acts as a matrix for the growth of a new tissue within the pulp space, similar to necrotic pulp after a traumatic injury.⁶ However, one issue discussed in the literature is the origin of this new tissue formed in the pulp region and whether it is, in fact, pulp tissue. Banchs and Trope,⁶ pioneers in this technique, recognize that it is not known whether this tissue is actually pulp. Nevertheless, based on the fact that, in their case report, there was root growth and thickening in the root walls, they concluded that the tissue probably formed was, in fact, pulp with functional odontoblasts. Thus, in teeth with an open apex, when the root canal is disinfected and the inflammatory conditions are reversed, it may be that some vital pulp tissue and Hertwig's epithelial root sheath remain in the apical region and proliferate.⁶ According to Lovelace et al.,⁴³ the manipulation of the periapical tissues performed in this procedure of inducing bleeding to

form a blood clot seems to trigger the release of undifferentiated stem cells into the inner region of the root canals, where such cells can contribute to the regeneration of pulp tissues.

This systematic review has limitations that should be recognized. First, in seven studies evaluated with the Cochrane tool, the risk of bias across the domains ranged from low to unclear risk of bias. Second, only one randomized clinical trial compared triple antibiotic paste and calcium hydroxide.⁹ This fact and the methodological heterogeneity across included studies made it impossible to accomplish a meta-analysis. This paucity of information on pulp revascularization may be associated with publication bias, through which studies with no statistically significant results are less likely to be published than those with statistically significant results.⁴⁹ Lastly, only articles in English, Portuguese, and Spanish were included. However, the restriction on the language of publication may have been minimized by the no restriction regarding the publication date of the included articles and the searches across multiple databases.

The findings of this systematic review demonstrated a scarcity of studies that performed pulp revascularization procedures using triple antibiotic paste as an intracanal medication. Moreover, most included studies have shortcomings regarding the risk of bias. Therefore, future research with a more rigorous methodology on pulp revascularization should be conducted. Future studies should also compare triple antibiotic paste and calcium hydroxide, providing to the literature more homogeneous data for meta-analysis.⁵⁰

Conclusions

Based on the results of this systematic review, the following conclusions can be made:

1. Triple antibiotic paste is effective in the pulp revascularization therapy of teeth with incomplete root formation.
2. Treatment with this medication has demonstrated clinical and radiographic success with an absence of symptoms and the achievement of periapical integrity.

Acknowledgments

This work was supported by National Council for Scientific and Technological Development (CNPq), Brasília, Federal District, Brazil; Coordination for the Improvement of High Education Personnel (CAPES), Brasília, Federal District, Brazil and Research Foundation of Minas Gerais (FAPEMIG), Belo Horizonte, Minas Gerais, Brazil.

References

- Thibodeau B, Trope M. Pulp revascularization of a necrotic infected immature permanent tooth: case report and review of the literature. *Pediatr Dent* 2007;29(1):47-50.
- American Association of Endodontists. Glossary of Endodontic Terms. 9th ed. Chicago, Ill., USA: American Association of Endodontists; 2016:5.
- Rafter M. Apexification: a review. *Dent Traumatol* 2005;21(1):1-8.
- Narang I, Mittal N, Mishra N. A comparative evaluation of the blood clot, platelet-rich plasma, and platelet-rich fibrin in regeneration of necrotic immature permanent teeth: a clinical study. *Contemp Clin Dent* 2015;6(1):63-8.
- Bansal R, Bansal R. Regenerative endodontics: a state of the art. *Indian J Dent Res* 2011;22(1):122-31.
- Banchs F, Trope M. Revascularization of immature permanent teeth with apical periodontitis: new treatment protocol? *J Endod* 2004;30(4):196-200.
- Nagy MM, Tawfik HE, Hashem AAR, Abu-Seida AM. Regenerative potential of immature permanent teeth with necrotic pulps after different regenerative protocols. *J Endod* 2014;40(2):192-8.
- Bezgin T, Yilmaz AD, Celik BN, Kolsuz ME, Sonmez H. Efficacy of platelet-rich plasma as a scaffold in regenerative endodontic treatment. *J Endod* 2015;41(1):36-44.
- Nagata JY, Gomes BP, Rocha Lima TF, et al. Traumatized immature teeth treated with two protocols of pulp revascularization. *J Endod* 2014;40(5):606-12.
- Estefan BS, El Batouty KM, Nagy MM, Diogenes A. Influence of age and apical diameter on the success of endodontic regeneration procedures. *J Endod* 2016;42(11):1620-25.
- Sharma S, Mittal N. A comparative evaluation of natural and artificial scaffolds in regenerative endodontics: a clinical study. *Saudi Endod J* 2016;6(1):9-15.
- Alagl A, Bedi S, Hassan K, Al-Humaid J. Use of platelet-rich plasma for regeneration in non-vital immature permanent teeth: clinical and cone-beam computed tomography evaluation. *J Int Med Res* 2017;45(2):583-93.
- Shivashankar VY, Johns DA, Maroli RK, et al. Comparison of the effect of PRP, PRF, and induced bleeding in the revascularization of teeth with necrotic pulp and open apex: a triple blind randomized clinical trial. *J Clin Diagn Res* 2017;11(6):ZC34-ZC39.
- Nagata JY, Soares AJ, Souza-Filho FJ, et al. Microbial evaluation of traumatized teeth treated with triple antibiotic paste or calcium hydroxide with 2 percent chlorhexidine gel in pulp revascularization. *J Endod* 2014;40(6):778-83.
- Albuquerque MTP, Nagata J, Bottino MC. Antimicrobial efficacy of triple antibiotic-eluting polymer nanofibers against multispecies biofilm. *J Endod* 2017;43(9S):S51-S56.
- American Association of Endodontics. AAE Clinical Considerations for a Regenerative Procedure. Revised 4-1-2018. Available at: https://www.aae.org/specialty/wp-content/uploads/sites/2/2018/06/ConsiderationsForRegEndo_AsOfApril2018.pdf. Accessed February 1, 2019. (Archived by WebCite® at: <http://www.webcitation.org/75ruNgim2>)
- Cotti E, Mereu M, Lusso D. Regenerative treatment of an immature traumatized tooth with apical periodontitis: report of a case. *J Endod* 2008;34(5):611-6.
- Cehreli ZC, Isbitiren B, Sara S, Erbas G. Regenerative endodontic treatment (revascularization) of immature necrotic molars medicated with calcium hydroxide: a case series. *J Endod* 2011;37(9):1327-30.
- Chen MY, Chen KL, Chen CA, Tayebaty F, Rosenberg PA, Lin LM. Responses of immature permanent teeth with infected necrotic pulp tissue and apical periodontitis/abscess to revascularization procedures. *Int Endod J* 2012;45(3):294-305.
- Huang Y, Chen K, Zhang Y, Xiong H, Liu C. [Effect of revascularization treatment of immature permanent teeth with endodontic infection]. *J South Med Univ* 2013;33(5):776-8.
- Hoshino E, Kurihara-Ando N, Sato I, et al. In vitro antibacterial susceptibility of bacteria taken from infected root dentine to a mixture of ciprofloxacin, metronidazole and minocycline. *Int Endod J* 1996;29(2):125-30.
- Bystrom A, Claesson R, Sundqvist G. The antibacterial effect of camphorated paramonochlorophenol, camphorated phenol and calcium hydroxide in the treatment of infected root canals. *Endod Dent Traumatol* 1985;1(5):170-5.
- Gomes-Filho JE, Duarte PC, de Oliveira CB, et al. Tissue reaction to a triantibiotic paste used for endodontic tissue self-regeneration of nonvital immature permanent teeth. *J Endod* 2012;38(1):91-4.
- Althumairy RI, Teixeira FB, Diogenes A. Effect of dentin conditioning with intracanal medicaments on survival of stem cells of apical papilla. *J Endod* 2014;40(4):521-5.
- Shamseer L, Moher D, Clarke M, Gheri D, Liberati A, Petticrew M, Shekelle P, Stewart L, PRISMA-P group. Preferred reporting items for systematic review and meta-analysis protocols (PRISMA-P) 2015: elaboration and explanation. *BMJ* 2015;349:g7647.
- Cochrane Collaboration. Cochrane Handbook for Systematic Reviews of Interventions. V. 5.1.0 (updated March 2011). In: Higgins JPT, Green S, eds. London, UK: The Cochrane Collaboration; 2011. Available at: <http://handbook.cochrane.org>. Accessed August 31, 2019.
- Nosrat A, Seifi A, Asgary S. Regenerative endodontic treatment (revascularization) for necrotic immature permanent molars: a review and report of two cases with a new biomaterial. *J Endod* 2011;37(4):562-7.
- Bezgin T, Yilmaz AD, Celik BN, Sonmez H. Concentrated platelet-rich plasma used in root canal revascularization: two case reports. *Int Endod J* 2014;47(1):41-9.
- Raju SM, Yadav SS, Kumar MSR. Revascularization of immature mandibular premolar with pulpal necrosis: a case report. *J Clin Diagn Res* 2014;8(9):ZD29-ZD31.

30. Nagaveni NB, Poornima P, Joshi JS, Pathak S, Nandini DB. Revascularization of immature, nonvital permanent tooth using platelet-rich fibrin in children. *Pediatr Dent* 2015;37(1):1-6.
31. Montero-Miralles P, Martín-González J, Alonso-Ezpeleta O, Jiménez-Sánchez MC, Velasco-Ortega E, Segura-Egea JJ. Effectiveness and clinical implications of the use of topical antibiotics in regenerative endodontic procedures: a review. *Int Endod J* 2018;51(9):981-8.
32. Akcay M, Arslan H, Yasa B, Kavruk F, Yasa E. Spectrophotometric analysis of crown discoloration induced by various antibiotic pastes used in revascularization. *J Endod* 2014;40(6):845-8.
33. Kahler B, Rossi-Fedele G. A review of tooth discoloration after regenerative endodontic therapy. *J Endod* 2016;42(4):563-9.
34. Santos LGPD, Chisini LA, Springmann CG, et al. Alternative to avoid tooth discoloration after regenerative endodontic procedure: a systematic review. *Braz Dent J* 2018;29(5):409-18.
35. Ruparel NB, Teixeira FB, Ferraz CC, Diogenes A. Direct effect of intracanal medicaments on survival of stem cells of the apical papilla. *J Endod* 2012;38(10):1372-5.
36. El-Meligy OA, Avery DR. Comparison of apexification with mineral trioxide aggregate and calcium hydroxide. *Pediatr Dent* 2006;28(3):248-53.
37. Lee LW, Hsiao SH, Chang CC, Chen LK. Duration for apical barrier formation in necrotic immature permanent incisors treated with calcium hydroxide apexification using ultrasonic or hand filing. *J Formos Med Assoc* 2010;109(8):596-602.
38. Lee LW, Hsieh SC, Lin YH, Huang CF, Hsiao SH, Hung WC. Comparison of clinical outcomes for 40 necrotic immature permanent incisors treated with calcium hydroxide or mineral trioxide aggregate apexification/apexogenesis. *J Formos Med Assoc* 2015;114(2):139-46.
39. Bonte E, Beslot A, Boukpepsi T, Lasfargues JJ. MTA versus Ca(OH)₂ in apexification of non-vital immature permanent teeth: a randomized clinical trial comparison. *Clin Oral Invest* 2015;19(6):1381-8.
40. Iwaya S, Ikawa M, Kubota M. Revascularization of an immature permanent tooth with periradicular abscess after luxation. *Dent Traumatol* 2011;27(1):55-8.
41. Wigler R, Kaufman AY, Lin S, Steinbock N, Hazan-Molina H, Torneck CD. Revascularization: a treatment for permanent teeth with necrotic pulp and incomplete root development. *J Endod* 2013;39(3):319-26.
42. Bose R, Nummikoski P, Hargreaves K. A retrospective evaluation of radiographic outcomes in immature teeth with necrotic root canal systems treated with regenerative endodontic procedures. *J Endod* 2009;35(10):1343-9.
43. Lovelace TW, Henry MA, Hargreaves KM, Diogenes A. Evaluation of the delivery of mesenchymal stem cells into the root canal space of necrotic immature teeth after clinical regenerative endodontic procedure. *J Endod* 2011;37(2):133-8.
44. Mohammadi Z, Dummer PM. Properties and applications of calcium hydroxide in endodontics and dental traumatology. *Int Endod J* 2011;44(8):697-730.
45. National Agency of Health Surveillance. Antimicrobial Theoretical Basis and Clinical Use. Available at: "http://www.anvisa.gov.br/servicos/controle/rede_rm/cursos/rm_controle/opas_web/modulo1/conceitos.htm". Accessed February 1, 2019. (Archived by WebCite® at: "<http://www.webcitation.org/75rvnkoHc>")
46. Mohammadi Z, Abbott PV. On the local applications of antibiotics and antibiotic-based agents in endodontics and dental traumatology. *Int Endod J* 2009;42(7):555-67.
47. Ghabraei S, Bolhari B, Sabbagh MM, Afshar MS. Comparison of antimicrobial effects of triple antibiotic paste and calcium hydroxide mixed with 2 percent chlorhexidine as intracanal medicaments against enterococcus faecalis biofilm. *J Dent (Tehran)* 2018;15(3):151-60.
48. Adl A, Hamed S, Sedigh Shams M, Motamedifar M, Sobhnamayan F. The ability of triple antibiotic paste and calcium hydroxide in disinfection of dentinal tubules. *Iran Endod J* 2014;9(2):123-6.
49. Guyatt GH, Oxman AD, Montori V, et al. GRADE guidelines: 5. Rating the quality of evidence--publication bias. *J Clin Epidemiol* 2011;64(12):1277-82.
50. Berman NG, Parker RA. Meta-analysis: neither quick nor easy. *BMC Med Res Methodol* 2002;2:10.
51. Moher D, Liberati A, Tetzlaff J, Altman DG, PRISMA group. Preferred reporting items for systematic reviews and meta-analyses: the PRISMA statement. *PLoS Med* 2009;6(7):e1000097.

OPEN ACCESS DISCLAIMER AND RIGHTS:

The American Academy of Pediatric Dentistry (AAPD) publishes and maintains select Open Access articles from the journal *Pediatric Dentistry*. These articles are available on the AAPD's website at: <https://www.aapd.org/publications/journals/open-access/>. They are intended for the personal, educational use of the reader. Requests for any additional use, distribution, and/or reproduction in any medium of any Open Access article should be submitted directly to the AAPD, who may within its sole discretion determine whether to permit a licensed use. In such case, the original work must be properly cited along with the following statement:

"This article is Copyright © [insert year of publication] of the American Academy of Pediatric Dentistry and reproduced with their permission. The statements and opinions contained in this article are solely those of the individual authors and do not necessarily represent the views of the American Academy of Pediatric Dentistry. The American Academy of Pediatric Dentistry does not endorse any specific organization, product, or services referenced in the article."